



THE AGA KHAN UNIVERSITY

eCommons@AKU

Department of Pathology and Laboratory Medicine

Medical College, Pakistan

May 2000

Central nervous system lymphomas: a histologic and immunophenotypic analysis

Suhail Muzaffar
Aga Khan University

M. Shahid Siddiqui
Aga Khan University

Irshad Nabi Soomro
Aga Khan University

Shahid Pervez
Aga Khan University, shahid.pervez@aku.edu

Naila Kayani Naila Kayani
Aga Khan University

See next page for additional authors

Follow this and additional works at: http://ecommons.aku.edu/pakistan_fhs_mc_pathol_microbiol

 Part of the [Neurology Commons](#), [Pathology Commons](#), and the [Public Health Commons](#)

Recommended Citation

Muzaffar, S., Siddiqui, M. S., Soomro, I. N., Pervez, S., Naila Kayani, N., Sheema H. Hasan, S. S., Imran Siddiqui, I. (2000). Central nervous system lymphomas: a histologic and immunophenotypic analysis. *Journal of Pakistan Medical Association*, 50(5), 141-144. Available at: http://ecommons.aku.edu/pakistan_fhs_mc_pathol_microbiol/288

Authors

Suhail Muzaffar, M. Shahid Siddiqui, Irshad Nabi Soomro, Shahid Pervez, Naila Kayani Naila Kayani, Sheema H. Hasan Sheema H. Hasan Sheema H. Hasan, and Imran Siddiqui Imran Siddiqui

Central Nervous System Lymphomas: A Histologic and Immunophenotypic Analysis

Suhail Muzaffar, M. Shahid Siddiqui, Irshad Nabi Soomro, Shahid Pervez, Naila Kayani, Sheema H. Hasan (Department of Pathology, The Aga Khan University Hospital, Karachi.)
Imran Siddiqui (Family Medicine Division, Department of Community Health Sciences, Aga Khan University, Karachi.)

Abstract

Objective: To observe the spectrum of non-Hodgkin's lymphomas involving the central nervous system including morphological subtypes and immunophenotypic status.

Setting: Retrospective analysis of eleven years (1986 to 1996) data from surgical pathology files of Department of Pathology.

Results: Forty-three cases of non-Hodgkin's lymphomas were diagnosed during the period of eleven years (from 1986 to 1996), all of which were diffuse types. A total of 1177 Central Nervous System (CNS) biopsies were examined, out of which 937 cases were diagnosed as CNS neoplasms, the remaining were non-neoplastic in nature. Among 937 CNS neoplasms, 43 cases (4.6%) were reported as non-Hodgkin's lymphomas. As most of the cases were outside referrals, the primary or secondary nature of the lymphomatous process could not be assessed. Seventeen cases were intracranial, while 26 cases were spinal in location. Majority of the intracranial lymphomas were biopsied from the cerebrum (12 cases). Male to female ratio was 1:2. The median age for intracranial lymphomas was 50 years and for spinal lymphomas 29 years. There were 16 cases (37%) of diffuse large cell lymphomas; 7 cases (16%) of diffuse mixed small and large cell lymphomas; 3 cases (7%) of diffuse large cell immunoblastic lymphomas; 2 cases (4.6%) of lymphoblastic lymphomas and diffuse small non-cleaved cell lymphomas and one case of small lymphocytic lymphoma and diffuse small cleaved cell lymphoma. One case of T cell rich B cell lymphoma was also diagnosed in the thoracic spine as primary extranodal lymphoma. Eight cases were unclassifiable and in 2 cases the features were suggestive of lymphoma. Immunophenotypic analysis was performed in 20 cases, however, in 2 cases the results were inconclusive. Fifteen cases (83%) showed immunoreactivity for B cell markers and 3 cases showed T cell phenotype out of which one case was lymphoblastic lymphoma.

Conclusion: CNS lymphomas were uncommon tumors and comprised 4.6% of the total CNS neoplasms in our study. Moreover, these CNS lymphomas accounted for 2.2% of the total non-Hodgkin's lymphomas, including both nodal and extranodal. There was a higher incidence of location of these lymphomas within the spinal cord than brain. Most of the lymphomas were of intermediate or high grade (75%) according to the working phenotype in 84% of the lymphomas, in which it was formulation. Immunophenotypical status revealed B-cell tested (JPMA 50:141, 2000).

Introduction

The extra-nodal lymphomas is a group of non-Hodgkin's lymphomas which arise in non-lymphoid bearing sites. This excludes the patient with disseminated disease (Stage III E or IV) since the extranodal component is most likely a manifestation of dissemination rather than the primary site of lymphoma. The most common extranodal sites are the stomach and intestinal lining, but lymphomas have been reported to originate in all anatomic sites, including thyroid, brain, ocular region, salivary glands, testis, ovary, central nervous system, bone, breast, lung and sinonasal area¹. Central nervous system as primary site of lymphoma is an uncommon site and approximately 2% of lymphomas originate in this location². We present a local profile of CNS non-Hodgkin's lymphomas which accounts for approximately 2.2% of the total NHLs.

Materials and Methods

Patient Population

This was a retrospective study of eleven years duration (from 1986 to 1996) and the data was collected and analysed from the surgical pathology files reported during this period. Most of the cases (39 cases) were sent to our laboratory from other hospitals in the city or other parts of the country. so precise clinical history and follow-up data in these patients were not available.

Histology and Immunohistochemical Analysis

The histologic features were assessed on hematoxylin and eosin (H&E) stained sections of formalin fixed, paraffin embedded tissue. Most of the cases were classified and graded according to the Working Formulation. Immunohistochemical studies were carried out in 24 cases. The remaining cases were not analyzed phenotypically mainly because of the unavailability of this technique in the earlier part of the study period. 3-5 µm-thick sections were cut from the paraffin blocks and mounted on poly-L-lysine coated slides and then immunostained using a battery of antibodies by peroxidase - antiperoxidase (PAP) technique. The antibodies used included leucocyte common antigen (LCA), Pan B (CD20 or L26), Pan T (CD45 RO, UCHL-1), glial fibrillary acidic protein (GFAP), neuron specific enolase (NSE), S-100 protein and epithelial membrane antigen (EMA). All antibodies were obtained from Dako Inc., Denmark. Parallel positive and negative controls were also run.

Results

This was a retrospective study of eleven years duration from 1986 to 1996. The surgical pathology files were evaluated to compile and analyse the data on CNS lymphomas. As mentioned either the major part of the biopsy material was received from other hospitals of the city as well as from different parts of the country, so adequate clinical data was missing in most of our study cases. A total of 43 cases were reported as central nervous system lymphomas during the period of 11 years. Seventeen cases were intracranial, while 26 cases were spinal in location. The intracranial tumors included: cerebellum 12 cases: cerebellar and ventricular 1 case each and 3 cases of unknown site. The spinal lymphomas presented mostly as extradural or epidural masses with signs and symptoms of spinal cord compression. Ten cases showed in thoracic location; 2 cases in lumbosacral region and in 14 cases the site was not mentioned. As 39 cases were outside referrals. it was not possible to identify the primary or secondary nature of the lymphomas. The results of histologic analysis are summarized in Table 1.

Table 1. Histological analysis of CNS Non-Hodgkin's Lymphomas.

S.No.	Histologic Category	Brain	Spinal Cord	Total
1	*ML, Small lymphocytic lymphoma/Chronic lymphocytic leukemia	-	1	1
2	ML, Diffuse small cleaved cell	1	-	1
3	ML, Diffused mixed small and large cell	1	6	7 (16%)
4	ML, Diffuse large cell	12	4	16 (37%)
5	ML, Diffuse large cell immunoblastic	1	2	3 (7%)
6	ML, T-cell rich B-cell lymphoma	-	1	1
7	ML, Lymphoblastic lymphoma	1	1	2
8	ML, Burkitt's lymphoma	-	2	2
9	ML, Unclassifiable	1	7	8 (18%)
10	ML, Suggestive	-	2	2
Total		17	26	43

*ML = Malignant Lymphoma

There were 28 males and 13 females with male to female ratio of 2: 1. The age at diagnosis in cases of brain lymphomas ranged from 2 to 73 years (median 50 years) and in cases of spinal lymphomas ranged from 5 to 69 years (median 29 years). Most of the cases of brain lymphomas occurred in 5th and 6th decades (10 cases), while the peak incidence in cases of spinal lymphomas was observed in 2nd to 4th decades (16 cases). Three cases of Hodgkin's disease, not included in the study group, were also reported in the spinal location as extradural masses. Immunohistochemical analysis was performed in 24 cases out of which 20 cases were subjected for immuno—phenotyping. In two cases the results were inconclusive. The results are summarized in Table 2.

Table 2. Immunohistochemical analysis of CNS-Lymphomas.

Histologic Sub-Types	LCA	Pan B (CD20 L26)	Pan T (UCHL-1, CD45 R0)
1 *ML, Diffuse large cell	+	+	-
2 ML, Diffuse large cell	+	+	-
3 ML, Diffuse large cell	+	+	-
4 ML, Diffuse large cell	+	+	-
5 ML, Diffuse large cell	+	+	-
6 ML, Diffuse large cell	+	+	-
7 ML, Diffuse large cell	+	-	+
8 ML, Diffuse large cell	+	EQ	EQ
9 ML, Diffuse large cell	+	+	-
10 ML, Diffuse mixed small and large cell	+	+	-
11 ML, Diffuse mixed small and large cell	+	**ND	ND
12 ML, Diffuse mixed small and large cell	+	+	-
13 ML, Diffuse mixed small and large cell	+	+	-
14 ML, Diffuse mixed large cell immunoblastic	+	+	-
15 ML, Diffuse mixed large cell immunoblastic	+	+	-
16 ML, Diffuse mixed large cell immunoblastic	+	+	-
17 ML, T-cell rich B-cell lymphoma	+	+	-
18 ML, Small lymphocytic lymphoma	+	+	-
19 ML, Lymphoblastic lymphoma	+	-	+
20 ML, Unclassified	+	ND	ND
14 ML, Diffuse mixed large cell immunoblastic	+	+	-
15 ML, Diffuse mixed large cell immunoblastic	+	+	-
16 ML, Diffuse mixed large cell immunoblastic	+	+	-
17 ML, T-cell rich B-cell lymphoma	+	+	-
18 ML, Small lymphocytic lymphoma	+	+	-
19 ML, Lymphoblastic lymphoma	+	-	+
20 ML, Unclassified	+	ND	ND
21 ML, Unclassified	+	ND	ND
22 ML, Unclassified	+	-	+
23 ML, Unclassified	+	ND	ND
24 ML, Unclassified	+	EQ	EQ

*ML = Malignant Lymphoma, LCA = Leukocyte common antigen.

**ND = Not Done.

EQ = Equivocal.

Discussion

Non-Hodgkin's lymphoma (NHL) is a group of malignant neoplasms, which usually arise in lymphoid tissues. Approximately 10 to 40% of non-Hodgkin's lymphomas originate or present in

extranodal locations³⁻⁴. The most common extranodal sites are stomach and intestinal tract. NHL presenting as space occupying lesion in the central nervous system (CNS) is uncommon and accounts for approximately 2% of extranodal lymphomas². Over 90% of the intracranial lymphomas are secondary as a result of extracranial systemic spread⁵. NHL of the nodal or extranodal, non-CNS type rarely involves the brain parenchyma; involvement of the CNS when it occurs is usually limited to the leptomeninges and manifested by the presence of malignant cells in the CSF. The term primary CNS lymphomas should be reserved for those cases which are restricted at presentation to the brain, spinal cord or meninges^{6,7}. Patients with primary CNS lymphomas often have multiple tumor masses within the brain parenchyma and which accounts for less than 1% of intracranial tumors⁶. According to this study during the eleven years period (1986-1996), 117⁷ biopsies of CNS were reported, out of which 937 (80%) cases were diagnosed as CNS neoplasms.

Among CNS neoplasms forty-three cases were non-Hodgkin's lymphomas making 4.6% of all CNS neoplasms. The primary or secondary nature of CNS lymphomas could not be established in our series mainly because of inadequate clinical information, in addition of their features, primary CNS lymphomas histologically exhibit characteristic perivascular distribution of the tumor cells and the production of a typical pattern of perivascular reticulin fibres i.e., concentric cuffs or whorls around the blood vessels (Figure).

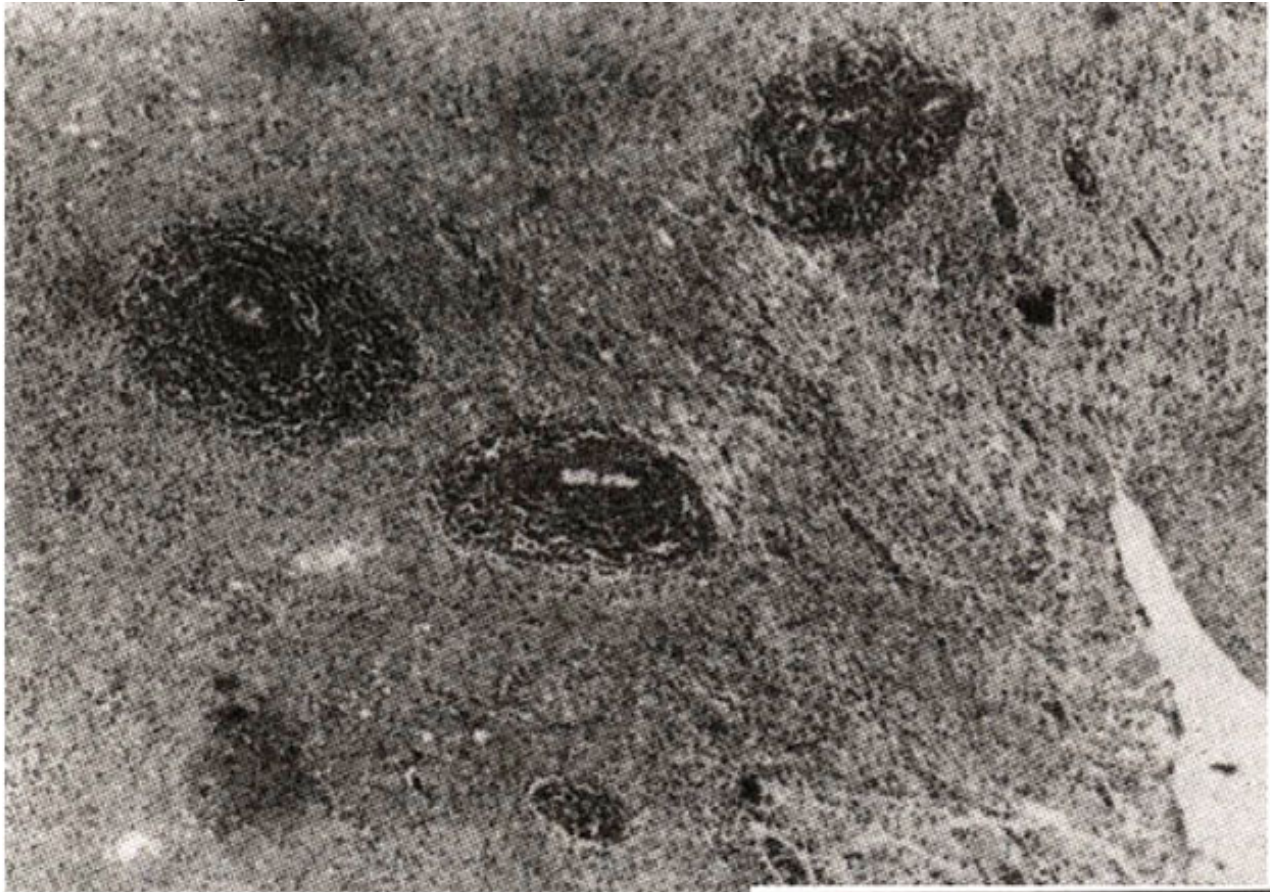


Figure Photomicrograph showing characteristic concentric lamination of tumor cells in the wall of the blood vessels (H&E stain Mag x 100).

Very rarely the lymphoma is exclusively intravascular (intravascular lymphomatosis) which is a systemic neoplasm that often involves the nervous system including progressive neurologic deficits in the background of undiagnosed or quiescent extranodal NHL⁸. Lymphoblastic and small non-cleaved cell lymphomas show the highest probability of secondarily invading the CNS. Large cell lymphoma

particularly the immunoblastic plasmacytoid type is the most common primary CNS lymphoma; small lymphocytic lymphoma is being the second most common type'. A large number of cases (37%) in our study belonged to the category of large cell lymphoma according to the classification of International Working Formulation. Although all ages are involved, the individuals in the sixth decade are most often affected. In our study spinal lymphomas showed median age of 29 years with peak incidence in 2nd to 4th decades while most of the cases of brain lymphomas affected 'patients in 5th and 6th decades of life. There is a male to female ratio of approximately 3:2. In our study the male to female ratio was 2:1. The primary CNS lymphomas are well known to be associated with immunodeficiency states, both congenital and acquired. Wiskott-Aldrich syndrome is the best documented example in the congenital group¹⁰. Among the acquired group the occurrence of lymphomas is well documented in organ transplantation and HIV infection. In one study the development of this complication was seen in 6% of the cases with the neurologic complications of the acquired immunodeficiency syndrome (AIDS)¹. Cerebrum is the commonest site, however, rarely the brainstem and cerebellum are involved. Multicentricity is a common feature; the frequency varies according to the different series from 20 to 40%, probably based on the extent and thoroughness of the examination¹². Almost all primary CNS lymphomas are of B-cell origin¹³. Comparable to the results mentioned in the published literature, 83% of our cases (15 out of 18 for which the test was carried out) were B cell lymphomas. Three cases showed T cell phenotype including one case of lymphoblastic lymphoma. One case was diagnosed as T cell rich B cell lymphoma (TCRBCL) which is a newly recognized entity and is likely to be confused with Hodgkin's disease and peripheral T cell lymphoma¹³. TCRBCL is regarded as an uncommon variant of diffuse large cell lymphoma according to the new Revised European American lymphoma (REAL) classification.¹⁴

References

1. Jaffe ES, Extranodal lymphomas and lymphoid hyperplasias. In surgical pathology of the lymph nodes and related organs. ed., Philadelphia, WB Saunders Company. 1995. pp. 476-744.
2. Cotran RS, Kumar V, Robbins SL... Robbins pathologic basis of disease. 5th ed. Philadelphia. WB Saunders Company. 1994, p. 1348.
3. Gospodarowicz MK, Sutebiffe SB, Biown TC, et al. Patterns of disease in localized extranodal lymphomas. J. Clin. Oncol.. 1997;5:875-80.
4. Mackintosh FR, Colby TV, Podolsky WJ. et al, CNS involvement in Non-Hodgkin's Lymphoma: An analysis of 05 cases. Cancer. 1982;49:586-95.
5. Otter R, Gerrits WB.I, Sandt MMVD. et al. Primary extra-nodal and nodal non-Hodgkin's lymphoma: A survey of a population-based registry. Eur. J. Cancer Clinical Oncol., 1989;25:1203-10.
6. Hochberg FH, Miller DC. Primary CNS lymphoma J. Neurosurg., 1988;68:835-53.
7. Nakleh RE, Manivel JC, Hurd D. et al CNS lymphomas Immunohistochemical and clinicopathologic study of 26 autopsy cases. Arch. Pathol. Lab. Med., 1989;13:1050-56.
8. Glass J, Hochberg F H, Miller DC. Intravascular lymphomatosis: A Systemic disease with neurologic manifestations. Cancer, 1993;71:31 56-64.
9. Murphy JK, O'Brien C.I, Ironside JW. Morphologic and immunophenotypic characterization of primary brain lymphomas using paraffin embedded tissue. Histopathology, 1989;15:449-60.
10. Model LM. Primary reticulum cell sarcoma of the brain in Wiskott—Aldrich syndrome. Arch. Neurol.. 1977;34:633-68.
11. Goldstein JD, Dickson DW, Moser F(i. et al. Primary central nervous system lymphoma in acquired immune deficiency syndrome. A clinical and pathologic study with results of treatment with radiation. Cancer, 1991;67:2756-65.
12. Henry JM, Heffner RR Jr., Dillard SH, et al. Primary malignant lymphomas of the central nervous

system. *Cancer*, 1974;34:1 293—98.

13.Simon J, Jones EL, Trumper MM. et al. Malignant lymphomas involving the central nervous system — a morphological and immunohistochemical study of 32 cases. *Histopathology*. 1987;11:335-49.

14.Chan JKC, Banks PM, Cleary ML. et al. A revised European — American classification of lymphoid neoplasms proposed by the international lymphoma study group: A summary version *Am. J. Clin. Pathol.* 1995;103:543-60.