



THE AGA KHAN UNIVERSITY

eCommons@AKU

---

Department of Surgery

Department of Surgery

---

September 2013

# Long-term outcome of primary external dacryocystorhinostomy

Rashid Baig

*Aga Khan University*, rashid.baig@aku.edu

Qazi Assad Khan

*Aga Khan University*

Khabir Ahmad

*Aga Khan University*, khabir.ahmad@aku.edu

Follow this and additional works at: [http://ecommons.aku.edu/pakistan\\_fhs\\_mc\\_surg\\_surg](http://ecommons.aku.edu/pakistan_fhs_mc_surg_surg)



Part of the [Ophthalmology Commons](#)

---

## Recommended Citation

Baig, R., Khan, Q., Ahmad, K. (2013). Long-term outcome of primary external dacryocystorhinostomy. *JCPSP: J Coll Physicians Surg Pak.*, 23(9), 641-644.

**Available at:** [http://ecommons.aku.edu/pakistan\\_fhs\\_mc\\_surg\\_surg/174](http://ecommons.aku.edu/pakistan_fhs_mc_surg_surg/174)

# Long-Term Outcome of Primary External Dacryocystorhinostomy

Rashid Baig, Qazi Assad Khan and Khabir Ahmad

## ABSTRACT

**Objective:** To assess the long-term functional outcome of external dacryocystorhinostomy (DCR) in terms of epiphora.

**Study Design:** Single-group cohort study.

**Place and Duration of Study:** Section of Ophthalmology, The Aga Khan University Hospital, Karachi, from January 2000 to June 2010.

**Methodology:** This study included adults who underwent external DCR surgery at the AKUH during January 2000 to June 2010. The main outcome measure was the proportion of patients reporting to have developed epiphora after surgery. During the telephonic interviews participants were asked if they had a recurrence (symptoms such as watering or discharge) after surgery. Individuals answering in affirmative were asked when the symptoms started. Data on age at surgery, gender and pre-operative symptoms were collected from medical records. Recurrence-free curves were calculated according to the Kaplan-Meier method.

**Results:** A total of 44 persons who underwent DCR surgery were contactable by telephone in 2011 and all agreed to participate in the study. The mean age of the patients at the time of surgery was  $48.0 \pm 15.8$  years. Overall, 38.6% (17/44) participants reported having developed epiphora after surgery. The overall median recurrence-free time was 1.7 years; there was no statistically significant difference in the median recurrence-free time between men and women.

**Conclusion:** The long-term functional outcome of external DCR surgery does not appear to be optimal and, in fact, far worse than the short-term results reported in the international literature.

**Key Words:** *External dacryocystorhinostomy. Epiphora. Functional outcome.*

## INTRODUCTION

Dacryocystorhinostomy or DCR is a surgical procedure to remove the obstruction within the lacrimal drainage channels.<sup>1,2</sup> The clinical manifestation of blocked nasolacrimal duct is epiphora or watering eyes. The site of blockage is usually the end of the duct. Since its first description by Toti in 1904,<sup>3</sup> DCR surgery has undergone many modifications. However, external DCR remains the gold standard for the treatment of such obstruction.<sup>4</sup> A new bypass channel is created by removing the intervening bone between the lacrimal sac and nasal cavity. The lacrimal sac is connected to the lining of the inside of the nose. Success is measured by two indicators: anatomic patency of the nasolacrimal system determined by saline irrigation and functional outcome defined as resolution of epiphora.<sup>5</sup> Good outcome depends on the site of obstruction, etiology, any previous surgery, and surgeon's experience.<sup>4,6</sup> However, the long-term outcome deteriorates over-time.<sup>7,8</sup>

While external DCR surgery is a routine procedure in ophthalmology units worldwide with good short-term

results, there is very little data on the long-term outcome of this procedure. The most common measure of success of DCR used in previous studies has been the anatomic patency.<sup>5</sup> However, in recent years, the importance of functional outcome after DCR has been recognized as an important end point since anatomic success is not always associated with functional success.<sup>1,4,9-13</sup> Although DCR is a routinely done eye surgical procedure, to-date no studies examining the long-term outcome have been published.

The aim of this study was to assess the long-term functional outcome of external DCR surgery performed at a tertiary hospital in Karachi, Pakistan.

## METHODOLOGY

This was a follow-up observational study. Patients who underwent external DCR surgery at the Aga Khan University, Karachi, during January 2000 – June 2010 and were contactable by telephone in 2011 were eligible to participate in the study. The main outcome measure was the proportion of patients reporting to have developed epiphora after surgery. Success of treatment was defined as self-reported resolution of epiphora after surgery. During the telephonic interview, each participant was asked if he/she had a recurrence of symptoms such as watering or discharge after surgery and if yes, when was that. Data were also collected from medical records on the following variables: age at the time of surgery, gender, preoperative symptoms, and history of trauma.

*Section of Ophthalmology, Department of Surgery, The Aga Khan University Hospital, Karachi.*

*Correspondence: Dr. Rashid Baig, Q-8, KDA Overseas Bungalows, Gulistan-e-Jauhar, Block 16-A, Karachi.*

*E-mail: rashid.baig@aku.edu*

*Received: July 20, 2012; Accepted: April 27, 2013.*

Data were analyzed using STATA 10.1 (Stata Corporation, College Station, Texas). Recurrence-free curves were calculated according to the Kaplan-Meier method. Recurrence-free interval was defined as the time from DCR surgery to the time of initial recurrence of epiphora. A p-value of < 0.05 was considered statistically significant.

### RESULTS

A total of 44 patients who had DCR surgery during the review period and who were contactable by phone in 2011. All of them participated in the study. Half of them (n = 22) were females (Table I). The mean age of study subjects at the time of surgery was 48.0 ± 15.8 years, ranging from 18 – 76 years. Three (6.8%) subjects had a history of trauma. Overall, 38.6% (17 subjects) reported having had recurrence (epiphora). The mean recurrence-free interval was 3.6 ± 3.5 years (Table II). The mean recurrence free interval was not significantly different between males and females: 3.9 ± 3.8 years vs. 3.2 ± 3.3 years; p = 0.424. Similarly, the overall median recurrence-free interval was 1.7 years ranging from 0.1 to 11.3 years. There was no statistically significant difference in the median recurrence-free interval by gender (p = 0.546).

Figure 1 shows the Kaplan Meier curve indicating the overall recurrence-free interval in years. The curve shows a sharp decline in the functional outcome from one month till 3 years after surgery, after which no

patient had recurrence. Recurrence-free probability at one-year, 2 years and 3 years after surgery were 79.5%, 63.3% and 56.1%, respectively. Figure 2 shows the Kaplan Meier curves indicating recurrence-free interval in years by gender. The curves showed no significant difference in the risk of recurrence by gender (p = 0.819).

### DISCUSSION

This is the first study, to the authors' knowledge, on the long-term functional outcome of external DCR surgery. This study shows that the long-term outcome of DCR surgery is not likely to be optimal.

Despite the increasing popularity of endoscopic DCR surgery worldwide in recent years, primarily driven by

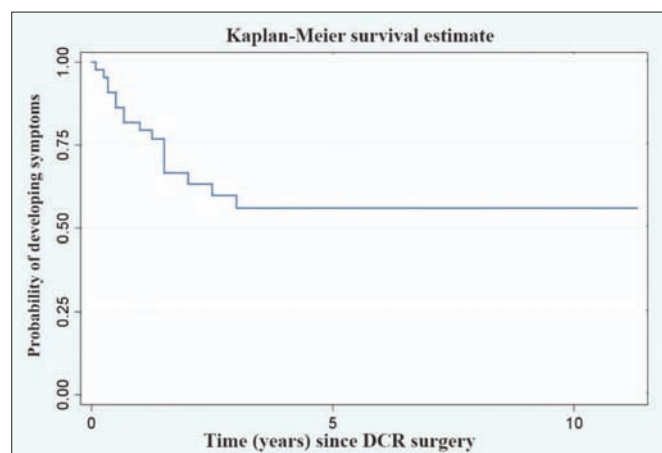


Figure 1: Survival curve showing probability of developing symptoms among 44 adults after DCR surgery.

Table I: Characteristics of study participants (n = 44).

|                                | Number | Percent |
|--------------------------------|--------|---------|
| Age at DCR surgery (years)     |        |         |
| 18-39                          | 13     | 29.5    |
| 40-59                          | 20     | 45.5    |
| ≥ 60                           | 11     | 25.0    |
| Gender                         |        |         |
| Male                           | 22     | 50.0    |
| Female                         | 22     | 50.0    |
| Symptoms at presentation*      |        |         |
| Epiphora                       | 43     | 97.7    |
| Purulent discharge             | 19     | 43.2    |
| Swelling at the medial canthus | 17     | 38.6    |
| Regurgitation                  | 13     | 29.5    |
| Cellulitis                     | 2      | 4.5     |
| Pain                           | 3      | 6.8     |
| History of trauma              |        |         |
| Yes                            | 3      | 6.8     |
| No                             | 41     | 93.2    |

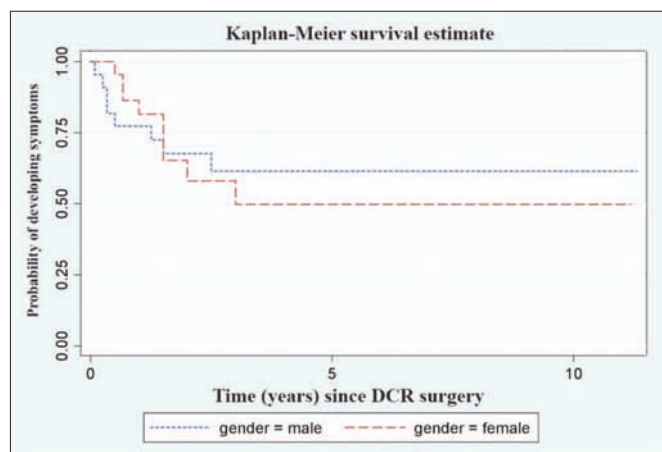


Figure 2: Survival curve (Kaplan-Meier) showing risk probability of developing symptoms among men and women after DCR surgery.

Table II: The mean and median follow-up time (years) and recurrence-free interval (years) among those who received DCR surgery (n = 44).

| Variable                     | Gender  | n  | Mean | SD  | Median | Minimum | Maximum |
|------------------------------|---------|----|------|-----|--------|---------|---------|
| Follow-up time (years)       | Male    | 22 | 5.6  | 3.7 | 5.0    | 1.2     | 11.5    |
|                              | Female  | 22 | 4.6  | 3.1 | 4.3    | 0.9     | 11.3    |
|                              | Overall | 44 | 5.1  | 3.4 | 4.8    | 0.9     | 11.5    |
| Recurrence-free time (years) | Male    | 22 | 3.9  | 3.8 | 2.2    | 0.1     | 11.3    |
|                              | Female  | 22 | 3.2  | 3.3 | 1.6    | 0.5     | 11.2    |
|                              | Overall | 44 | 3.6  | 3.5 | 1.7    | 0.1     | 11.3    |

**Table III:** Functional outcome of DCR surgery: comparison of the present study with previous studies.

| Author               | Year | Country     | Mean follow-up duration (range) in months | Sample size | Successful outcome (resolution of epiphora) |      |
|----------------------|------|-------------|---|-------------|---|------|
|                      |      |             |   |             | Number                                      | %    |
| Tarbet <sup>14</sup> | 1995 | USA         | 52 months (range 12-108)                  | 93          | 74  | 79.6 |
| Ibrahim <sup>5</sup> | 2001 | UK          | 40 months (range, 11-63)                  | 110         | 42  | 38.2 |
| Mirza <sup>11</sup>  | 2002 | UK          | 9 months (range, 3-15)                    | 49          | 41  | 83.7 |
| Dolman <sup>6</sup>  | 2003 | Canada      | 12 months (NA)                            | 153         | 138   | 90.2 |
| Mansour <sup>4</sup> | 2005 | Netherlands | NA (range, 12-60 months)                  | 83          | 52  | 62.7 |
| Yigit <sup>7</sup>   | 2007 | Turkey      | 12 months ( NA)                           | 55          | 38  | 69.1 |
| Lester <sup>9</sup>  | 2008 | UK          | 9 months (range 3-15)                     | 49          | 41  | 83.7 |
| Leong <sup>9</sup>   | 2010 | UK          | 16.8 months (range, 3-36)                 | 31          | 22  | 71.0 |
| Current study        | 2011 | Pakistan    | 61 months (range, 11-138)                 | 44          | 27  | 61.4 |

NA = Not available

some of the disadvantages of external DCR surgery (e.g., cutaneous scar and bleeding), the latter remains the gold standard for the treatment of nasolacrimal duct obstruction to relieve epiphora because it has a shorter operative time, is easy to learn and cost-effective.

A comparison of the present study with previous studies,<sup>1,9-15</sup> that used a similar definition of functional outcome (i.e., resolution of epiphora) is shown in Table III. Four of listed studies were conducted in UK and one each in the United States, Canada, Netherlands and Turkey. The present sample size is within the range of what has been previously reported (Table III). DCR is not a very frequently done surgical procedure and, therefore, achieving a sufficiently large sample size is a challenge. One striking feature of the available literature on functional outcome of DCR surgery has been the wide variation in the length of follow-up period among the different studies.<sup>1,9-15</sup> Of the studies we reviewed, three did not have complete information about the length of follow-up.<sup>9,11,12</sup> The remaining had different lengths of follow-up, with follow-up period ranging from 7 months to 108 months.<sup>1,10,13-15</sup> The rate of successful functional outcome in this study was 61.4% (mean follow-up duration: 61 months) which is within the range (38.1% to 94.1%) observed in previous studies. Generally, the greater the mean length of follow up period, the lower was the rate of successful functional outcome. For example, Tarbet and Custer<sup>14</sup> assessed the long-term outcome of DCR surgery subjectively through a telephone survey in 153 patients in the United States. Responses were obtained from 93 patients. Of these, 79.6% had successful functional outcome (average follow up duration: 52 months, range 12 – 108 months). Similarly, Mansour and colleagues<sup>9</sup> sent a postal questionnaire to 139 patients who had undergone external DCR surgery to assess their functional outcome. Complete data were received for 83 persons of whom 52 (62.7%) had successful functional outcome. The follow-up duration ranged from 12 to 60 months.

The outcome of external DCR surgery can be measured by both anatomical and functional indicators. However, functional outcome is what matters to patients. It is being

increasingly recognized that anatomic patency does not always translate into good functional outcome. Some patients with an anatomically patent nasolacrimal system still have epiphora symptoms. Hence, the functional outcome alone provides a good picture regarding DCR outcome.<sup>9</sup> Previous studies assessing the functional outcome of DCR surgery have used face-to-face or telephone interviews; or postal questionnaire surveys.<sup>1,9-15</sup> In this study, the questionnaire was administered via telephone interview. While telephone interviews compared with face-to-face interviews have certain advantages in terms of cost and convenience, most of the phone numbers were not answered when called several times at varying times of day and on varying days of the week. A total of 289 persons with known phone numbers were contacted, but we were only able to complete 44 telephonic interviews. All those who could be reached via a residential or mobile phone number agreed to participate in the study. It was not possible to ascertain how representative these respondents were of all 289 who underwent DCR surgery during the 11-year review period. Another limitation of our study was that we could not assess factors predictive of outcome such as the site of obstruction and surgeons' skills. Despite these limitations, this study provides evidence that the functional outcome of external DCR surgery deteriorates with time and the long-term functional outcome of this procedure is not optimal. Adequately sized long-term follow up research is needed to confirm this hypothesis.

## CONCLUSION

The long-term functional outcome of external DCR surgery does not appear to be as optimal as the short-term outcome. Generally, the greater the length of follow-up duration, the lower the success rate.

## REFERENCES

1. Leong SC, Karkos PD, Burgess P, Halliwell M, Hampal S. A comparison of outcomes between non-laser endoscopic endonasal and external dacryocystorhinostomy: single-center

- experience and a review of British trends. *Am J Otolaryngol* 2010; **31**:32-7.
2. Carifi M, Zuberbuhler B, Carifi G. Efficacy of external and endonasal dacryocystorhinostomy. *J Craniofacial Surg* 2012; **23**:1582-3.
  3. Toti A. Nuovo metodo conservatore di cura radicale delle suppurazioni croniche del sacco lacrimale (Dacriocistorinostomia). *Clin Moderna Firenze* 1904; **10**:385-7.
  4. Leong SC, Macewen CJ, White PS. A systematic review of outcomes after dacryocystorhinostomy in adults. *Am J Rhinol Allerg* 2010; **24**:81-90.
  5. Lee DW, Chai CH, Loon SC. Primary external dacryocystorhinostomy versus primary endonasal dacryo-cystorhinostomy: a review. *Clin Experiment Ophthalmol* 2010; **38**:418-26.
  6. Eichhorn K, Harrison AR. External vs. endonasal dacryocystorhinostomy: six of one, a half dozen of the other? *Curr Opin Ophthalmol* 2010; **21**:396-403.
  7. Walker RA, Al-Ghoul A, Conlon MR. Comparison of nonlaser nonendoscopic endonasal dacryocystorhinostomy with external dacryocystorhinostomy. *Canadian J Ophthalmol J Canadien D'ophtalmol* 2011; **46**:191-5.
  8. Anijeet D, Dolan L, Macewen CJ. Endonasal versus external dacryocystorhinostomy for nasolacrimal duct obstruction. *Cochrane Database Syst Rev* 2011; **(1)**: CD007097.
  9. Mansour K, Sere M, Oey AG, Bruin KJ, Blanksma LJ. Long-term patient satisfaction of external dacryocystorhinostomy. *Ophthalmologica J Int d'ophtalmol Int J ophthalmol Zeitschrift fur Augenheilkunde* 2005; **219**:97-100.
  10. Ibrahim HA, Batterbury M, Banhegyi G, McGalliard J. Endonasal laser dacryocystorhinostomy and external dacryocystorhinostomy outcome profile in a general ophthalmic service unit: a comparative retrospective study. *Ophthalmic Surg Lasers* 2001; **32**:220-7.
  11. Dolman PJ. Comparison of external dacryocystorhinostomy with nonlaser endonasal dacryocystorhinostomy. *Ophthalmology* 2003; **110**:78-84.
  12. Yigit O, Samancioglu M, Taskin U, Ceylan S, Eltutar K, Yener M. External and endoscopic dacryocystorhinostomy in chronic dacryocystitis: comparison of results. *European archives of oto-rhino-laryngology. External and endoscopic dacryocystorhinostomy in chronic dacryocystitis: comparison of results. Eur Arch Otorhinolaryngol* 2007; **264**:879-85.
  13. Lester SE, Robson AK, Bearn M. Endoscopic 'cold steel' versus laser dacryocystorhinostomy: completing the audit cycle. *J Laryngol Otolaryngol* 2008; **122**:924-7.
  14. Tarbet KJ, Custer PL. External dacryocystorhinostomy. Surgical success, patient satisfaction, and economic cost. *Ophthalmology* 1995; **102**:1065-70.
  15. Mirza S, Al-Barmani A, Douglas SA, Bearn MA, Robson AK. A retrospective comparison of endonasal KTP laser dacryocystorhinostomy versus external dacryocystorhinostomy. *Clin Otolaryngol Allied Sci* 2002; **27**:347-51.

