



4-2013

# Cerebral sinus thrombosis secondary to epidural anaesthesia

Modar Khalil

*Hull Royal Infirmary, Kingston-Upon-Hull, England*

Mohamed El-Sayed

*Royal Infirmary, Kingston-Upon-Hull, England*

Fayyaz Ahmed

*Royal Infirmary, Kingston-Upon-Hull, England*

Alec Ming

*Hull Royal Infirmary, Kingston-Upon-Hull, England*

Follow this and additional works at: <http://ecommons.aku.edu/pjns>



Part of the [Neurology Commons](#)

## Recommended Citation

Khalil, Modar; El-Sayed, Mohamed; Ahmed, Fayyaz; and Ming, Alec (2013) "Cerebral sinus thrombosis secondary to epidural anaesthesia," *Pakistan Journal of Neurological Sciences (PJNS)*: Vol. 8 : Iss. 2 , Article 4.

Available at: <http://ecommons.aku.edu/pjns/vol8/iss2/4>

# CEREBRAL SINUS THROMBOSIS SECONDARY TO EPIDURAL ANAESTHESIA

**Modar Khalil, Mohamed El-Sayed, Fayyaz Ahmed, Alec Ming**  
 Neurology Department, Hull Royal Infirmary, Kingston-Upon-Hull, England

Correspondence to: Modar Khalil, Specialist registrar in Neurology, Hull Royal Infirmary, Anlaby road, Kingston-Upon-Hull HU10 6RG, UK. Email: modar.khalil@hey.nhs.uk

## ABSTRACT

Cerebral venous sinus thrombosis (CVST) is an uncommon, and yet potentially fatal, condition; we present a rare case of CVST as a complication of epidural anaesthesia used for caesarean section, we review different aspects of CVST in terms of epidemiology, aetiology, investigations, and treatment, as well as most acceptable theory explaining the pathogenesis in our case report

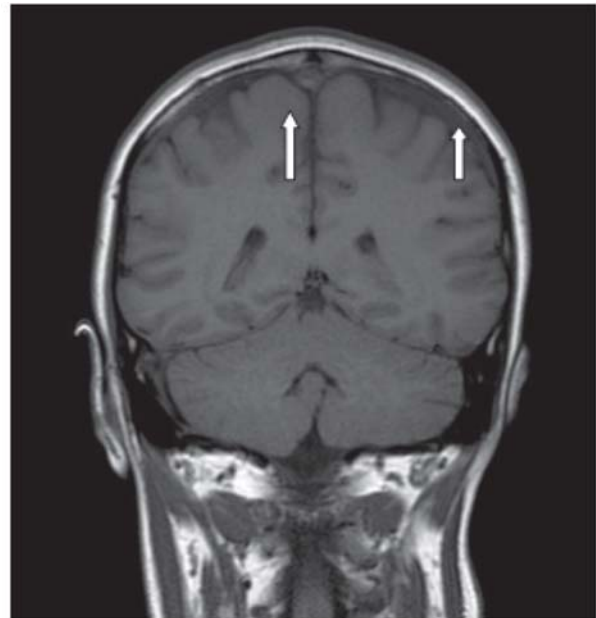
## INTRODUCTION

Cerebral venous sinus thrombosis (CVST) is an uncommon condition that can be potentially life threatening. CVST can present with diverse set of symptoms that makes diagnosing it a difficult task. We report a case of CVST secondary to epidural anaesthesia that is rarely described in the literature. In light of this case we review various aspects of the disorder as well as possible pathogenesis.

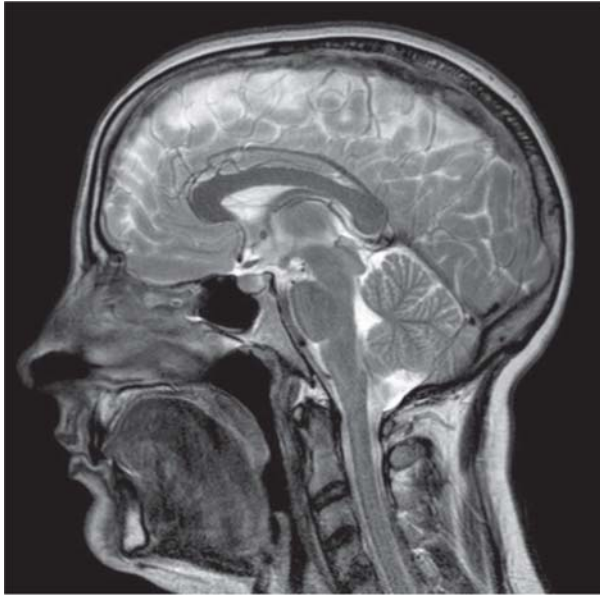
## CASE REPORT

A 31 year old female with past medical history of epilepsy since 2002, taking lamotrigine 200mg twice daily, was seizure free for 6 years prior to this event. She delivered her first baby with emergency caesarean section (using epidural anaesthesia) due to foetal distress, secondary to prolonged labour after 40 weeks of uneventful pregnancy. The following day, patient complained of global headache with significant postural component suggestive of low cerebrospinal fluid (CSF) pressure, which was being managed conservatively. 5 days post-epidural the patient complained of sudden onset horizontal gaze diplopia worse on looking to the left, and a day later presented to accident & emergency with three generalised tonic-clonic seizures.

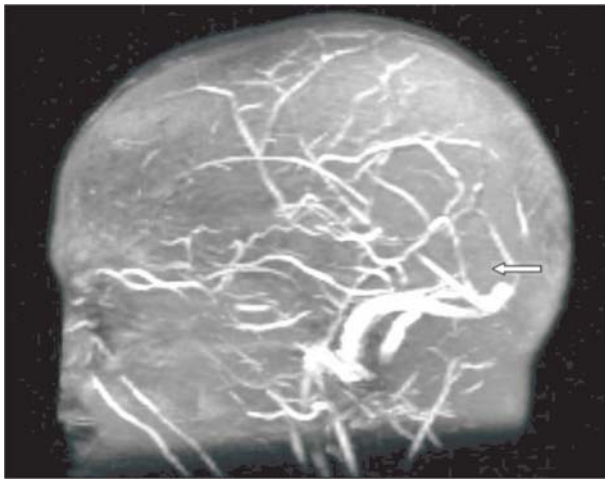
An urgent MRI/MR brain venography of the brain (figure 1, 2, 3) showed bilateral subdural collections, absence of normal flow void in the superior sagittal sinus consistent with a thrombus. The patient was commenced on anticoagulation therapy with seizure control optimised by adding clonazepam. Repeat neuro-imaging at 6 months showed almost complete re-canalisation, so anticoagulation was discontinued and clonazepam was weaned off.



**Figure 1:** MRI T1 coronal section showing absence of flow void in the superior sagittal sinus (long arrow) and subdural collection secondary to decreased CSF pressure after the epidural anaesthesia (short arrow)



**Figure 2:** MRI T2 sagittal showing signal change in the superior sagittal sinus (arrows) suggestive of CVST



**Figure 3:** MR venogram (MRV) showing absence of contrast flow in the superior sagittal sinus

## DISCUSSION

CVST epidemiological data are lacking, however, incidence varies between 0.22-1.23/100000 cases<sup>1,2</sup>. In a different study, the incidence was considerably higher perinatally 11.6/100000 cases<sup>3</sup>. CVST is commoner in women (ratio is 3:1)<sup>4</sup>, probably, due to women being more susceptible to risk factors of pregnancy and use of hormones for contraception.

The pathophysiology of CVST is still unclear, nonetheless it is known that the clinical manifestations of CVST are

related to either focal cerebral cellular dysfunction secondary to venous thrombosis, or raised intracranial pressure secondary to poor absorption of CSF into the cerebral sinuses.

### Aetiology:

Many conditions have been recognised as risk factors for CVST, and around 50% of cases had more than one risk factor, nonetheless 10-15% of CVST cases have no identifiable causative aetiology<sup>5</sup>. The commonest risk factor is prothrombotic conditions, others include: pregnancy, contraceptive pills, malignancy, infection, and mechanical injuries.

Dural puncture as an aetiology for CVST is rare, around 30 cases have been reported since 1985<sup>6,7</sup>, and an acceptable explanation of the pathogenesis stems from:

1. The intracranial changes following low CSF pressure leading to reduced mean blood flow velocity by almost half which, given enough time may precipitate thrombus formation<sup>8</sup>.

2. Venous blood stasis as a consequence to sinus dilatation following intracranial hypotension is a significant risk for clot formation Almost 75% of post-LP CVST cases had another risk factor, commonly, prothrombotic states, malignancies, puerperium, and high dose steroids<sup>6,7</sup>. As far as we are aware only a few cases following an epidural anaesthesia has been reported<sup>9, 10, 11</sup>.

### Investigations:

Non contrast head CT scan can be normal in up to a third of cases<sup>12</sup> so the best modality of investigation which offers best sensitivity is MRI gradient echo T2\* susceptibility-weighted sequence along with MR venography<sup>13</sup>. CT venography offers a cheap and quick alternative to MRI when contraindicated. Normal D-dimer does not fully exclude the diagnosis of CVST, as it can be normal in up to 10% of cases<sup>14</sup>. Appropriate screening for prothrombotic conditions should be considered.

LP has poor specificity for CVST, but it is helpful in excluding other potentially dangerous conditions as well as provides a temporary high-CSF-pressure relief where vision is endangered.

### Treatment:

The use of anticoagulation therapy is cornerstone in managing CVST with the aim of achieving complete recanalisation. A meta-analysis has shown anticoagulation to be beneficial but did not reach statistical significance<sup>15</sup>

and the duration of treatment was suggested to be 3-6 months in provoked CVST and 6-12 months in unprovoked cases<sup>16</sup>. Thrombolysis/thrombectomy may be reserved for severe cases without response to anticoagulation, but this is not substantiated by good quality evidence<sup>17</sup>.

Anti platelet therapy could be considered where anticoagulation therapy is contraindicated. Acute treatment of raised intracranial pressure (ICP) would go hand in hand with the general measures taken in treating raised ICP, however intravenous steroids were found to be ineffective in CVST<sup>18</sup>.

CVST can present with seizures in up to 40% of cases and use of anti epileptic drug (AED) is recommended in those with evidence of supra tentorial lesions<sup>16</sup>, for one year as per the European Federation of Neurological Societies (EFNS) guidelines<sup>20</sup>. Use of valproate appears to be preferential to phenytoin due to reduced risk of drug interactions with concomitant anticoagulation<sup>21</sup>.

## REFERENCES

1. Ferro JM, Correia M, Pontes C, Baptista MV, Pita F, Cerebral Venous Thrombosis Portuguese Collaborative Study Group (Venoport). Cerebral vein and dural sinus thrombosis in Portugal: 1980-1998. *Cerebrovasc Dis*. 2001;11(3):177
2. Coutinho JM, Zuurbier SM, Aramideh M, Stam J. The incidence of cerebral venous thrombosis: a cross-sectional study. *Stroke*. 2012 Dec;43(12):3375-7
3. Lanska DJ, Kryscio RJ. Risk factors for peripartum and postpartum stroke and intracranial venous thrombosis. *Stroke*. 2000;31(6):1274
4. Coutinho JM, Ferro JM, Canhão P, Barinagarrementeria F, CantúC, Bousser MG, Stam J. Cerebral venous and sinus thrombosis in women. *Stroke*. 2009;40(7):2356
5. Ferro JM, Canhão P, Stam J, Bousser MG, Barinagarrementeria F, ISCVT Investigators. Prognosis of cerebral vein and dural sinus thrombosis: results of the International Study on Cerebral Vein and Dural Sinus Thrombosis (ISCVT). *Stroke*. 2004;35(3):664
6. Coutinho JM, Ferro JM, Canhão P, Barinagarrementeria F, CantúC, Bousser MG, Stam J. Cerebral venous and sinus thrombosis in women. *Stroke*. 2009;40(7):2356
7. Ferro JM, Canhão P, Stam J, Bousser MG, Barinagarrementeria F, ISCVT Investigators. Prognosis of cerebral vein and dural sinus thrombosis: results of the International Study on Cerebral Vein and Dural Sinus Thrombosis (ISCVT). *Stroke*. 2004;35(3):664
8. Aidi S, Chaunu MP, Biousse V, Bousser MG. Changing pattern of headache pointing to cerebral venous thrombosis after lumbar puncture and intravenous high-dose corticosteroids. *Headache* 1999;39:559-564
9. Miglis MG, Levine DN. Intracranial Venous Thrombosis After Placement of a Lumbar Drain. *Neurocrit Care* 2010;12:83-87
10. Canhao P, Batista P, Falcao F. Lumbar Puncture and Dural Sinus Thrombosis - A Causal or Casual Association? *Cerebrovasc Dis* 2005;19:53-56
11. Jungmann V, Werner R, Bergmann J, Daum J, Wöhrle JC, Dünnebacke J, Silomon M. Sinusvenenthrombose nach geburtshilflicher Epiduralanästhesie. *Anaesthesist*. 2009;58(3):268-72
12. Todorov L, Laurito C, Schwartz D. Postural Headache in the Presence of Cerebral Venous Sinus Thrombosis. *Anesth Analg* 2005;101:1499-500
13. Ghatge S, Uppugonduri S, Kamarzaman Z. Cerebral venous sinus thrombosis following accidental dural puncture and epidural blood patch. *Journal of Obstetric Anesthesia* (2008) 17, 267-270
14. Bousser MG, Russell RR. Cerebral venous thrombosis. In: Major Problems in Neurology, Warlow CP, Van Gijn J (Eds), WB Saunders, London 1997. p.27, 104
15. Lafitte F, Boukobza M, Guichard JP, Hoeffel C, D, Ille O, Woimant F, Merland JJ. MRI and MRA for diagnosis and follow-up of cerebral venous thrombosis (CVT). *Clin Radiol*. 1997;52(9):672