



THE AGA KHAN UNIVERSITY

eCommons@AKU

---

Section of Otolaryngology, Head & Neck Surgery

Department of Surgery

---

June 1999

# Aspergillosis of the Sphenoid Sinus with the Involvement of the Clivus

Mubasher Ikram  
*Aga Khan University*

S.S.M. Hussain  
*Aga Khan University*

R Ahmad  
*Liaqat Hospital*

Follow this and additional works at: [http://ecommons.aku.edu/pakistan\\_fhs\\_mc\\_surg\\_otolaryngol\\_head\\_neck](http://ecommons.aku.edu/pakistan_fhs_mc_surg_otolaryngol_head_neck)



Part of the [Otolaryngology Commons](#)

---

## Recommended Citation

Ikram, M., Hussain, S., Ahmad, R. (1999). Aspergillosis of the Sphenoid Sinus with the Involvement of the Clivus. *Journal of the Pakistan Medical Association*, 49(6), 146-148.

**Available at:** [http://ecommons.aku.edu/pakistan\\_fhs\\_mc\\_surg\\_otolaryngol\\_head\\_neck/61](http://ecommons.aku.edu/pakistan_fhs_mc_surg_otolaryngol_head_neck/61)

# Aspergillosis of the Sphenoid Sinus with the Involvement of the Clivus

Pages with reference to book, From 146 To 148

M. Ikram, S.S.M. Hussain ( Departments of Otolaryngology Head and Neck Surgery, The Aga Khan University Hospital, Karachi. )

R. Ahmed ( Department of Radiology, Liaquat National Hospital, Karachi. )

## Introduction

Fungal infections of the nose and paranasal sinuses are frequent in this part of the world. One aspect of the increased frequency is the improved clinical, radiological and pathological diagnostic methods that are now available. Aspergillus is the commonest infecting fungus of the nose and the paranasal sinus<sup>1</sup>. It is mainly a saprophytic spore producing fungus and can cause invasive and non-invasive infections. The initial report of fungal paranasal infection largely dealt with immunocompromised individuals as distinct from the allergic fungal infection. Aspergillosis confined to the sphenoid sinus is uncommon with only 34 cases having been reported in the literature<sup>2,3</sup>. These were mostly seen in immunosuppressed patients. Isolated sphenoid sinusitis is uncommon and that due to fungal infection is rare<sup>4</sup>. We report the case of aspergillosis of the sphenoid sinus where disease had extended into the upper part of the clivus bone.

## Case Report

A 23 year male student presented with generalized headaches of 3 years and diplopia of 6 months duration. There was nothing remarkable in his past medical history. Clinical examination revealed a paralysed left lateral rectus muscle. His nose and throat showed no abnormality. There was an adenoid like swelling in his post nasal space. His airway was patent. No other abnormality was noted. The swelling within his post nasal space was biopsied with rigid endoscope under local anaesthesia and trans-septal sphenoidotomy was performed under general anaesthesia. Frozen section showed chronic granulomatous inflammation with septate hyphae. The disease was cleared from the sphenoid along with its extension into the clivus. An uneventful recovery followed. The patient was commenced on oral itraconazole. This is to continue for 6 months.

## Discussion

Aspergillosis of the paranasal sinuses can present in two forms, either as extra mucosal disease or the more dangerous fulminant form.

The extramucosal disease presents with symptoms that are not dissimilar to chronic sinusitis with nasal obstruction, purulent rhinorrhea and facial pain, all of which are resistant to treatment with antibiotics. This may be associated with a slow development of fungal ball. The fulminant form occurs in immunosuppressed as in uncontrolled diabetic patients with ketoacidosis. Necrosis of turbinates, with black crusting in nasal cavities suggestive of this aggressive form of invasive fungal sinusitis. This is more aggressive and may show intracranial or orbital extension<sup>5</sup>. It may produce rhinocerebral infection and orbital involvement similar to mucormycosis, although hematogenous spread from lungs to brain is more common. This fungus also has a well known propensity for involving blood vessels including internal carotid artery. Patients with this condition usually have a history of recurrent upper respiratory infection, immunosuppression and granulocytopenia, or debilitating illnesses such as

diabetes mellitus and renal failure. The common presenting symptoms include headache, dizziness, focal neurological deficit or visual disturbances<sup>6</sup>.

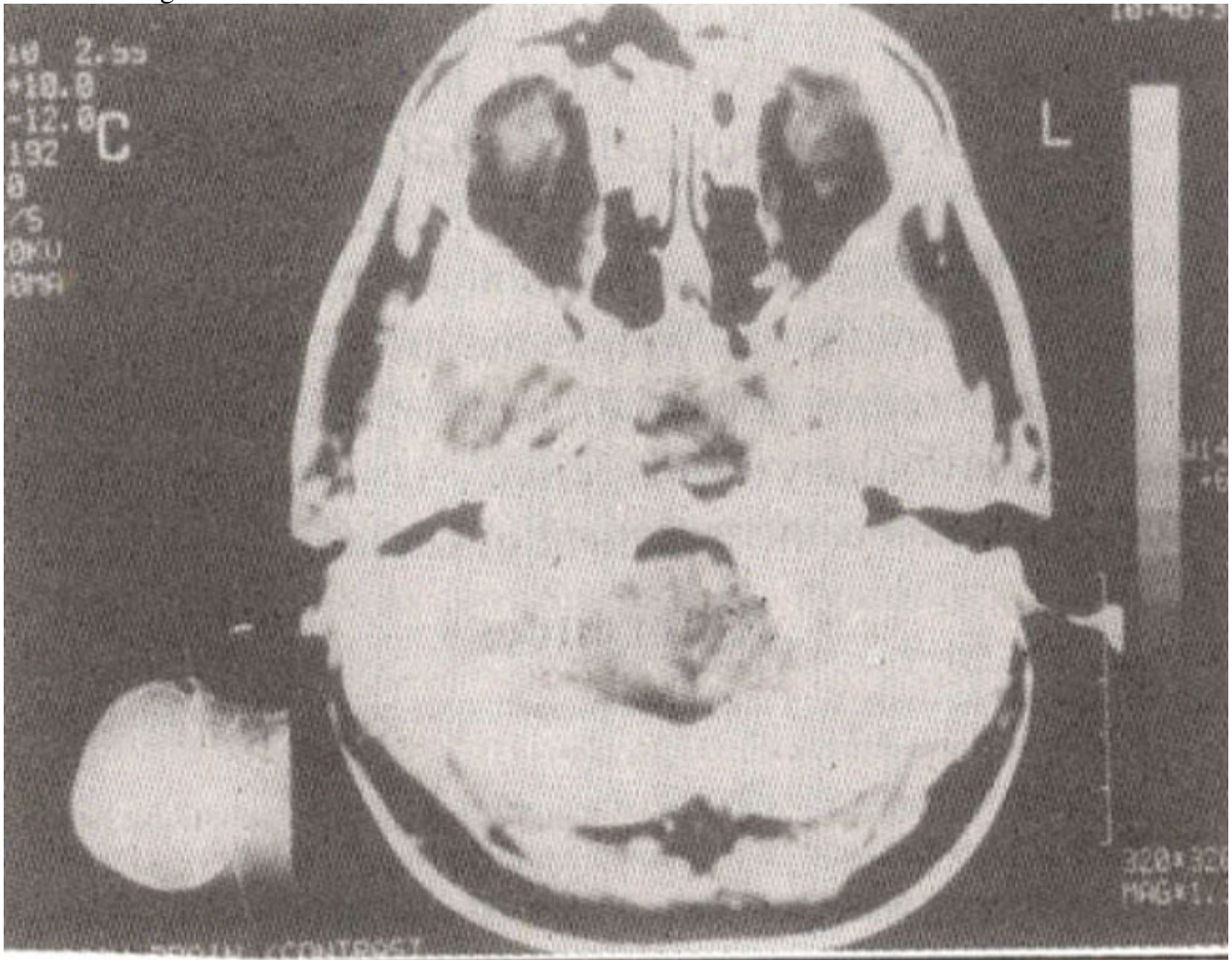


Figure 1. CT scan showing the soft tissue mass in the sphenoid with extension into the clivus

CT and MR scanning have been the most effective imaging modalities for making the correct diagnosis. Areas of increased attenuation in a diseased sinus, in the absence of contrast administration are readily identified by CT and are highly suggestive of fungal infection. Heavy metals such as iron and magnesium are essential components of fungal metabolism. It is these heavy metals that cause high density on CT.

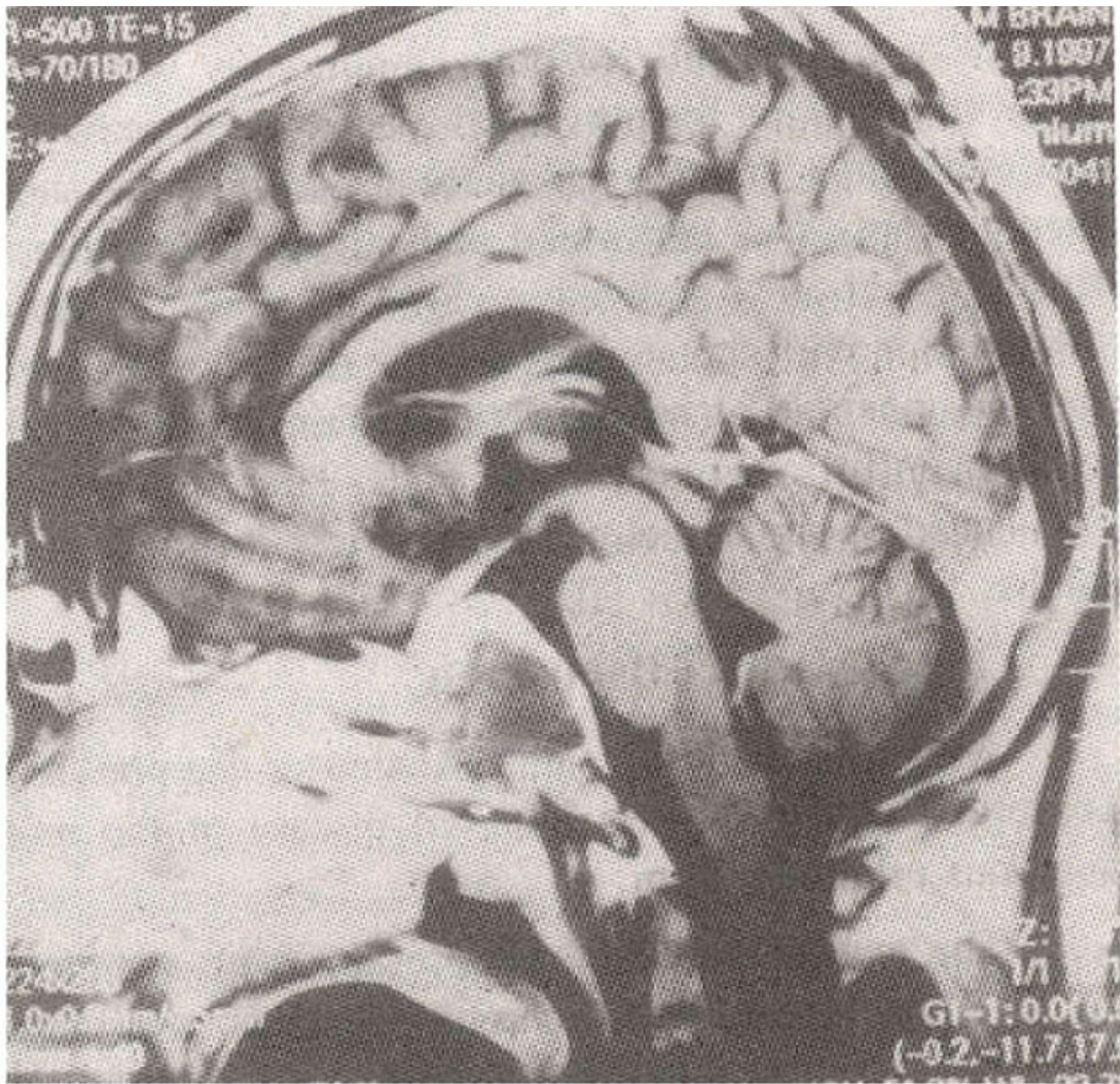


Figure 2a. MRI (Sagittal) with gadolinium showing the mass as hypodense signal on T2 weighted image.

The nodular mucoperiosteal thickening and bony sclerosis and erosions are clearly documented. Magnetic Resonance Imaging evaluation of this condition can be diagnostic. There is a decrease signal intensity in T1 and T2 weighted MR sequences due to presence in fungal concretions of iron, magnesium and manganese, which are known to be essential to the fungal amino acid metabolism and calcium<sup>7</sup>. Aspergillosis of the sphenoid sinus is rare with only 34 cases reported in the literature<sup>2</sup>. The involvement of clivus is more so. The clinical presentation of the sphenoid sinus aspergillosis is directly related to the anatomy of the sinus and surrounding structures. In the few documented cases of isolated sphenoid aspergillosis headache was the most frequent symptom followed by rhinorrhea, nasal obstruction, ptosis, proptosis, diplopia and decreased visual acuity<sup>8</sup>. The treatment of this condition is primarily surgical, i.e., removal of mycotic mass and the establishment of drainage of the involved sinus. Antifungal chemotherapeutic agents are essential part of the treatment in invasive aspergillosis particularly when the disease is fulminant or the central nervous system has been involved<sup>9</sup>.

Craniotomy is not recommended as the surgical approach to sphenoidal sinus disease. Endoscopic sphenoidotomy is a direct surgical approach with minimum blood loss and in experienced hands with decrease morbidity<sup>8</sup>. The disadvantage being that this is lateral to the midline and clearance may be difficult if the clivus is involved.

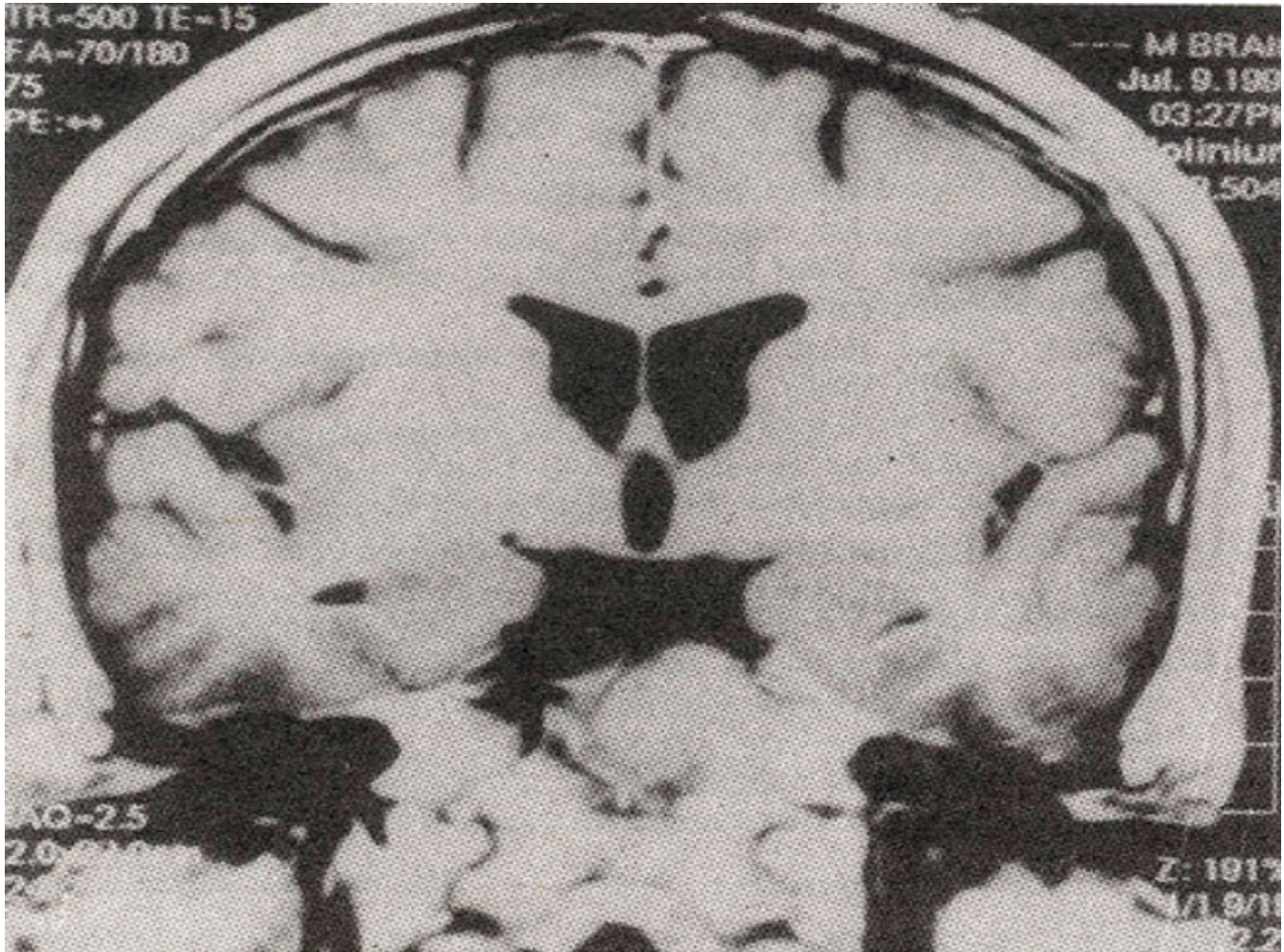


Figure 2b. MRI (Coronal) with showing the mass as hypodense signal on T2 weighted image.

The transeptal sphenoidotomy has the advantage of being in the midline as well as the use of the microscope to allow stereoscopic appreciation of depth and satisfactory clearance particularly when clivus is involved. In the author's view this is the treatment of Choice.

## References

1. Blitzer A, Lawson W. Fungal infection of nose and PNS. *Otolaryngologic clinics of North America* 1993;26: 1007-35.
2. Kurita H, Shiokavo Y, Paraseller. Aspergillus granuloma extending from the sphenoid sinus. Report of two cases. *Surgical Neurology*, 1995;44:489-94.
3. Parker KM, Nicholson JK. Aspergillosis of the sphenoid sinus, presenting as a pituitary mass and postoperative Gallium-67 Imaging. *Surgical Neurology*, 1996;45:354-8.
4. Walter GWR, Milford CA. Isolated sphenoid sinusitis due to *penalolleschie Boydii*. *J. of Laryngol. Otol.*, 1993;107:344-46.
5. Colmon MF. Invasive aspergillus of the head and neck. *Laryngoscope*. 1985;95:898-99.
6. Sarti EJ, Blaugrund SM. Paranasal sinus disease with intracranial extension. *Aspergillosis versus*

malignancy. Laryngoscope. 1988;9&632-35.

7. Shankar L, Evans K, Hawke M, et al. An Atlas of imaging of paranasal sinus. Chap. 8., Philadelphia, J.B. Lippincott Co., 1995, pp. 82.

8. Lin WS, Hung HY. Transnasal endoscopic surgery of sphenoid sinus aspergillosis. J. of Laryngol. Otol., 1993 107:837-39.

9. Romett IL, Newman RK. Aspergillosis of the nose and PNS. Laryngoscope, 1982,92:764-769.