

Bleomycin induced pneumonitis: a case successfully managed with high-dose steroids

Shahid Javed Husain, Ali Bin Sarwar Zubairi, Muhammad Irfan
Section of Pulmonary & Critical Care Medicine, The Aga Khan University Hospital, Karachi.

Introduction

Bleomycin is a chemotherapeutic agent used in a number of solid organ malignancies.¹⁻³ It accumulates in the skin and lungs resulting in skin ulceration and associated pulmonary toxicity. Its use is somewhat limited due to its significant pulmonary adverse effects with bleomycin induced pneumonitis (BIP) as the commonest and most dreaded complications. The overall incidence of pulmonary toxicity is as high as 10% and it is fatal in 1-2%.^{3,4}

We present a case of BIP which was successfully managed by the aggressive use of high dose steroids with complete resolution.

Case Report

A 59 year old male with a history of Hodgkin's lymphoma which was treated with 6 cycles of ABVD (adriamycin, bleomycin, vincristine, doxorubicin) completed one month ago, presented to the hospital with a 2 week history of low grade fever and cough accompanied by dyspnoea and right sided pleuritic chest pain. On physical examination he was in mild distress. The BP was 110/70 mmHg, pulse was 100/min, RR 28/min and oxygen saturation of 88% on room air, which increased to 96% on 4 L nasal oxygen. On chest examination he had harsh breath sounds and crackles at the bases bilaterally. His chest radiograph showed subtle increase density in both lung bases. He was started on intravenous ceftriaxone and clarithromycin. A fiberoptic bronchoscopy with broncho alveolar lavage was done. The gram stain and culture sensitivity, acid fast bacilli smear and fungal cultures were all negative. The BAL cell count was not done due to its low specificity.

A high resolution CT scan of chest was performed which showed diffuse ground glass opacification on both lower lung zones and pleural based nodules (Figures 1 and 2). These findings were highly suggestive of bleomycin induced pneumonitis (BIP). The patient was started on oral steroids at 1 mg/kg (50mg/day). His dyspnoea improved in 48 hours and he was able to walk to the washroom without assistance and without oxygen. He was subsequently discharged home. As an outpatient he had a spirometry (10 days of steroids) which showed mildly reduced FVC (70%) and FEV1/FVC ratio of 85%.

He was continued on steroids which were gradually tapered down. His dyspnoea resolved completely and he began to exercise regularly and gained weight as well. A repeat spirometry after 4 months showed improvement in

FVC to 120% and FEV1/FVC ratio to 71%. Steroids were discontinued after 6 months and on follow-up he has had no recurrence. The follow up chest radiograph was also normal.

Discussion

Bleomycin, originally isolated from the fungus streptomyces verticillus is an antibiotic agent with antitumor activity.^{1,2} Bleomycin exerts its antitumor effect by inducing free radicals leading to tumor cell death and inhibiting tumor angiogenesis.³ Bleomycin is eliminated

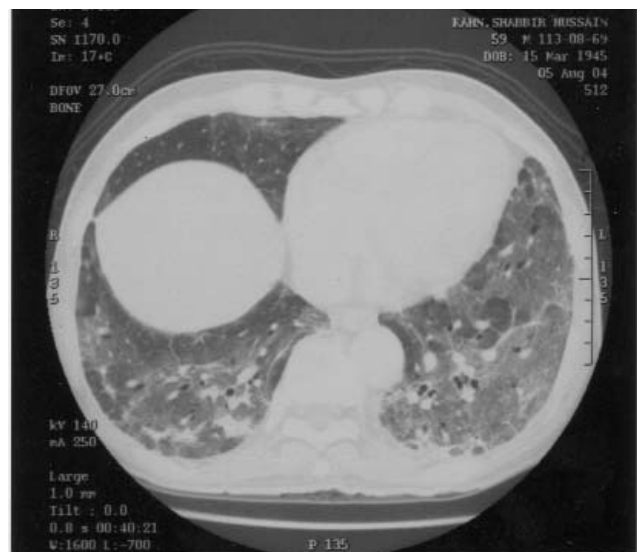


Figure 1. High resolution CT scan of chest showing diffuse ground glass opacification in both lower lung zones.

from the body mainly by the kidneys; 60% unchanged in the first 24 hours; while the rest is deactivated by the enzyme bleomycin hydrolase. Bleomycin is used in several tumor types such as germ cell tumors, lymphomas, kaposi's sarcoma, cervical cancer and head and neck malignancies.

Bleomycin use is somewhat limited due to toxicity primarily involving the lungs and the skin. Directly after administration, fever, chills and hypotension are not uncommon, however the most feared and dose limiting side effects are due to pulmonary toxicity.

These include Bleomycin induced pneumonitis (BIP) in 0-46%, bronchiolitis obliterans with organizing pneumonia and eosinophilic hypersensitivity. The mortality associated with BIP is reported in excess of 3% of all patients treated with bleomycin.⁴⁻⁶

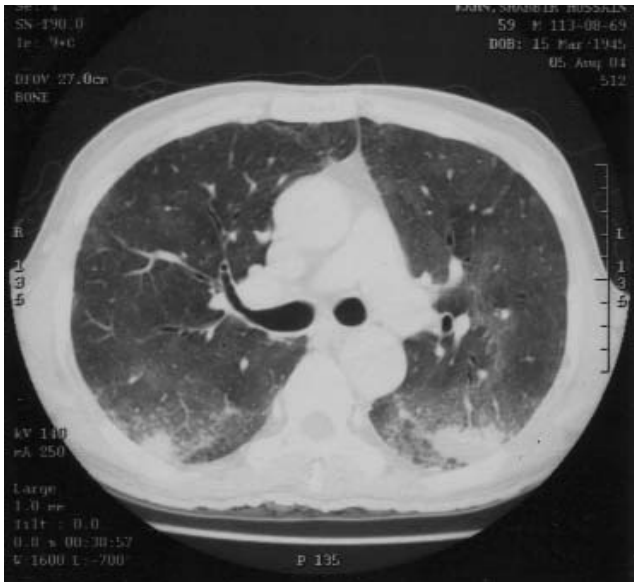

Figure 2. HRCT Chest showing pleural based nodules.

The risk factors suggested include advanced age, high cumulative dose, renal impairment, bolus administration, smoking and giving concurrent high flow oxygen and radiotherapy.^{6,7} Our patient was an older male who received only moderate doses of bleomycin (120 mg/m²), was a non-smoker and did not receive radiotherapy. Clinically our patient had a presentation 1 month after the last cycle of chemotherapy, with a sub acute presentation and typical physical exam findings and gas exchange abnormalities.^{4,5}

The high resolution CT scan of chest findings of ground glass opacities and sub pleural nodules and linear lesions are also characteristic.^{5,8}

Once infection was ruled out by a bronchoscopy, steroids at high doses were initiated. Clinically our patient had a very rapid improvement which is uncommon for BIP. If the BIP is left unchecked it may lead to progressive fibrosis and significant morbidity and mortality.^{4,5} We chose spirometry to monitor the progress of our patient which showed a gradual improvement. The treatment was discontinued and the patient on follow-up has not had any recurrence of symptoms.

Conclusion

BIP is not an uncommon complication of bleomycin related chemotherapy regimen and should always be considered if the patient presents with compatible features. It should be treated aggressively due to the significant morbidity associated with it.

References

1. Umezawa H, Meaeda K, Takeuchi T. New antibiotics, bleomycin A and B J Antibiot Ser A 1966; 19:200-5.
2. Chen J, Stubbe J. Bleomycins: towards better therapeutics. Nat Rev Cancer 2005;5:102-12.
3. Schirner M, Hoffmann J, Menrad A, Schneider MR. Antiangiogenic chemotherapeutic agents: characterization in comparison to their tumor growth inhibition in human renal cell carcinoma models. Clin Cancer Res 1998; 4:1331-6.
4. Jules-Elysee K, White DA. Bleomycin-induced pulmonary toxicity. Clin Chest Med 1990; 11:1-20
5. Sleijfer S. Bleomycin-induced pneumonitis. Chest 2001; 120:617-24.
6. Van Barneveld PWC, Van der Mark TW, Sleijfer DT, et al. Predictive factors for bleomycin-induced pneumonitis. Am Rev Respir Dis 1984; 130:1078-81.
7. O'Sullivan JM, Huddart RA, Norman AR, Nicholls J, Dearnaley DP, Horwich A, et al. Predicting the risk of bleomycin lung toxicity in patients with germ-cell tumours. Ann Oncol 2003; 14:91-6.
8. De Lena M, Guzzon A, Monfardini S, et al. Clinical, radiologic and histopathological studies on pulmonary toxicity induced by treatment with bleomycin (N.S.C.-125066). Cancer Chemother Rep 1972; 56: 343-55.