



THE AGA KHAN UNIVERSITY

eCommons@AKU

---

Department of Radiology

Medical College, Pakistan

---

April 2010

# Cerebral toxoplasmosis in a patient with acquired immunodeficiency syndrome

Rohana Naqi  
*Aga Khan University*

Muhammad Azeemuddin  
*Aga Khan University*

Humera Ahsan  
*Aga Khan University*

Follow this and additional works at: [http://ecommons.aku.edu/pakistan\\_fhs\\_mc\\_radiol](http://ecommons.aku.edu/pakistan_fhs_mc_radiol)



Part of the [Immune System Diseases Commons](#), and the [Radiology Commons](#)

---

## Recommended Citation

Naqi, R., Azeemuddin, M., Ahsan, H. (2010). Cerebral toxoplasmosis in a patient with acquired immunodeficiency syndrome. *Journal of the Pakistan Medical Association*, 60(4), 316-8.

**Available at:** [http://ecommons.aku.edu/pakistan\\_fhs\\_mc\\_radiol/35](http://ecommons.aku.edu/pakistan_fhs_mc_radiol/35)

## Case Report

### Cerebral toxoplasmosis in a patient with acquired immunodeficiency syndrome

Rohana Naqi, Muhammad Azeemuddin, Humera Ahsan  
Department of Radiology, The Aga Khan University Hospital, Karachi.

#### Abstract

Cerebral toxoplasmosis commonly affects patients with advanced HIV immunodeficiency. Toxoplasmosis in patients who are immunocompromised can be severe and debilitating in patients with Central Nervous System (CNS) involvement and the condition may be fatal.

We report the case of a 40 years old man who was a known case of HIV and presented with cerebral toxoplasmosis. His Magnetic Resonance Imaging (MRI) scan showed multiple ring enhancing lesions with extensive surrounding oedema in supratentorial as well as infratentorial region. Lesions were mainly located in the periventricular region as well as at the grey-white matter junction and showed enhancement in the periphery as well as a tiny nodular enhancement in the centre. Patient was started on Septran DS, empirically for toxoplasmosis and steroids to reduce intracranial pressure. On follow up MRI scan after 10 days there was a reduction in size, number and enhancement of the masses with decrease in the surrounding oedema. Patient was clinically stable, oriented and his fever settled. He was discharged from hospital on same medication and advised to continue regular follow-up.

#### Introduction

Toxoplasmosis, a common mass lesion in patients with acquired immune deficiency syndrome (AIDS), is caused by ubiquitous parasite, *Toxoplasma gondii*. Human infection usually occurs via the oral or trans-placental route.<sup>1</sup> In adults, most *T.gondii* infections are subclinical, but severe infections can occur in patients who are immunocompromised (A.I.D.S, Malignancy). AIDS associated toxoplasma encephalitis results from reactivation of chronic latent infection in more than 95% of patients.<sup>2</sup> In patients with AIDS seropositive for *T.gondii*, the risk for cerebral toxoplasmosis approaches 30%.<sup>3</sup> Drug therapy does not eradicate *T.gondii*, and lifelong therapy to avoid relapse is often necessary.<sup>1</sup>

Toxoplasmosis is the most common cause of focal brain lesions in patients with AIDS and frequently localizes to the basal ganglia, although other sites in the brain and spinal cord may be affected, multiple foci are seen more often.<sup>1</sup>

#### Case Report

A 40 years old male patient was diagnosed as HIV positive. Initially asymptomatic he had been bed bound for

last 2 months and unable to move his body, could not talk and for last 4 days had fever and became disoriented and stuporous. There was no history of seizures. On examination, patient was vitally stable, Glasgow Coma Scale (GCS) 7/15, neck stiffness was present, left sided gaze, increased tone bilaterally, decreased bulk, reflexes brisk and power 2/5 in all limbs was noted.

He underwent MRI brain with Gadolinium which showed multiple ring enhancing lesions of variable sizes in bilateral supra and infratentorial regions. Lesions were mainly located in the periventricular region as well as at the grey-white matter junction with extensive surrounding oedema. These were causing mass effect with midline shift. These lesions were enhancing in the periphery as well as a tiny nodule in their centre. Based on these findings, diagnosis of cerebral toxoplasmosis was suggested (Figure-1).

Further information obtained from biological and immunological studies showed raised neutrophils count, positive Toxo IgG antibodies, positive serum HIV and raised C Reactive protein. CBC showed absolute lymphocyte count 7.8%. CSF analysis and CD4 cell count were not done. Patient's chest X-ray and Ultrasounds were unremarkable.

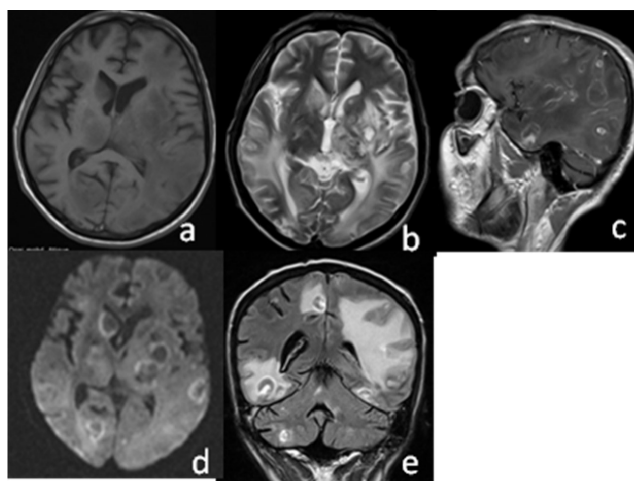


Figure-1: (a) T1-Weighted Axial MR image showing multiple hypointense lesions with perilesional edema. (b) T2-Weighted Axial MR image showing multiple hyperintense lesions of varying sizes with marked surrounding vasogenic edema. (c) Post contrast sagittal T1 image showing multiple lesions with enhancement in the periphery and centre. (d) Post contrast coronal image showing multiple supratentorial and infratentorial ring enhancing lesions with eccentric nodules: the "target sign". (e) Diffusion weighted axial MR image showing multiple ring enhancing lesions of varying sizes.

Brain biopsy was deferred because of financial constraints and the patient was started on Septran DS empirically for toxoplasmosis and steroids to reduce intracranial pressure. He was also given Paracetamol, Clarithromycin and rehydrated with intravenous fluids.

Follow-up MRI scan with Gadolinium performed after ten days re-demonstrated multiple ring enhancing lesions of various sizes in supra and infratentorial region. These demonstrated mixed signals on T1, hyperintense on T2-Weighted and Flair images. Post contrast images showed peripheral and central enhancement. On Susceptibility Weighted images the lesion showed susceptibility effect. However on comparison with previous MRI scan there was reduction in size, number and enhancement of the masses as well as the surrounding oedema. Lesions showed haemorrhagic component in them (Figure-2).

Patient was clinically stable, oriented had started taking orally and his fever settled. He was discharged from hospital on same medication and advised to continue regular follow-up.

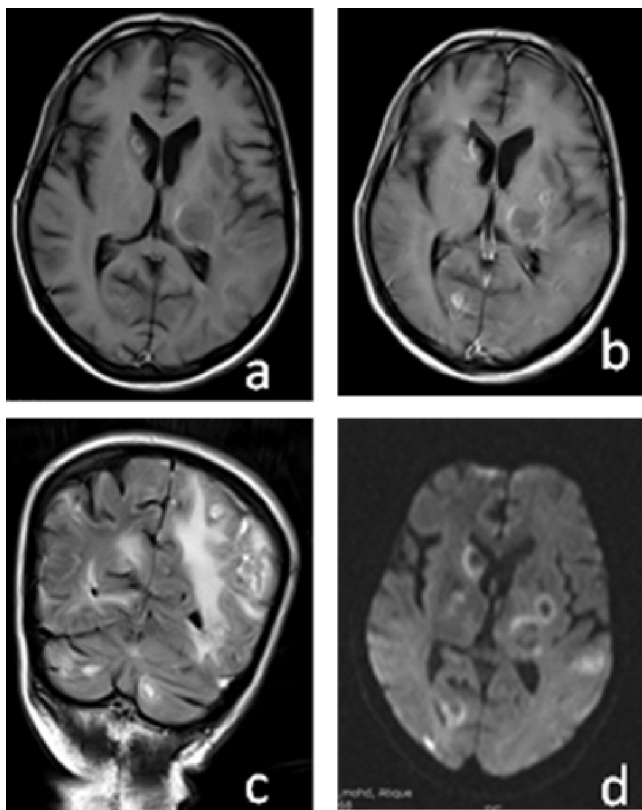


Figure-2: (a): Follow up T1-Weighted axial MR Image shows multiple lesions with mixed hypo and hyperintense signal and markedly reduced surrounding edema. (b) Post contrast axial MR image shows multiple ring enhancing lesions, reduced in size, number and enhancement with markedly reduced surrounding edema. (c) Coronal Flair post contrast image shows multiple enhancing lesions in supratentorial and infratentorial region. (d) Diffusion weighted MR Image showing multiple ring enhancing lesions.

## Discussion

Diagnosis of toxoplasmosis is made clinically, radiologically and by serology, histology or by molecular methods. Toxoplasmosis associated with HIV infection manifest primarily as toxoplasmic encephalitis and is a frequent cause of focal CNS lesions. Characteristically, toxoplasmic encephalitis presents with headache, altered mental status and fever. Most common focal neurological signs are motor weakness, speech disturbance. Patients can present with seizures, cranial nerve abnormalities, visual field defects, sensory disturbances, cerebellar dysfunction, meningismus, movement disorders and neuropsychiatric manifestations.<sup>4</sup> Ocular and pulmonary diseases are the most common presentations in patients with cerebral toxoplasmosis.<sup>5</sup> Toxoplasmosis rarely presents as a rapidly fatal form of diffuse encephalitis.

The most commonly used serologic tests to detect the presence of anti-T gondii IgG and IgM. IgG antibodies can be detected with the Sabin Feldman dye test (considered to be the gold standard). CSF from patients with toxoplasmic encephalitis may reveal mild pleocytic mononuclear predominance and protein elevation.<sup>6</sup> Polymerase chain reaction (PCR) based detection of T.gondii DNA has sensitivity of 12-70 % and specificity of 100% in patients with toxoplasmic encephalitis.<sup>7</sup> Toxoplasmosis can be diagnosed by isolation of T.gondii from culture of body fluids (Blood, CSF, and bronchoalveolar lavage fluids) or tissue biopsy.

The cranial imaging features on CT and MRI are not pathognomonic, but their distribution or appearance may have predictive value. MRI is the best initial screening procedure for CNS toxoplasmosis. CT scan reveals multiple, bilateral, hypodense contrast enhancing focal brain lesions in 70-80% of patients. These lesions tend to involve basal ganglia and hemispheric corticomedullary junction. Contrast enhancement often shows a ring like pattern surrounding the lesion. Toxoplasmic encephalitis may less frequently present with single lesion or with no lesion on CT scan.<sup>8</sup>

MRI is more sensitive and is the preferred imaging technique especially in patients with focal neurological abnormalities. Typical radiological findings comprise of bilateral, multiple, ring enhancing lesions over basal ganglia and corticomedullary junctions of cerebral hemisphere. In approximately 14% of cases, the lesions are solitary. Haemorrhage may be seen occasionally, a finding that can help differentiate toxoplasmosis from lymphoma which typically does not bleed before treatment. Occasionally a small eccentric nodule rests alongside an enhancing ring; the "target sign" is highly suggestive of toxoplasmosis. However, it is seen in less than 30% of

cases. Surrounding oedema and mass effect are present in varying degrees.<sup>8</sup>

The most important differential diagnosis is CNS lymphoma. Features that favor the diagnosis of *T.gondii* encephalitis over CNS lymphoma include: subcortical lesions, more than three lesions, absence of ependymal or leptomeningeal involvement, marked perilesional oedema, absence of hyper attenuation on non enhanced CT scans or slender uniform ring enhancing foci.<sup>9</sup> Diffusion weighted imaging has been suggested to help differentiate between the two diseases, as lymphoma typically has restricted diffusion. Unfortunately, toxoplasmosis demonstrates a wide range of diffusion characteristics which can overlap with those of lymphoma.<sup>8</sup> Increased uptake in SPECT or PET can enhance the specificity for the detection of CNS lymphoma.

Brain biopsy showing tachyzoites or cyst provides a definitive diagnosis for toxoplasmosis encephalitis. Conservative approach is particularly helpful when the lesion is surgically inaccessible. Combination of Pyrimethamine /Sulfadiazine and folinic acid is considered the standard regime for the treatment of toxoplasmosis encephalitis.<sup>6</sup> Short course of corticosteroids can be used in toxoplasmosis encephalitis patients with significant cerebral edema and elevated intracranial pressure. Toxoplasmosis will reoccur if therapy is discontinued.<sup>8</sup>

Empirical treatment for *T.gondii* should be started on patients with multiple ring enhancing lesions on MRI, positive serology for *Toxoplasma IgG*, and absolute CD4 count less than 200 cells/mm<sup>3</sup>.<sup>4</sup>

If an empiric course of treatment is begun for toxoplasmosis without biopsy, then a repeat cranial study is recommended. If CT or MRI findings are unchanged, then biopsy is indicated. Both CT and MRI may be used for follow up after treatment. In our case the appearance of the lesions was very characteristic as there were a number of "target Lesions" in the brain. Also the distribution of the

lesions was also typical in our case. We used MRI to follow up the case to see the response.

Primary prophylaxis should be considered in HIV patients with CD4 cell counts less than 200 and positive *Toxoplasma IgG* titers. Prophylaxis can be discontinued when the patients CD4 cell count has returned to over 200 for atleast 6 months.<sup>4</sup>

HIV infected persons should be tested for baseline *IgG* antibodies to *Toxoplasma* to detect latent infection with *T. gondii*. All HIV infected persons should be counselled regarding exposure to toxoplasmic infection. (a) Avoid eating raw or undercooked meat. (b) Wash hands after contact with raw meat. (c) Wash fruits and vegetables well. (d) Avoid handling cat's litter.<sup>10</sup>

## References

1. Khan AN, Turnbull I, Al Okaili R. Toxoplasmosis, CNS. (Online) 2010. Available from URL: <http://emedicine.medscape.com/article/344706-overview>.
2. Dahner W. Radiology Review Manual. Central Nervous System, 5th ed. Philadelphia: Lippincott, Williams and Wilkins, 2003; pp 323-4.
3. Edelman RR, Hesselink JR. Clinical Magnetic Resonance Imaging. Infectious and inflammatory diseases, 3rd ed. Philadelphia: Saunders, Elsevier Co, 2006' pp 1274-6.
4. Rathore MH. Neurological manifestations of HIV-Associated Infections (Part-I). *Infect Dis J* 2005; 14: 51-6.
5. Rabaud C, May T, Amiel C, Katlama C, Leport C, Ambroise-Thomas P, et al. Extracerebral toxoplasmosis in patients infected with HIV. A French National Survey. *Medicine (Baltimore)* 1994; 73: 306-14.
6. Montoya JG, Kovacs JA, Remington JS. *Toxoplasma gondii*. In : Mandell GL, Bennett JE, Dolin R. Principles and Practice of Infectious Diseases. 6th ed. Philadelphia: Churchill Livingstone, 2005; pp 3170-98.
7. Parmley SF, Goebel FD, Remington JS. Detection of *Toxoplasma gondii* in cerebrospinal fluid from AIDS patients by polymerase chain reaction. *J Clin Microbiol* 1992; 30: 3000-2.
8. Smith AB, Smirniotopoulos JG, Rushing EJ. From the archives of the AFIP: central nervous system infection associated with human immunodeficiency virus infection: radiologic pathologic correlation. *Radiographics* 2008; 28: 2033-58.
9. Dunn IJ, Palmer PE. Toxoplasmosis. *Semin Roentgenol* 1998; 33: 81-5.
10. No author listed. 1999 USPHS/IDSA guidelines for the prevention of opportunistic infections in persons infected with Human Immunodeficiency Virus. US Public Health Service (USPHS) and Infectious Diseases Society of America (IDSA). *MMWR Recomm Rep* 1999; 48: 1-59, 61-6.