



THE AGA KHAN UNIVERSITY

eCommons@AKU

---

General Surgery, East Africa

Medical College, East Africa

---

February 2007

# An unusual abdominal mass: case report

H. Saidi

*Aga Khan University*

U. Mohammed

*Aga Khan University*

M. Machoki

*Aga Khan University*

Follow this and additional works at: [http://ecommons.aku.edu/eastafrica\\_fhs\\_mc\\_gen\\_surg](http://ecommons.aku.edu/eastafrica_fhs_mc_gen_surg)



Part of the [Radiology Commons](#), and the [Surgery Commons](#)

---

## Recommended Citation

Saidi, H., Mohammed, U., Machoki, M. (2007). An unusual abdominal mass: case report. *East African Medical Journal*, 84(2), 88-92.

Available at: [http://ecommons.aku.edu/eastafrica\\_fhs\\_mc\\_gen\\_surg/8](http://ecommons.aku.edu/eastafrica_fhs_mc_gen_surg/8)

*East African Medical Journal Vol. 84 No. 2 February 2007*

**AN UNUSUAL ABDOMINAL MASS: CASE REPORT**

H. Saidi, BSc (Anat), MBChB, MMed (Surg), FCS, Department of Surgery, Aga Khan Hospital, Nairobi and Department of Human Anatomy, College of Health Sciences, University of Nairobi, P.O. Box 30197-00100, Nairobi, Kenya, U. Mohammed, MBBS, FCPS, Department of Radiology and M. Machoki, MBChB, Department of Surgery, Aga Khan Hospital, P.O. Box 30270-00100, Nairobi, Kenya

Request for reprints to: Dr. H. Saidi, Department of Human Anatomy, College of Health Sciences, University of Nairobi, P.O. Box 30197-00100, Nairobi, Kenya

## AN UNUSUAL ABDOMINAL MASS: CASE REPORT

H. SAIDI, U. MOHAMMED and M. MACHOKI

### SUMMARY

The causes of intra-abdominal masses associated with chronic abdominal pain range from the benign to malignant; common to bizarre and some raise major medical-legal issues. We present a case of a 40-year old African lady who presented with chronic right-sided abdominal pain with an associated mass on the right mid-abdomen. She had had a Caesarian section one year prior to presentation. Antecedent history of surgery and typical imaging features enabled a preoperative diagnosis of abdominal mass secondary to retained surgical gauze. The case illustrates the fallibility of the men and women in the operating theatres and the vital role of correct instrument and sponge counts.

### CASE REPORT

Mrs. X was a 40-year old African lady, who first presented to our out-patient department due to increasing pain in the right mid abdomen for the preceding two months. She had also noticed a non-progressive swelling in the same region in the preceding two weeks. An abdominal ultrasound demonstrated a right-sided intra-abdominal mass and the patient then referred to the surgical clinic for further evaluation. Her pain was dull and occasional initially, but got worse a week before presentation. The pain had no aggravating or relieving factors, no associated fever, night sweats, rigors or chills and radiated neither to the back nor to the groin.

The swelling in the right mid-abdomen was more obviously felt while lying down with the abdomen relaxed. There was no associated change in bowel habit nor was there a change in appetite or loss of weight. Her urine was clear and micturition painless. She had not noticed any change in urine frequency. She had no family history of either abdominal or gynaecological malignancy.

Significant past medical and surgical history was treatment for peptic ulcer disease and that both her children had been delivered via Caesarian sections at outside institutions. The last Caesarian section was one year prior to the symptomatology. At the time of presentation she had regular menses with normal flow.

On physical examination, she was a middle-aged lady in good general condition, good nutrition and no stigmata of chronic disease. She weighed 88 Kilograms and was 5'6' tall (body mass index of 30.9 kg/m<sup>2</sup>). She had no lymphadenopathy, finger clubbing or jaundice. Her vital signs were within normal ranges.

Abdominal examination was significant for an eight centimetre diameter palpable mass in the right mid abdomen. It felt firm and mobile with no attachment to underlying structures or the skin. The mass was slightly tender and was not pulsatile. Bowel sounds were present and normal. Rectal and vaginal examinations were normal.

The clinical diagnosis at this point was a right-sided abdominal mass with the differential

diagnoses including mesenteric tumor, cecal mass, appendicular mass or pedunculated gynaecological tumor. Her hematological and biochemical investigations were all normal (Table 1). The urine analysis was normal.

**Table 1**

*Haematological and biochemical indices in a patient with retained gauze*

Test	Results	Normal range
WBC (N 55%, L40%, M2%, E3%)	5.7	4.8 – 10.8
Haemoglobin	14.5 g/dl	12 – 16 g/dl
Plateletes	347	150 – 400
Potassium	4.2	3.5 – 4.9 mmol/l
Sodium	139	135 – 149 mmol/l
Creatinine	81	60 – 124 umol/l
Urea	4.9	2.5 – 6.7 mmol/l

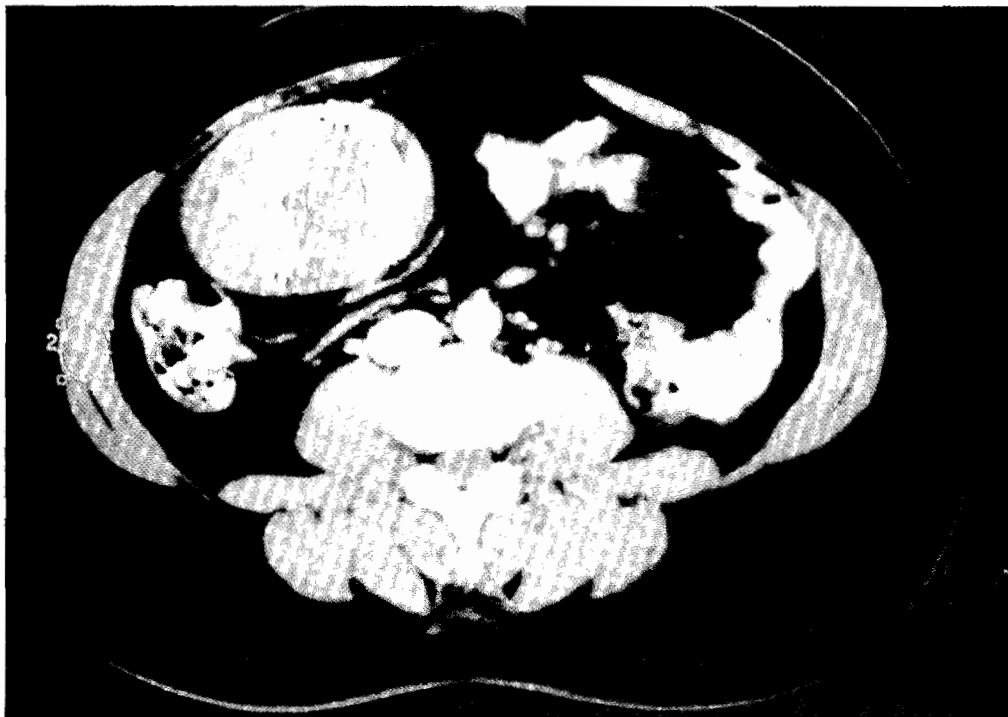
We reviewed her ultrasound scan that revealed a normal uterus, normal ovaries and adnexae. A

7.32 by 2.99 cm mass lay in the right iliac fossa at the level of the umbilicus. This was shown to be a well-defined soft tissue mass in the right lower abdomen on CT scan. It measured 8.5 by 7.6 cm and contained multiple radio-opaque densities, separate from all bowel loops. There was no evidence of inflammation in the surrounding fat (Figure 1). The serpentine linear opacities over the right portion of the abdomen and seen on the scout film (Figure 2) were diagnostic of retained surgical gauze.

The patient was appraised of the clinical and radiological diagnoses and consented to surgery. At laparotomy, we found a mass at the right iliac fossa. It measured 10 cm in diameter and was attached to the lateral abdominal wall, the omentum, part of the transverse colon and caecum. It was excised in total and found to consist of a walled-off abscess containing a single large abdominal surgical gauze (Figure 3). The liver, spleen and intestines appeared normal. The post-operative period has been uneventful. The histopathology report confirmed an abscess wall with gauze. The final diagnosis was Gossypiboma.

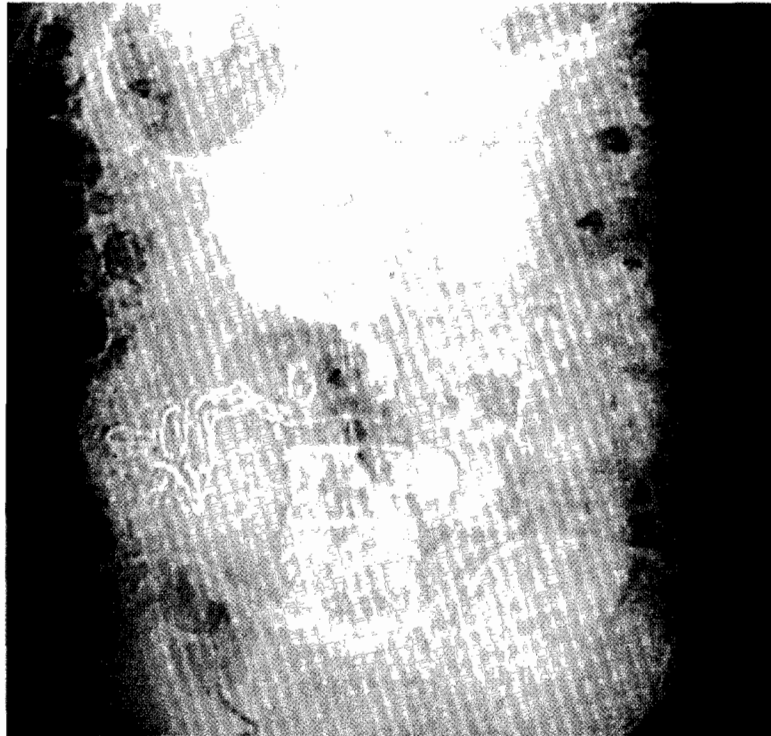
**Figure 1**

*Abdominal computed tomography scan for patient X, three months following Caesarian-section. Note the characteristic rounded soft tissue non-homogenous mass with whirl-like pattern*

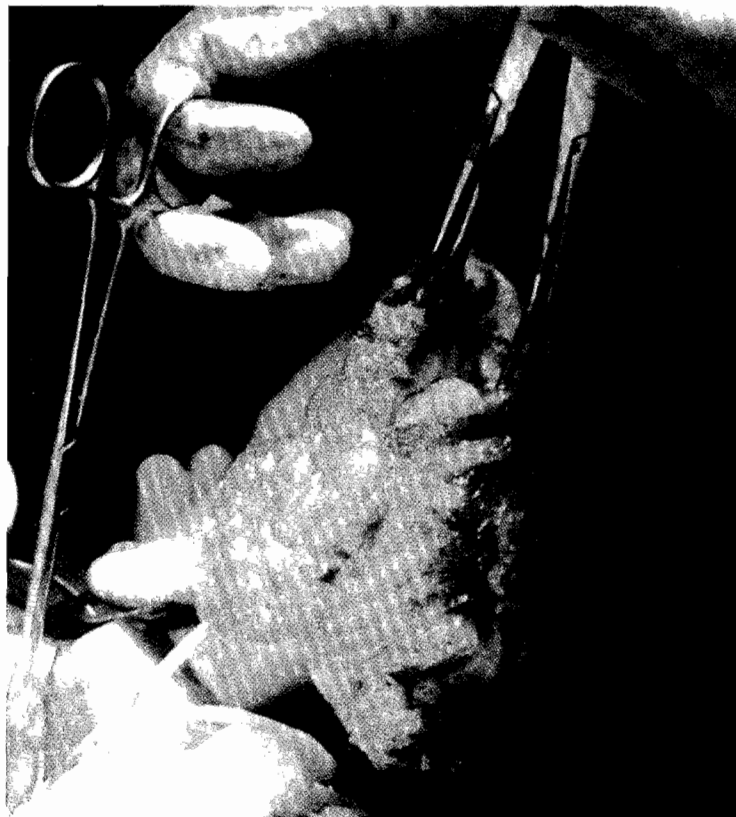

**Figure 2**

*Scout film of the abdomen showing serpentine linear opacities over the right portion of abdomen*

**Figure 3**

*Excised mass at laparotomy. Notice the thick wall lining a cavity containing the folded large abdominal gauze pad*



## DISCUSSION

The term *gossypiboma* derives from the words *gossium* (cotton) and the swahili word *boma* (housing or place of concealment) (1). There is also an occasional meaning of *gossypiboma* that relates to the attended gossip that follows its exposure (2). The true incidence of *gossypiboma* is difficult to estimate as published reports are limited by fears of initiating medical-legal suits and critical press coverage (3). Further, some patients may remain asymptomatic for years. This is the first report from our institution and the only case in recent times. It is estimated that the rate lies somewhere between 1/8,801 to 1/18,760 inpatient operations at non-specialty acute care hospitals, corresponding to one case or more each year for a typical large hospital (3). Although the local incidence of retained surgical gauze remains unclear and possibly very low, we believe it is important not only from a medical-legal standpoint but for the significant associated morbidity and mortality.

Our patient has had to undergo a second operation for symptomatic abdominal swelling. Although the postoperative outcome was excellent, the financial implication for the preoperative work-up and laparotomy was immense. Sometimes the outcome is less optimal (4,5) in repeat operations. In a review of retained gauzes at a university hospital in Jordan, Bani-Hani reported one death out of their series of eleven patients (5).

A number of factors are associated with retention of surgical implements and sponges/gauze. These include emergency surgery; complex surgery involving more than one team; change-over in the nursing team during surgery; high body mass index of the patient; procedures involving a lot of blood loss and abdominal/pelvic surgery (3). Our patient had undergone an earlier emergency Caesarian section through a Pfannenstiel incision. We contend that the emergency nature of her operation complicated by the surgical approach and her body habitus contributed to the iatrogenic complication being reported here. Emergency operations are more likely to be associated with failure to perform correct sponge counts (3,5). The low incision in a capacious abdomen may lend a lost sponge difficult to visualise at the end of the laparotomy. Although reports suggest that emergency surgery is the culprit in a number of cases of retained sponges, one must consider a diagnosis of retained

sponges after any laparotomy. In a recent Israeli case report, one half of the patients had undergone elective abdominal operations (4).

Presentation may be acute with symptoms and signs of abscess formation, peritonitis and intestinal obstruction or chronic with vague abdominal discomfort/pain, mass, adhesions, fistulae and rarely with transmigration of the swab or instrument through the hollow viscus (intestines or bladder) (6,7).

The CT scan examination facilitated the preoperative diagnosis of *gossypiboma* in this case. The classical CT scan features include soft tissue mass with air bubbles and a whirl like or spongiform pattern (8,9). Other imaging modalities also facilitate diagnosis. They would usually have been ordered for evaluation of the abdominal mass rather than retained gauze per se. On scout films, a whirl-like appearance is characteristic (10). The ultrasound typically shows a well-delineated mass containing wavy internal echo with a hypoechoic rim and a strong posterior acoustic shadowing (11).

The retention of instruments and swabs in body cavities illustrate a weakness to be overcome. The development of radio-opaque sponges, protocols of double counting of instruments and sponges and surgical training that insists on routine exploration of the abdomen after operation are all meant to minimize the incidence. Avoiding hurried counts during long procedures, usage of packs during fascial closure and use of intra-operative radiology in situations of multiple procedures and where multiple disciplines have been involved are additional measures (12). We call for rededication to theatre protocols of strict sponge and instrument counts and correct count documentation. Possibility of a retained sponge should be entertained in abdominal complaints following laparotomy.

## REFERENCES

1. Williams R.G., Bragg D.G. and Nelson J.A. *Gossypiboma — the problem of the retained surgical sponge. Radiol.* 1978; **129**: 323-326.
2. Montes B.B., Yilmaz E., Sen M., et al. Transgastric migration of a surgical sponge. *J. Clin. Gastroenterol.* 1997; **24**: 55-57.
3. Gawande A.A., Studdert D.M., Orav E.J., et al. Risk factors for retained instruments and sponges after surgery. *N. Eng. J. Med.* 2003; **348**: 229-235.

4. Tacyildiz I. and Aldemir M. Acta: The mistakes of surgeons: "gossypiboma." *Chir. Belg.* 2004; **104**: 71-75.
5. Kamal E., Bani-Hani and Kamal A. Gharaibeh and Rami J. Retained surgical sponges (Gossypiboma) *Asian J. Surg.* 2005; **28**: 109-115.
6. Hyslop J. and Maull K. Natural history of the retained surgical sponge. *South Med. J.* 1982; **75**: 657-660.
7. Robinson K.B. and Levin E.J. Erosion of retained surgical sponges into the intestine. *Amer. J. Roentgenol.* 1966; **96**: 339-343.
8. Choi B.I., Kim S.H., Yu E.S., *et al.* Retained surgical sponge: Diagnosis with CT and sonography. *Amer. J. Roentgenol.* 1988; **150**: 1047-1050.
9. Liessi G., Semisa M., Sandini F., *et al.* Retained surgical gauzes: acute and chronic CT and US findings. *Eur. J. Radiol.* 1989; **9**: 182-186.
10. Kokubo T., Itai Y., Ohtomo K., *et al.* Retained surgical sponges: CT and US appearance. *Radiol.* 1987; **165**: 415-418.
11. Chau W.K., Lai K.H. and Lo K.J. Sonographic findings of intra-abdominal foreign bodies due to retained gauze. *Gastrointest. Radiol.* 1984; **9**: 61-63.
12. Jawaid M. Gossypiboma – the forgotten swab. *Pak. J. Med. Sci.* 2003; **19**: 141-143.