



THE AGA KHAN UNIVERSITY

eCommons@AKU

Department of Pathology and Laboratory Medicine

Medical College, Pakistan

July 1996

Subcutaneous phaeohyphomycosis: Infection with pigmented fungi

I N. Soomro
Aga Khan University

A Kennedy

Follow this and additional works at: https://ecommons.aku.edu/pakistan_fhs_mc_pathol_microbiol



Part of the [Microbiology Commons](#), and the [Pathology Commons](#)

Recommended Citation

Soomro, I. N., Kennedy, A. (1996). Subcutaneous phaeohyphomycosis: Infection with pigmented fungi. *Journal of Pakistan Medical Association*, 46(7), 156-158.

Available at: https://ecommons.aku.edu/pakistan_fhs_mc_pathol_microbiol/1022

Subcutaneous Phaeohyphomycosis: Infection with Pigmented Fungi

Pages with reference to book, From 156 To 158

Irshad Nabi Soomro (Department of Pathology, The Aga Khan University Hospital, Karachi.)
Alexander Kennedy (Northern General Hospital, Herries Road, Sheffield S5 7AU.)

Introduction

Phaeohyphomycosis falls into a large group of diseases caused by Dematiaceous fungi and is a well known deep fungal infection having a worldwide distribution, but principally localized to the tropics and subtropics. It is broadly categorized into subcutaneous and systemic forms, the latter being more common in the immunocompromised host, often with visceral dissemination^{1,2}, although examples in the immunocompetent population are not unknown^{3,4}. There are numerous species of about twenty genera which are distinguishable by their growth pattern in culture and are characterised by thin, septate, branched or unbranched hyphae with brown to yellow pigmentation of their cell walls. These need to be distinguished from chromoblastomycosis which have spherical pigmented fungus cell⁵. Agents causing phaeohyphomycosis are most commonly found in decaying wood and soil, hence, the infection is more common in gardeners and farmers⁶. During the past ten years, there has been significant increase in the number of phaeohyphomycotic infections in humans⁷, although it is debatable whether the increase is real or due to the increasing awareness of its existence. Because of the relative rarity of this infection in the United Kingdom, we describe three cases of subcutaneous phaeohyphomycosis diagnosed at the Northern General Hospital in Sheffield between 1984-93 in immunocompetent non- white patients.

Case Report

Case 1

A 29 years old Pakistani male presented to his general practitioner with a lesion at the base of dorsal aspect of the left middle finger which was clinically suspected to be either a ganglion or an implantation dermoid. The patient was otherwise healthy. This lesion was excised and appeared as a smooth grey nodule measuring 1x0.8x0.6 cm which contained pus in the centre.

Case 2

A 41 years old West Indian male had a tender lump over right olecranon region which had been present for several years and had been drained once previously. On examination he had a mobile subcutaneous cystic lesion approximately 1 cm in maximum dimension. The general health of the patient was normal. The lesion was excised and appeared as an ovoid mass 1.2x0.8x0.4 cm. On section there was a small central cavity.

Case 3

A Pakistani man presented with a swelling in the suprapatellar region of the right knee which was diagnosed as a ruptured ganglion. It was excised in two pieces and consisted of white fibrous tissue measuring 2x1.5x1 cm and 1.5x1x1 cm containing cream coloured nodular foci. The cut-surface was nodular with a small central cavity.

Pathology

The specimens from all the three patients were processed conventionally and stained with

haematoxylin and eosin for routine histological examination. Representative blocks from each of these cases were cut and stained with PAS, Grocott's methanamine silver and ZN for acid fast bacilli. Histological examination revealed virtually identical changes in all the three cases which consisted of mainly fibrous tissue in the centre of which there were necrotizing granulomas formed by palisaded histiocytes surrounding a large number of polymorphs and necrotic debris in the centre of each granuloma. In two cases birefringent foreign material surrounded by giant cell was noted. At the edges of these granulomas occasional chestnut brown coloured fungal spores and hyphae were seen which could easily be missed on casual examination (Figures 1 and 2).

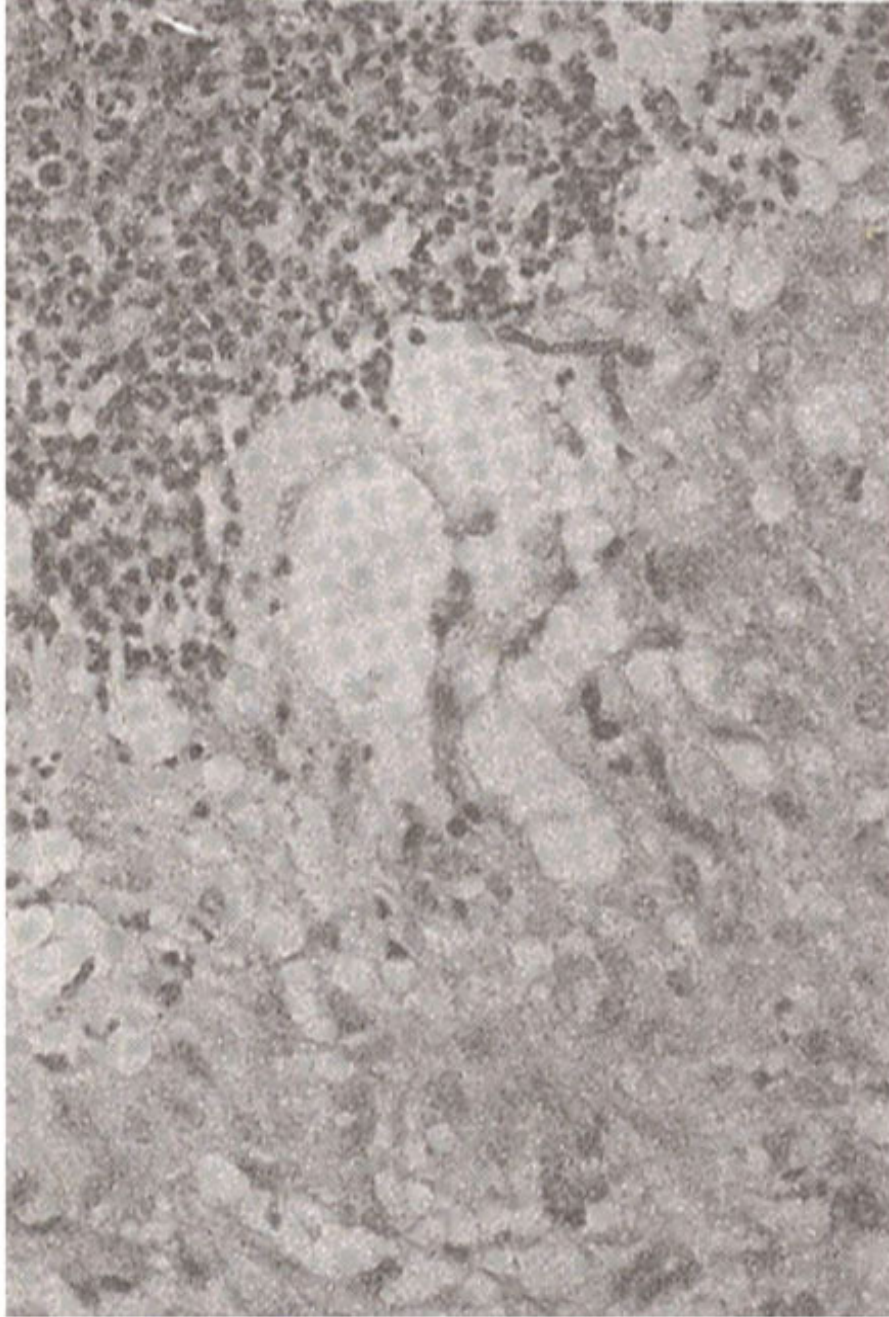


Figure 1. Phaeohyphomycosis. The fungal hyphae are located close to the abscess cavity.

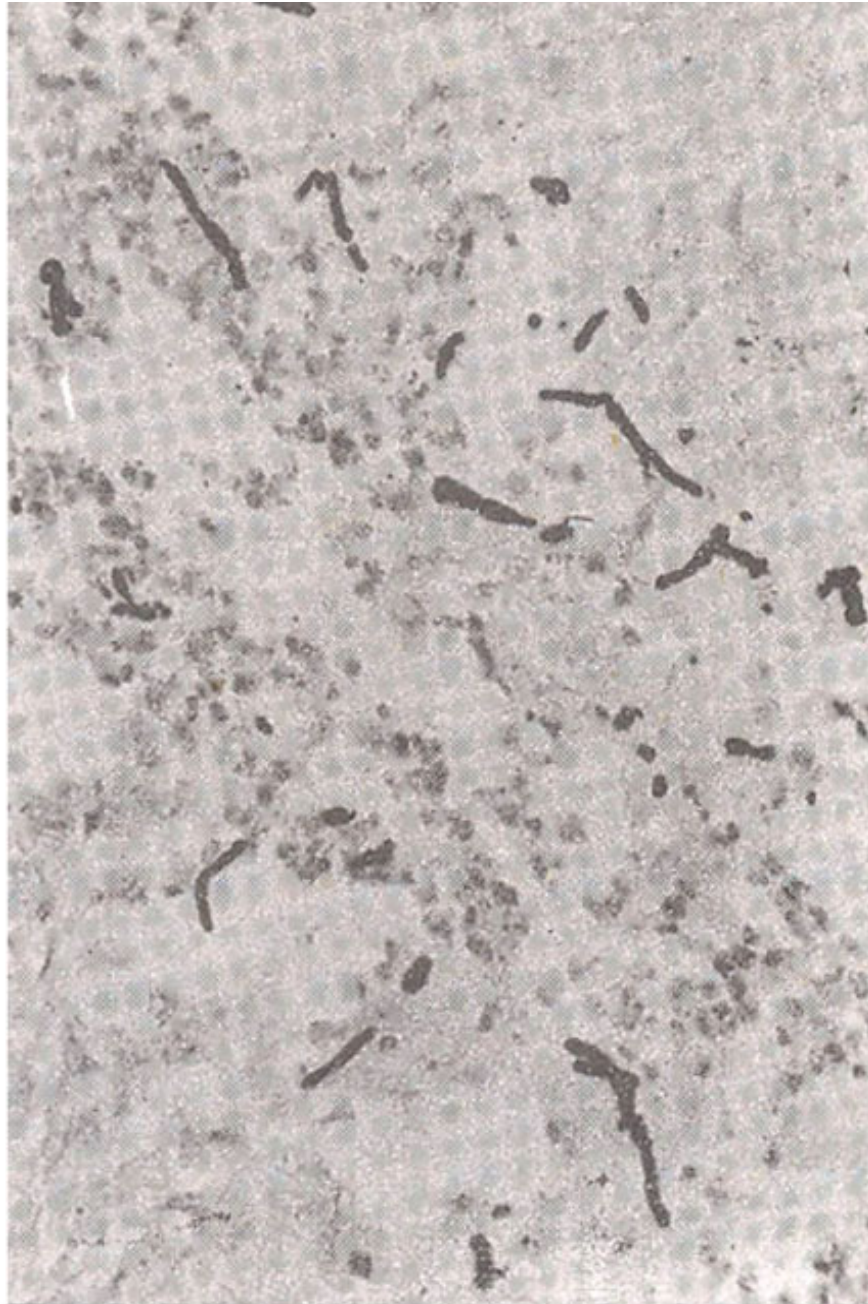


Figure 2. The fungus cells overlooked on H&E staining are best demonstrated by special stains such as PAS as in this case.

Indeed in the third case only two spores were found after a careful search. Staining with PAS revealed a large number of fungi mostly formed by round spores upto 15 urn in diameter producing hyphae with occasional branches (Figure 3).

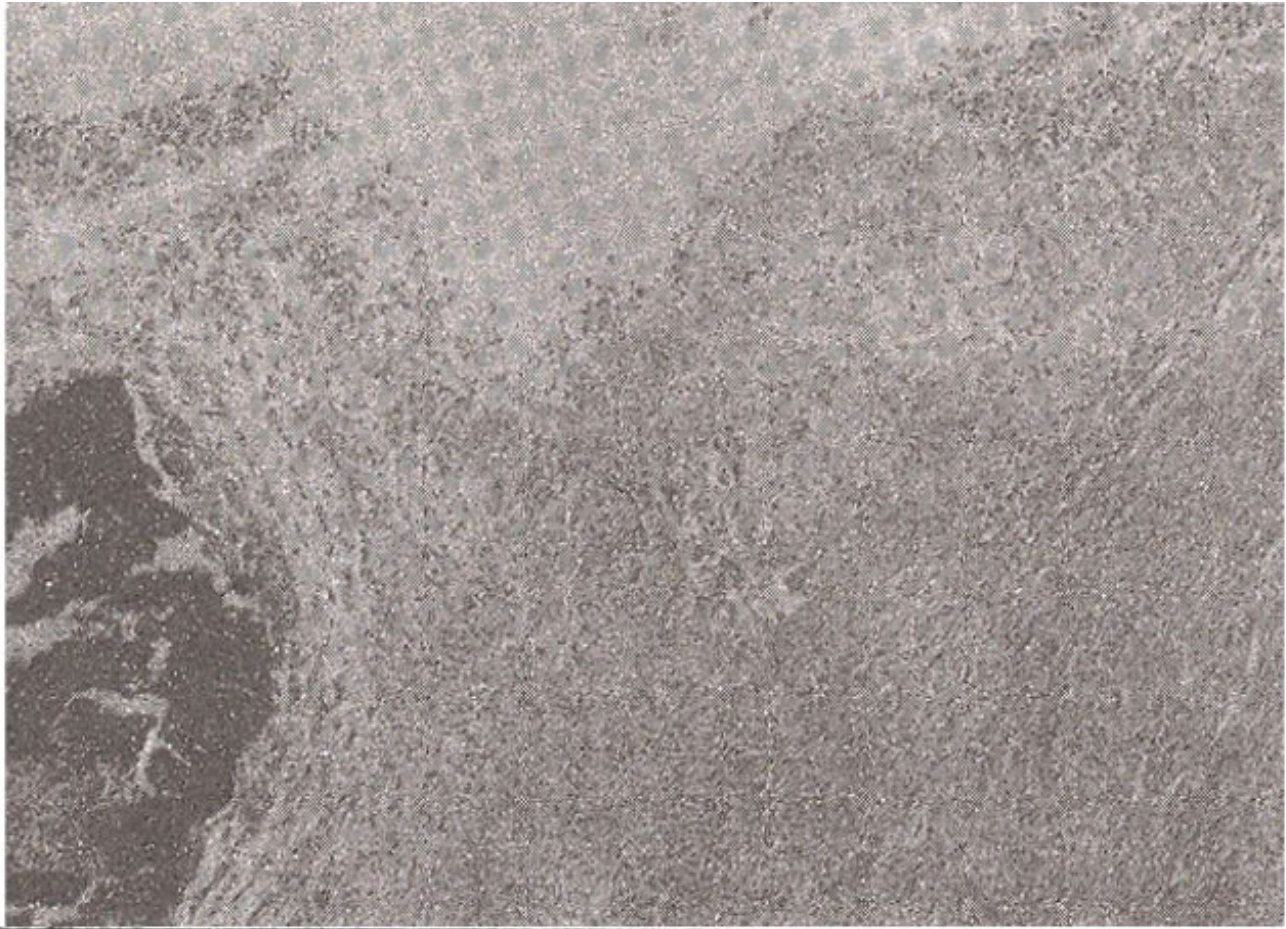


Figure 3. Adjacent to the abscess cavity implanted foreign material is seen and in the centre of the picture many fungal hyphae are visualised.

The appearances were those of infection with phaeohyphomycosis, also known as cystic chromomycosis and is caused by infection with pigmented fungi. Since the overlying epidermis was not included in the specimens of these three cases, it was not possible to comment on the presence or absence of pseudoepitheliomatous hyperplasia as has been described in some reports². Similarly, since the tissue was received fixed in formalin, it was not possible to send fresh material for culture. It was not, therefore, possible to further categorize these fungi.

Discussion

Mehta et al described a case of phaeohyphomycosis of the paranasal sinuses masquerading as a neoplasm in which the fungi were not identified on the histologic examination possibly due to the paucity of fungal elements. It was only after the tissue was sent for culture which revealed *Fonseca pedrosoi*. This species is now classified under a group of infections caused by pigmented fungi called chromoblastomycosis rather than phaeohyphomycosis and show spherical fungus cells rather than hyphae⁵. Ever increasing number of species identified and confusing nomenclature of these infective agents make it very important to use the correct terminology as defined in standard text books and articles. This case also raises an important question, of whether clinicians should always submit fresh tissue for culture in similar situations. The cases described in this report bear strong resemblance to nine patients from Malawi described by Donnel and Hutt⁸. In two of our cases there was evidence of foreign material, whereas in this case the pus had been drained on a previous occasion and it is

possible that foreign material was lost during this procedure. These findings strongly suggest that these pigmented fungi are implanted during injury and contamination with foreign matter, such as decaying wood and soil. The presentation of all three cases was very similar. We feel that this condition should always be considered in the differential diagnosis of a chronic progressive cutaneous lesion such as a cold abscess as suggested by

Symmers⁹ The history of injury may not always be available and the immune status of the patient may be completely normal, as in these three cases. There was no recent history of foreign travel but a case of a patient who had never left the British Isles has been described¹⁰. It is possible that infection was acquired in the past without patient realizing and remained dormant. These lesions can be chronic and indolent, progressing gradually over months and sometimes years without spread to other viscera. Thorough examination of the histology in these patients is advised as these organisms can be easily missed. We, therefore, recommend that special fungal stains should be employed 'in similar situations, although natural brown colour of the hyphae is masked by Grocott's and other methods⁵. The recommended treatment for subcutaneous phaeohyphomycosis is surgical excision and drainage of the pus whereas the systemic infections had been treated variedly in the past including fluorocytosine, thiabendazole, amphotericin B, local heat, cryosurgery, ketoconazole and itraconazole depending on the immune status of the patient and location of the lesion⁶.

Acknowledgements

We wish to thank Dr. Robert Laing and Jenny Williams for their help in preparing this manuscript.

References

1. Aldape, K.D., Fox, H.S., Roberts, J.P. et al. Cladosporium trichoides cerebral phaeohyphomycosis in a liver transplant recipient. Report of a case. Am. J. Clin Pathol 1991 ;95:499-502.
2. Grcne, iN., Foulis, P.R. and Yangco, 8G. Chromomycosis in a steroid-dependent patient with chronic obstructive pulmonary disease Am. J. Med. Sci., 1990;299:54-7.-
3. Herrey, C., Song, E., Kellen, A. et al. Cerebral phaeohyphomycosis caused by Xylophabantiana. Eur. J. Microbiol. Infect. Dis., 1989;8:984-8.
4. Aviv, J.E., Lawson, W., Bottone, E.J. et al. Multiple intracranial mucococci associated with phaeohyphomycosis of the paranasal sinuses. Arch. Otolaryn. go!. Head Neck Surg., 1990;116:1210-3.
5. Salfelder, K., de-Liscano, T.R. and Saucrteig, E. Phaeohyphomycosis In Gresham, GA., eds. Atlas of Fungal Pathology, Lancaster, Kluwer, 1990, pp.56-59.
- 6 Gross, D.J. and Schosser, RI! Chromomycosis of the nose Arch. Dermatol. 1991;127:18312-18345.
7. Singh, SM., Naidu, J., Pouranik M. Ungual and cutaneous phaeohyphomycosis caused by altermaria altermata and alternaria chlamdospora. J. Med. Vet. Mycol.. 1990;28:275-78.
- 8 Donnel, PJ and Hutt, M.S.R Subcutaneous phaeohyphomycosis: A histopathological study of nine cases from Malawi. .1. Clin. Pathol., 1985;38:288.292.
9. Symmers, W.S C New style cold abscesses Br. Med. J., 1971 ;ii:337.