



THE AGA KHAN UNIVERSITY

eCommons@AKU

---

Department of Surgery

Department of Surgery

---

June 2019

# Radial forearm free flap: A dynamic flap for single-staged multiple subunit reconstruction

Muhammad Ubaid Khan

*Aga Khan University*

Safdar Ali

*Aga Khan University*

Muhammad Asif Ahsan

*Aga Khan University, asif.ahsan@aku.edu*

Follow this and additional works at: [https://ecommons.aku.edu/pakistan\\_fhs\\_mc\\_surg\\_surg](https://ecommons.aku.edu/pakistan_fhs_mc_surg_surg)

---

## Recommended Citation

Khan, M. U., Ali, S., Ahsan, M. A. (2019). Radial forearm free flap: A dynamic flap for single-staged multiple subunit reconstruction. *Journal of Pakistan Medical Association*, 69(6), 905-908.

**Available at:** [https://ecommons.aku.edu/pakistan\\_fhs\\_mc\\_surg\\_surg/781](https://ecommons.aku.edu/pakistan_fhs_mc_surg_surg/781)

## Radial forearm free flap: A dynamic flap for single-staged multiple subunit reconstruction

Muhammad Ubaid Khan, Safdar Ali, Asif Ahsan

### Abstract

We report the case of a middle aged patient with biopsy proven squamous cell carcinoma of buccal mucosa who presented to us in Aga Khan University Hospital Karachi in April, 2017 and required reconstruction of buccal mucosa, upper lip and lower lip. As per protocol of our institute the lesion was excised by the head and neck surgeon and the defect was reconstructed by our team. The defect was large comprising of buccal mucosa including the left oral commissure, upper lip and the lower lip. It was reconstructed via a free flap and a radial forearm free flap. A specially designed radial forearm free flap was harvested and used for reconstruction which resulted in a good aesthetic and functional outcome.

**Keywords:** Radial-Forearm, Free-Flap, Subunits.

### Introduction

Since the first report of radial forearm free flap which was reported in 1982 by Song et al<sup>1</sup> it has been a mainstay of reconstructive surgery. In the era of advancement where every coming day is a dawn for a new and improved technique, radial forearm flap has maintained its place among one of the most harvested flap for reconstruction.

Radial forearm free flap has a thin pliable skin with good colour match<sup>2</sup> with face making it a preferable flap for head and neck reconstruction. The ability of the flap to incorporate radius with it making it an Osseo-cutaneous flap has rejuvenated its clinical applications. The donor site morbidity of the Osseo-cutaneous was acceptable with low rates of complications.<sup>3</sup>

Radial forearm free flap have been used extensively for lip reconstruction, Palmaris longus sling have been associated with the flap for achieving goals like oral continence, speech and mastication and excellent results have been achieved.<sup>4</sup> Radial forearm free flap is also considered by many as the gold standard for lip reconstruction.<sup>2</sup>

.....  
Aga Khan University Hospital, Karachi.

**Correspondence:** Muhammad Ubaid Khan.

Email: muhammad.ubaidkhan@hotmail.com

In cases where more than one subunit of face are involved like upper lip, lower lip, buccal mucosa or cheek, it is a challenge to address all the issues in a single stage while maintaining acceptable aesthetics in formation of oral commissure and achieving goals like oral continence and mouth opening.

We report the case of a male patient who was subjected to buccal re-construction after excision of the mucosa due to squamous cell carcinoma

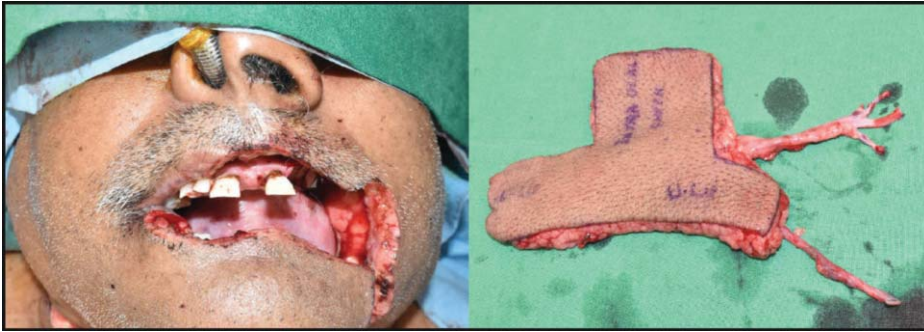
### Case Report

Our patient, a 57 years old male, presented to us in Aga Khan University Hospital Karachi in April, 2017. A known case of diabetes mellitus with a good glycaemic control, came with a lesion over the left buccal mucosa for the past three years which was gradually increasing in size. Patients from lower socio economic strata usually present to us very late from the onset of disease. The lesion was primarily involving the left buccal mucosa extending up to the lower buccal sulcus. Both the lips were keratotic with lower lip almost completely involved and about 40% of upper lip involvement along with the left oral commissure.

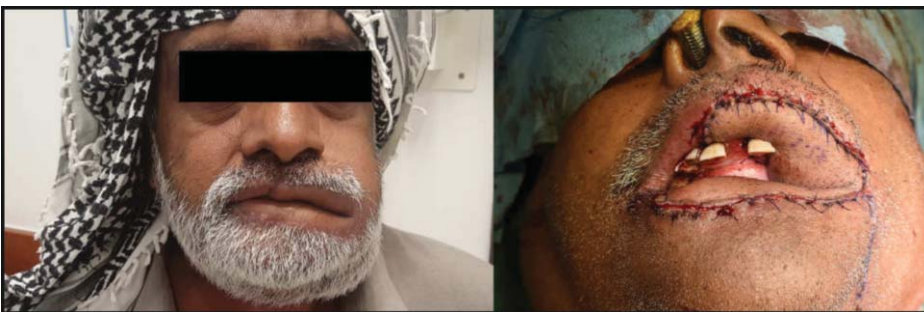Excisional biopsy was performed of the lesion over buccal mucosa which showed well differentiated squamous cell carcinoma. The cause of the lesion was suspected to be chronic irritation secondary to oral tobacco habits that the patient had for the past 20 years.

As per the protocol of our institute the lesion was excised by a Head and neck cancer surgeon with wide margins. Frozen sections were obtained for margin clearance confirmation. The defect that we were handed was enormous with buccal mucosa defect of about 5x5 cm, more than 50% of upper lip was resected and about 90% of the lower lip was excised along with left oral commissure (Figure-1).

To reconstruct this defect which had upper lip, lower lip and buccal mucosa was a difficult challenge but we designed a radial forearm free flap which would not only provide all the subunits but also give an acceptable aesthetic look to the patient also. We designed the skin paddle in such a way that a single strip would



**Figure-1:** The defect after tumor excision. Almost half of the upper lip, complete lower lip and full thickness cheek defect including skin and oral mucosa is visible. Radial forearm free flap after harvest. The pedicle with radial artery with its two venae comitantes is shown, also note that the cephalic vein is included in the flap to improve venous drainage of the flap.



**Figure-2:** Post op at 3 months and immediate post op. The flap design incorporated into the defect over upper lip, lower lip, oral mucosa and cheek skin. At 3 months the aesthetic appearance of the patient is satisfactory.

circumferentially from the upper lip and lower lip. The extension of skin from the part which would form the oral commissure almost perpendicular to the original strip, would form the buccal mucosa.

Radial Forearm Free Flap was harvested (Figure-1) with radial artery and its associated veins. Good pedicle length was obtained. Flap was inset as per the plan. Arterial anastomosis was done with the facial artery and two veins were anastomosed, one with the Internal jugular vein which was an end to side anastomosis and the other end to end anastomosis with a tributary of Internal jugular vein. Final inseting can be seen in Figure-2. Donor site was closed using a split thickness skin graft harvested from the thigh. Standard postoperative monitoring was done. Patient remained stable throughout the hospital course and was discharged on the sixth postoperative day.

On follow up patient showed good recovery with acceptable aesthetic appearance as seen in fig 2. The aesthetics were acceptable to the patient. The patient also showed acceptable oral continence and the speech was normal. Patient had good mouth opening and mastication was unhindered. This case elaborates the

importance of planning the skin paddle of the free flap customized to requirements of the defect and a single free flap can be customized to reconstruct more than one subunit in a single stage. Patient consented for publication of the case report.

## Discussion

The burden of HN cancer is 21% of the cancers among men and 11% among women across Pakistan.<sup>5</sup> Due to socioeconomic circumstances the presentation of Head and neck cancer is usually delayed and almost all (80%) the patients lose precious time (up to 3 years) between first presentation to clinician and final confirmation.<sup>6</sup> This delayed presentation causes advancement in local disease which in turn causes larger defect size which usually require reconstruction via a free flap. There are multiple options to choose from when deciding

about the flap that can be used for reconstruction. Radial forearm free flap is one of the oldest free flaps which was first described in 1982.<sup>1</sup> Since then this has been one of the most commonly used free flaps for head and neck reconstruction but the amount of skin available for is not unlimited but pre-operative planning is of paramount importance even if defect is large and comprises of multiple facial subunits. Numerous modifications in flap planning and design have been described in-order to achieve better cosmesis and reduce donor site morbidity. Concept of Narrow radial forearm flap and bipaddleradial forearm flap have been described which significantly reduces donor site morbidity by primary closure of wound.<sup>7,8</sup> Usually preferred for isolated subunit reconstruction like tongue, oral lining of cheek and floor of mouth, radial forearm flap has also been used as folded flap for full thickness cheek defects.<sup>9</sup> Because of its reliability and versatility it has been used for various reconstructions like Scalp, forehead and nose providing thin pliable tissue with reasonable colour match.<sup>10-12</sup> We have described a flap design resembling to shape of TETRIS (famous video game) and we believe that it can be used to cover three different subunits (upper and

lower lips and buccal mucosa).

### Conclusion

Radial forearm free flap can be tailored as per the need of the patient and tailored to defect using which reconstruction of multiple facial subunits can be done. Pre operative planning and special attention to aesthetic and functional appearance are essential for a better outcome. In our patient all subunits were reconstructed with the flap which gave an aesthetic appearance which was good and acceptable to the patient. Patient also had good oral continence and had an excellent mouth opening.

**Disclaimer:** None to declare.

**Conflict of Interest:** None to declare.

**Funding Disclosure:** None to declare.

### References

1. Song R, Gao Y, Song Y, Yu Y, Song Y. The forearm flap. *Clin Plast Surg* 1982;9:21-6.
2. Sasidaran R, Zain MA, Basiron NH. Lip and oral commissure reconstruction with the radial forearm flap. *Natl J Maxillofac Surg* 2012;3:21-4. doi: 10.4103/0975-5950.102144.
3. Satteson ES, Satteson AC, Waltonen JD, Li Z, Wiesler ER, Apel PJ, et al. Donor-site outcomes for the osteocutaneous radial forearm free flap. *J Reconstr Microsurg* 2017;33:544-548. doi: 10.1055/s-0037-1602740.
4. Jeng SF, Kuo YR, Wei FC, Su CY, Chien CY. Total lower lip reconstruction with a composite radial forearm-palmaris longus tendon flap: a clinical series. *Plast Reconstr Surg* 2004;113:19-23. doi: 10.1097/01.PRS.0000090722.16689.9A
5. Joshi P, Dutta S, Chaturvedi P, Nair S. Head and neck cancers in developing countries. *Rambam Maimonides Med J* 2014;5:e0009. doi: 10.5041/RMMJ.10143.
6. Bhurgri Y, Bhurgri A, Usman A, Pervez S, Kayani N, Bashir I, et al. Epidemiological review of head and neck cancers in Karachi. *Asian Pac J Cancer Prev* 2006;7:195-200.
7. Shaikh SA, Bawa A, Shahzad N, Yousufzai Z, Ghani MS. Reducing the donor site morbidity in radial forearm free flaps by utilizing a narrow radial forearm free flap. *Arch Plast Surg* 2018;45:345-350. doi: 10.5999/aps.2018.00115.
8. Zhang YX, Xi W, Lazzeri D, Zhou X, Li Z, Nicoli F, et al. Bipaddle radial forearm flap for head and neck reconstruction. *J Craniofac Surg* 2015;26:350-3. doi: 10.1097/SCS.0000000000001468.
9. Liu F, Wang L, Pang S, Kan Q. Reconstruction of full-thickness buccal defects with folded radial forearm flaps: a retrospective clinical study. *Medicine (Baltimore)* 2017;96:e7344. doi: 10.1097/MD.0000000000007344.
10. Fang QG, Li ZN, Zhang X, Liu FY, Xu ZF, Sun CF. Clinical reliability of radial forearm free flap in repair of buccal defects. *World J Surg Oncol* 2013;11:26. doi: 10.1186/1477-7819-11-26.
11. Kruse AL, Bredell MG, Lübbers HT, Jacobsen C, Grätz KW, Obwegeser JA. Clinical reliability of radial forearm free-flap procedure in reconstructive head and neck surgery. *J Craniofac Surg* 2011;22:822-5. doi: 10.1097/SCS.0b013e31820f36aa.
12. Santamaria E, Granados M, Barrera-Franco JL. Radial forearm free tissue transfer for head and neck reconstruction: versatility and reliability of a single donor site. *Microsurgery* 2000;20:195-201.