



THE AGA KHAN UNIVERSITY

eCommons@AKU

Department of Surgery

Department of Surgery

12-1-1993

Endoscopic correction of vesicoureteric reflux in children

K Rasheed
Aga Khan University

Follow this and additional works at: https://ecommons.aku.edu/pakistan_fhs_mc_surg_surg

Recommended Citation

Rasheed, K. (1993). Endoscopic correction of vesicoureteric reflux in children. *Journal of Pakistan Medical Association*, 43(12), 255-257.

Available at: https://ecommons.aku.edu/pakistan_fhs_mc_surg_surg/704

Endoscopic Correction of Vesicoureteric Reflux in Children

Pages with reference to book, From 255 To 257

Khalid Rasheed (Department of Surgery, The Aga Khan University Hospital, Karachi.)

Abstract

Vesicoureteric reflux (VUR) Is a common cause of recurrent urinary tract infections in children. Mild reflux (grade I-II) Is usually managed conservatively with antibiotics but severe degree of reflux (grades III, IV, V) requires surgical intervention. We present our initial experience with endoscopic correction of vesicoureteric reflux by sub-ureteric teflon injection (STING) In ten patients. Results are available for 15 ureters with a success rate of 86.6%. There was no change in the grade of VUR in two ureters. There were no complications. Endoscopic correction of vesico-ureteric reflux by sub-ureteric teflon injection is effective and simple with no pain to the child. It averts the need for open operations (JPMA 43:255, 1993).

Introduction

Urinary tract infection (UTI) is a common problem in children and one third to half the cases are due to vesicoureteric reflux. Vesicoureteric reflux in an undilated system is likely to disappear over the years and is managed by continuous low dose chemoprophylaxis until disappearance is documented. Severe vesicoureteric reflux is unlikely to disappear and generally require surgical intervention. Several open anti-reflux reimplantation operations are performed with good results. Now in the era of minimal invasiveness, endoscopic correction of vesicoureteric reflux with subureteric teflon injection (STING) is replacing open surgical procedures in many centres. This study reports our initial experience with this technique.

Patients and Methods

STING (sub-ureteric teflon injection) was performed under general anaesthesia at cystoscopy after identifying the refluxing ureteric orifice in 10 children. Pun's catheter (Storz), 4F or 5F with 21G needle at the end, introduced through a 11F cystoscope, was placed in the submucosa below the affected ureteric orifice. Teflon paste, taken in 1 ml syringe with a metal sheath and piston (Storz) was injected. It forms a nipple on top of which the ureteric orifice appears as a crescent. During voiding the ureteric orifice maintains its compliance and stops refluxing². Vesicoureteric reflux was graded according to the international classification of reflux (Figure 1):

VESICO-URETERIC REFLUX

International

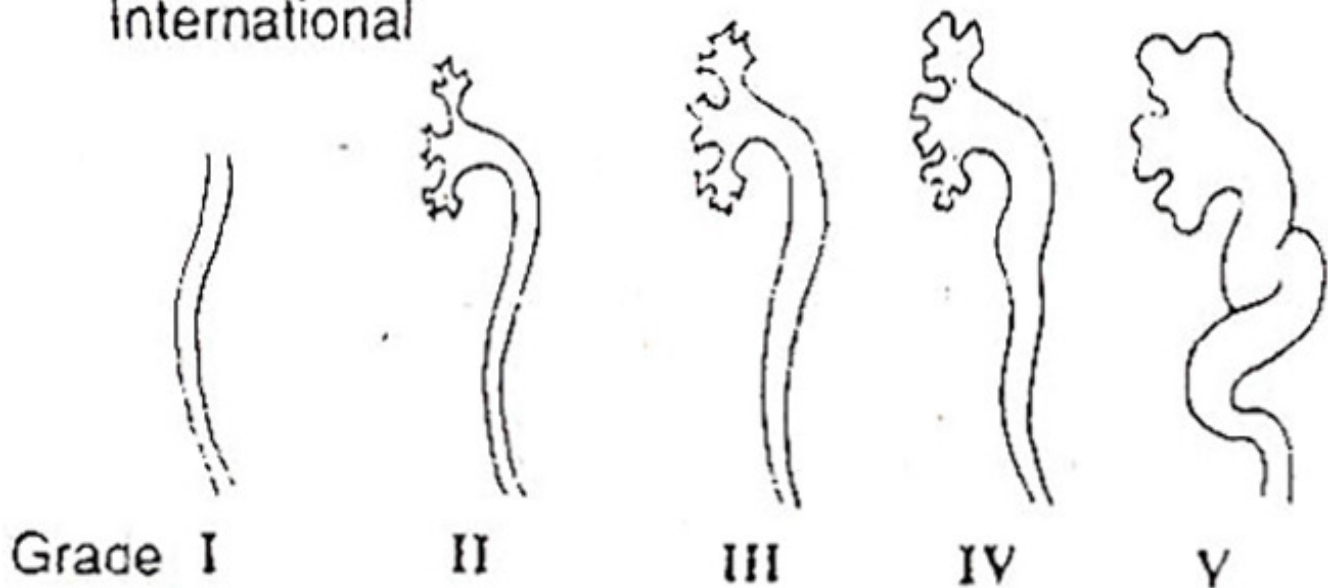


Figure 1. International classification of VUR.

grade I ureter only; grade II ureter, pelvis and calices, no dilatation, normal caliceal fornices; grade III mild or moderate dilatation or tortuosity of ureter and mild or moderate dilatations of renal pelvis but slight or no blunting of fornices; grade IV moderate dilatation or tortuosity of ureter and moderate dilatation of renal pelvis and calices, complete obliteration of sharp angle of fornices but maintenance of papillary impressions in most calices; grade V gross dilatation and tortuosity of ureter, gross dilatation of renal pelvis and calices and papillary impressions no longer visible in most calices⁵. All patients were admitted on the day of the procedure, some were discharged on the same day and a few stayed over night in the hospital. All patients were kept on prophylactic dose of antibiotic. Follow-up included monthly urine cultures, ultrasound examinations and a voiding cystourethrogram 3 months after the STING procedure. Post-sting ultrasound examinations were performed to rule out any increasing hydronephrosis due to obstruction at the ureteric orifice.

Results

During the last one year 10 patients had STING for vesicoureteric reflux. There were 4 males and 6 females. Mean age was 4.1 years (range 3 to 10 years).

Table I. Grades of VUR in 10 patients (18 ureters).

	Grades					Total
	I	II	III	IV	V	
No. of ureters	0	3	7	5	3	18

Table I shows the arading of vesicoureteric reflux. Seven patients (6 females, 1 male) had primary reflux while three had secondary vcotoureteric reflux (2 secondary to posterior urethral valves, 1

secondary to re-implantation). Eight patients had bilateral VUR and two had unilateral reflux so there were a total of 18 refluxing ureters. Two patients with bilateral and another with unilateral vesicoureteric reflux are awaiting their post-STING voiding cystourethrogram, so results are available on fifteen ureters (Table II).

Table II. Results of STING for VUR (15 ureters).

	No. of ureters
Reflux stopped	6
Improvement of reflux to:	
Grade I	5
Grade II	2
No change in reflux	2

Reflux of urine stopped in 6 ureters after STING (Figure 2 a, b),

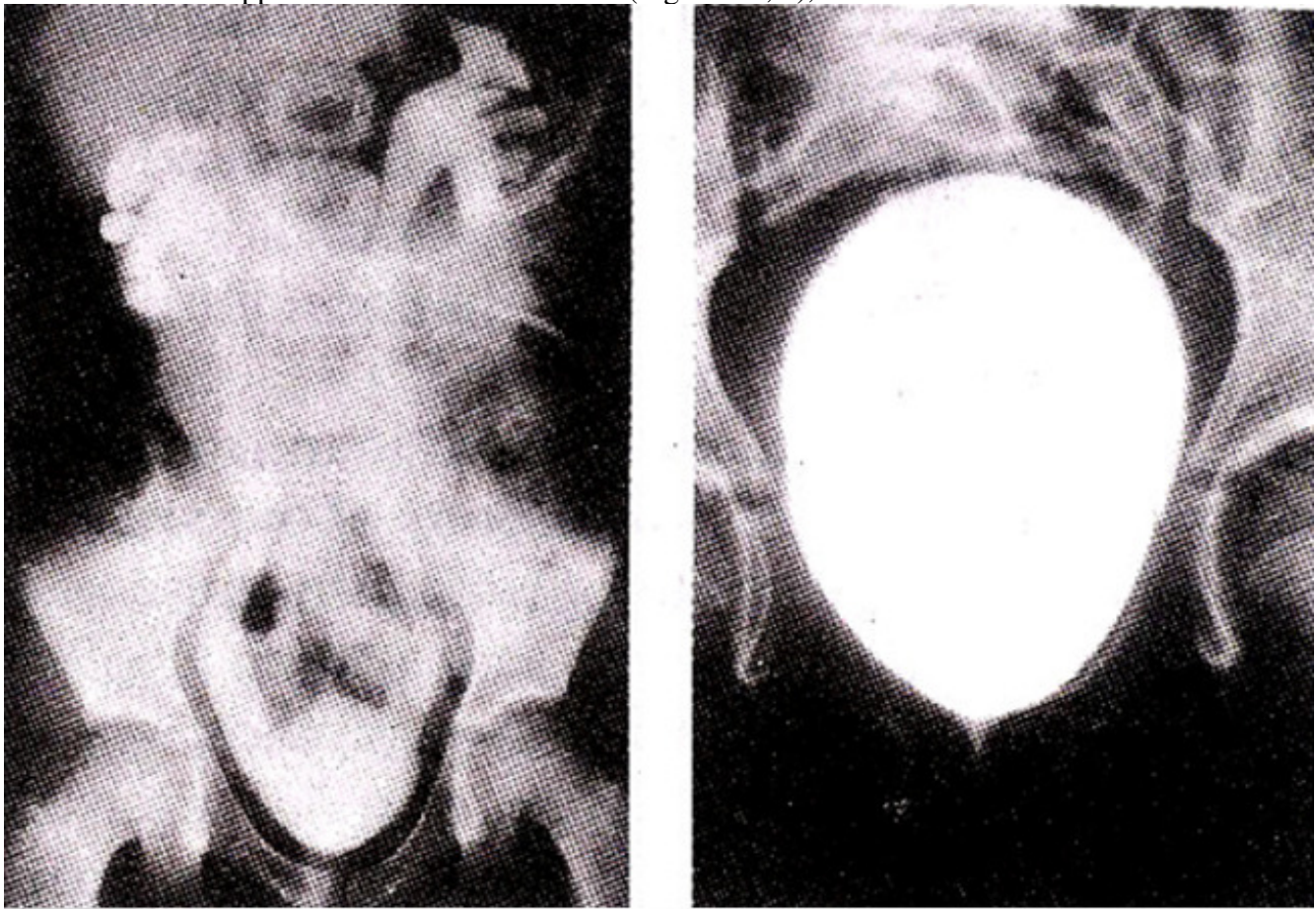


Figure 2 (a, b). (a) VCUG showing grade IV reflux (b) and resolution of reflux after STING.

confirmed by YCUG. There was improvement of reflux to grade I in five and grade II in two ureters. These 7 ureters with improved grades of VUR are unlikely to require any further surgery. There has been a success rate of 86.6%. There were no immediate post-operative complications. In the short follow up of 6 to 9 months there has been no incidence of obstruction. Patients with no change in reflux will require another STING.

Discussion

Lower grades of VUR are managed with conservative antibiotics treatment but higher grade usually require surgery. Open operations with reimplantation of ureters using different techniques are available. These require prolonged hospital stays and a lot of post-operative pain to the patients. Endoscopic correction of vesicoureteric reflux with STING is an alternative way to manage the problem with less pain and scars to the child. Indications for STING remains the same as those for open operations for reimplantation of ureters. Teflon paste is a suspension of biologically inert polytetrafluorethylene particles in glycerin. Glycerin is absorbed after the injection and teflon implant achieves firm consistency and retains its shape, encapsulated by thin fibrous tissue². Teflon is being used in the medical field for a long time for augmentation of the vocal cords, hip implants and periurethral tissue. There is no evidence to date to suggest that use of teflon is associated with any morbidity in humans and no clinical complications suggestive of distant migration have been reported^{6,7}. The main mechanism of incompetent vesicoureteric orifice is believed to be presence of short intramural tunnel and absence of adequate support for the intravesical ureter⁸. In a normal ureter, intramural portion has longitudinal muscle fibres only. These fibres continue downwards beyond the ureteric orifice into the trigone, fanning out and giving a firm attachment⁹. Congenital deficiency or absence of the longitudinal muscle of the intramural ureter, as found in primary reflux, results in upward or lateral displacement of the orifice, thereby reducing the length and obliquity of the intramural ureter. Subureteric teflon implant produce a solid support behind the intravesical ureter and provides a firm anchorage, thus preventing it from sliding upwards or laterally during voiding and stops the reflux. STING stops the reflux or improves the grade of reflux and can be performed more than once to completely cure the reflux. In two ureters of our series there was no change in the grade of reflux. In these patients procedure can be repeated⁷. The presence of teflon implant does not affect the reimplantation surgery if required¹⁰. Very few recurrences of reflux after STING procedure have been reported in the long term followup^{7,10}. We intend to follow our patients with ultrasound examinations and DTPA/DMSA renal isotope scans. We have presented our initial results with short follow-up. The technique requires precision. Endoscopic correction of vesicoureteric reflux by STING is simple and effective. It is well tolerated, prevents open operation, can be performed as day surgery and can be offered to all children with vesicoureteric reflux.

References

1. Hodaon, C.J. and Cotran, R.S. tteflux nepbropathy. *Hosp. Pract.*, 1982;17:133-56.
2. Purl, P. and O'Donnell, B. Correction of experimentally produced vealcoureteric reflux in the piglet by intravesical injection of teflon. *Br.Med.J.*, 1984;289:5-7.
3. O'Donnell, B. and Purl, P. Treatment of veaicoureteric reflux by endoacopic injeccion of teflon. *Br.Med.J.*, 1984;289:7-9.
4. Report of the International Reflux Study Committee. Medial verausaurgical treatment of primary veaicoureteral reflux. *Paediatrics*, 1961;67:392-400.
5. Dewan, P. Ia injected polytetrafluoroetheylene (polytef) carcinogenic? *Br.J.Urol.*, 1992;69:29-33.

6. Puri, P. Endoscopic correction of primary vesicoureteric reflux by ureteric teflon injection (S'TING): followup study in 123 patients. *Paediatr. Sur& Int.*, 1991;6:269-72.
7. Stephens, F.D. and Lenaghan, D. The anatomical basis and dynamics of vesicoureteral reflux. *J.Urol.*, 1962;87:669-80.
8. Lyon, R.P., Marshall, & Tanagho, R.H. The ureteral orifice: its configuration and competency. *J.Urol.*, 1969;102:504-9.
10. Frey, P. and Whitalcar, R.H. Prevention of vesicoureteric reflux by endoscopic injection. *Br.J.Urol.*, 1992;69:1-6.