



THE AGA KHAN UNIVERSITY

eCommons@AKU

Department of Surgery

Department of Surgery

February 2000

Diagnosis and management of the neonatal cloaca

A Samad

S Hussain

Aga Khan University, shabbir.hussain@aku.edu

M Arshad

Aga Khan University, arshad.muhammad@aku.edu

F Moazam

Aga Khan University, farhat.moazam@aku.edu

Follow this and additional works at: https://ecommons.aku.edu/pakistan_fhs_mc_surg_surg



Part of the [Surgery Commons](#)

Recommended Citation

Samad, A., Hussain, S., Arshad, M., Moazam, F. (2000). Diagnosis and management of the neonatal cloaca. *Journal of Pakistan Medical Association*, 50(2), 71-73.

Available at: https://ecommons.aku.edu/pakistan_fhs_mc_surg_surg/700

Diagnosis and Management of the Neonatal Cloaca

Abdul Samad, Shabbir Hussain, Muhammad Arshad, Farhat Moazam (Department of Surgery, The Aga Khan University Hospital, Karachi.)

Introduction

The cloaca is one of the most complex and challenging developmental malformations managed by paediatric surgeons. The word Cloaca is latin in origin and means Sewer. It is classically defined as a common chamber into which the urinary, genital and intestinal tracts terminate before draining to the exterior through a common opening¹. Normally, this is a transient embryological event at about 7-8 mm stage of the human embryo but may persist as a rare congenital anomaly^{2,3}. Its incidence is reported to be one in 50,000 births annually⁴. Although the incidence of true persistent cloaca is much more rare, the cloaca includes a wide range of anomalies from the almost insignificant to the very complex. This paper describes two neonates with cloacal anomalies recently managed at the Aga Khan University Hospital (AKUH), Karachi.

Case Report

Case One

A female neonate was born at 36 weeks of gestation to a 22 years old nulliparous woman. Although the earlier antenatal ultrasounds were reported to be normal, one done at 29th gestational week revealed an irregular mass in the fetal abdomen measuring about 3.1 x 2.2 cm together with bilateral hydronephrosis and oligohydramnios. Subsequent ultrasounds showed rapid increase in the size of the mass. The neonate required incubation and ventilatory support due to the respiratory distress at birth. Clinical examination revealed 3 palpable abdominal masses and a single orifice (Figure 1)

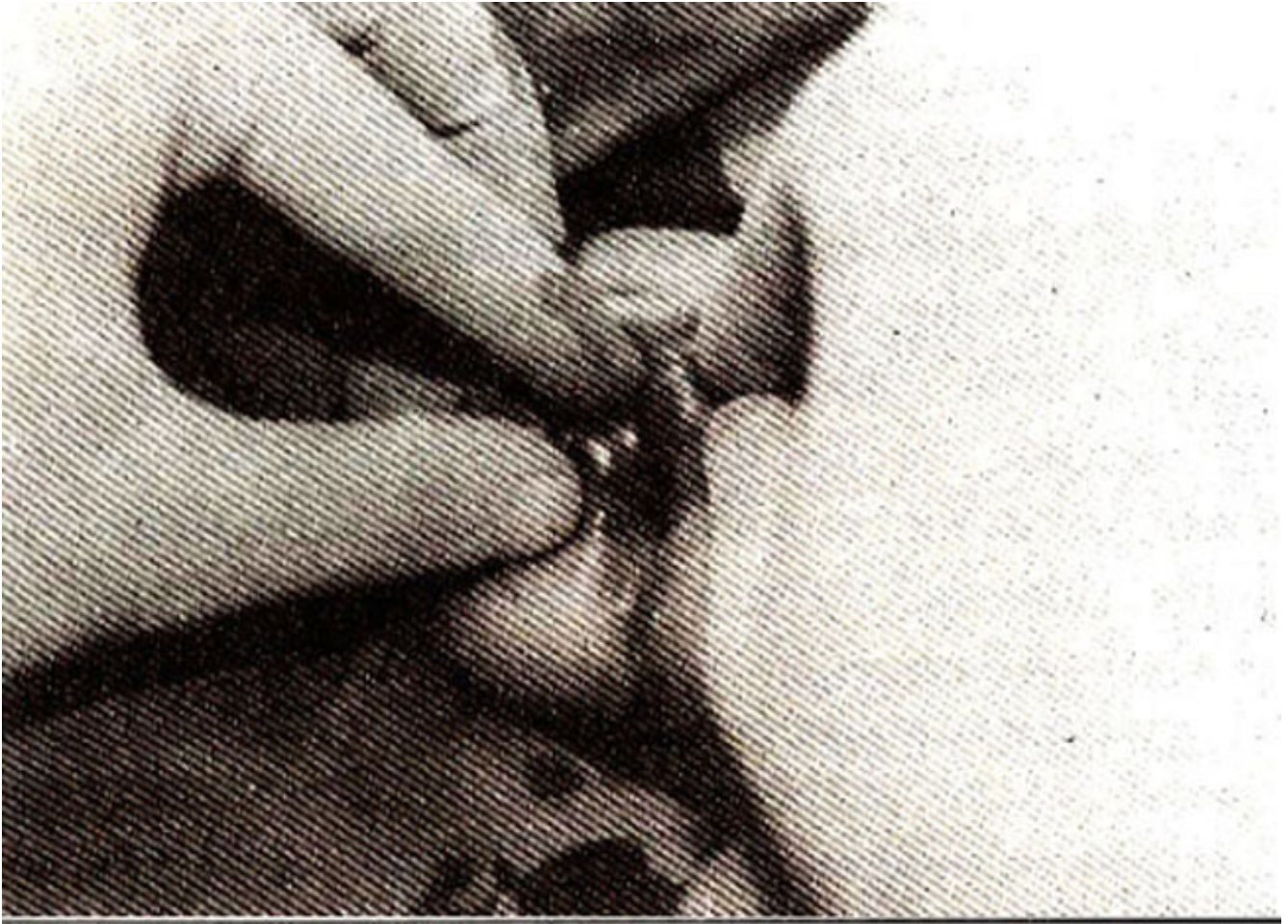


Figure 1 Single orifice in the depth of the labia majora.

in the depth of the labia majora. Catheterization of the orifice drained urine with some mucoid debris. The child did not pass meconium. Congenital dislocation of the left hip was also noted. A provisional diagnosis of cloaca was made. An ultrasound as well as sinograms (Figure 2)

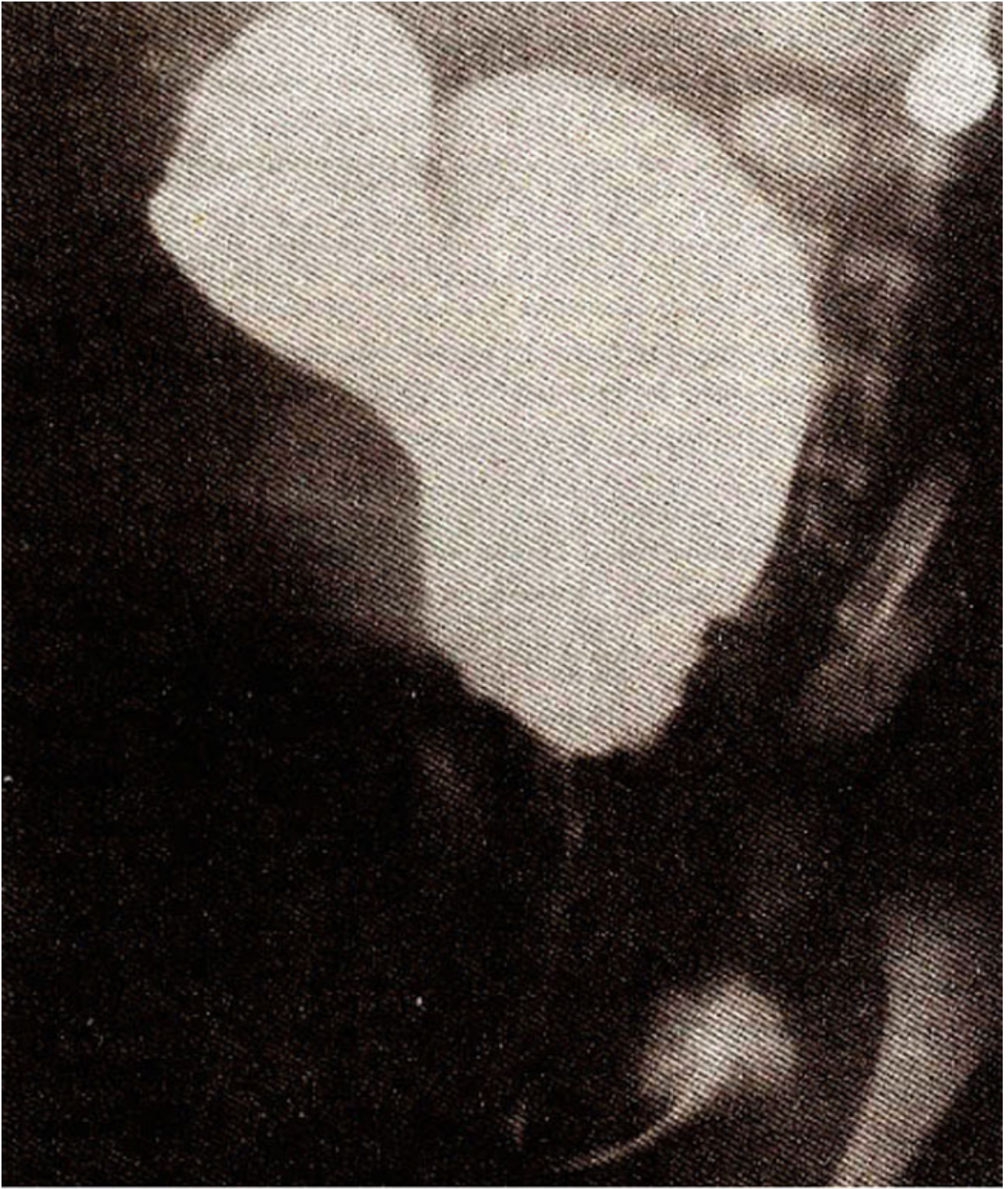

Figure 2. Sinogram

were not helpful in defining the internal anatomy clearly.

The neonate's serum creatinine increased from 0.8 to 1.5 mg/dl over the first 3 days of life. Endoscopy revealed a common channel leading to two chambers, anteriorly the urinary bladder and posteriorly to a vagina with haemorrhagic mucosa. A subsequent exploratory laparotomy revealed a bicornuate uterus

and a short colon with a dilated pouch, both communicating with the urinary bladder, confirming a case of classical cloaca. Two appendices at the base of the caecum were also found. A divided ileosomy and a tube vesicostomy were performed to decompress the gastrointestinal and genitourinary systems. The patient improved and the ventilatory support was gradually discontinued. The serum creatinine had gradually dropped to 0.5 at the time of discharge from the hospital. During follow-up, the patient was passing urine and mucus from the cloacal opening with very little residual urine in the urinary bladder. The Foley's catheter in the vesicostomy was removed and the vesicosomy closed spontaneously. The mother was instructed in clean intermittent catheterization to ensure complete decompression of the urinary bladder. Future plans for this infant include the contrast studies through stoma to determine the status of her anatomical structures followed by definitive reconstruction.

Case Two

A female neonate was born at about 35 weeks of gestation with no abnormality detected on two antenatal ultrasounds in early pregnancy. However, the ultrasound done a few days prior to birth, showed oligohydramnios, a markedly distended fetal urinary bladder, moderate bilateral hydronephrosis and a breech presentation. The neonate required ventilatory support due to respiratory distress at birth. Clinical examination revealed a complex pelvic mass and a blind clitoris with a single urogenital opening. Meconium was adequately passed via an anteriorly placed ectopic anus. Polydactyly of left hand was also found. A sinogram done on the third day of life showed a massively distended vagina with the urinary bladder pushed anteriorly. An echocardiogram showed ventricular septal defect. On endoscopy, a long common urogenital sinus with an anteriorly placed urinary bladder was also noted. An exploratory laparotomy performed on the same day revealed a uterus pushed up by an enormously distended vagina. A tube vaginostomy was done to decompress the system. Ventilatory support was gradually weaned off and the patient was discharged on the 6th post-operative day. Future plans for this infant include contrast studies through stoma for further demarcation of various anatomical structures followed by elective, definitive reconstruction.

Discussion

The basic embryological defect that results in a cloacal anomaly is failure of the complete descent of uro-rectal septum⁵. The uro-rectal septum, which appears in a 4 weeks embryo and fuses with the cloacal membrane in the 7th week, divides the cloaca into dorsal hindgut and ventral urogenital sinus⁶. The urogenital sinus gets further subdivided into cranial urethro-vesicle canal and caudal definitive urogenital sinus at the point of entry of mesonephric duct⁷. If there is testicular differentiation, there is associated müllerian duct regression and the primitive urogenital sinus, caudal to the Wolffian duct forming prostatic, membranous urethra and the penis. In case of differentiation into the female sex, the müllerian duct along with definitive urogenital sinus form fallopian tubes, uterus and vagina. The cloacal anomalies have a wide spectrum ranging from almost insignificant like ectopic anus to the very bizarre. Attempts to classify the cloacal anomalies have been unsuccessful and currently there is no universally accepted classification system^{8,9}, due to enormous variations. External examination does not accurately predict internal anatomy. A battery of investigations is required to evaluate internal anatomy. Despite this significant number of anomalies can only be accurately evaluated through surgical exploration¹.

Approximately 60% of cloacal anomalies are associated with upper urinary tract malformations and hydrocolpas caused by partial or complete obstruction of the vaginal outlet. Frequently hydrocolpas contributes to bladder outlet and/or ureteral obstruction, urinary stasis and sepsis. Both our cases presented antenatally with hydrocolpas, due to vaginal obstruction and associated upper urinary tract dilatation with deteriorating renal function. Case one presented with classical cloacal anomaly while case two had urogenital sinus associated with ectopic anus.

The basic aim of neonatal exploration is decompression of stagnant system and the proper evaluation of cloacal anatomy. Gastro-intestinal system is decompressed by enterostomy¹². Right transverse colostomy with preservation of mid-colic, left colic and sigmoid arteries is preferred, as distal colon may be required for later vaginal reconstruction¹³. In case one, we did divided ileostomy because of extremely short colon. Hydronephrosis and urinary bladder distension are the main indications for urinary bladder decompression. In both our patients, the urogenital tract required decompression by stoma. Allen and Husmann reported upto 60% of patients with cloacal anomalies required vesicostomy¹. Many may have varying degrees of neurogenic dysfunction of bladder while vesico-ureteric reflux is reported in over 60%.

Definitive cloacal reconstruction involves surgical separation of the three systems and bringing them to the perineum with construction of three continent openings. The decision for the timing of reconstructive surgery depends on the condition of infant, complexity of malformation and experience of the surgeon. Although the neonatal reconstruction is possible¹⁴, it is best deferred beyond the first month of the life¹².

References

1. Allen TD, Husmann DA. Cloacal anomalies and other urorectal septal defects in female patients: A spectrum of anatomical abnormalities. *J. Urol.*, 1991;145: 034-39.
2. Gray SW, Skandakalis IF. The colon and rectum: Embryology for surgeons. Philadelphia. WB Saunders Co., 1982. p. 187.
3. Pohnnan AG. The development of the cloaca in human embryos. *Am. J. Anat.*, 1911;12-1.
4. Alexander F, Kay R. Technical considerations in the repair of cloacal vaginal deformities. *J. urol.*, 1995;153:788-91.
5. Escobar LF, Weaver DD, Diller D, et al. Urorectal septum malformation sequence: report of six cases and embryological analysis. *Am. J. Dis. Child.*, 1987;141:102-1.
6. Stephens ED. Embryology of the cloaca and embryogenesis of anorectal malformations. *Birth Defects*, 1988;24:1-77.
7. Marshall FE. Embryology of genitourinary tract. *J. Urol. Clin. North. Am.*, 1978;5:3-15.
8. Sanaatulli TV, Kiesewelter WB, Bill All. Anorectal anomalies: A suggested international classification. *J. Pediatr. Surg.*, 1970;5:28-1.
9. Smith ED. Anorectal malformations Classifications. *Birth Defects*, 1988;24:21-1.
10. Ueno S, Yokoyama S, Soeda J. Three dimensional display of the pelvic structure of anorectal malformations based on CT and MR images. *J. Pediatr. Surg.*, 1995;30:682-86.
11. Hendren WH. Urological aspects of cloacal anomalies. *J. Urol* 1988;140:1207-13.
12. Hendren WH. Repair of cloacal anomalies: Current techniques. *J. Pediatr. Surg.*, 1986;21:1159-76.
13. Hendren WH. Cloacal anomalies: Abdominal Surgery of Infancy and Childhood. 1996;26: 1-12.
14. Raffensperger JG, Rauschenbysky ML. The management of a cloaca. *J. Pediatr. Surg.*, 1973;8:647-57.