



THE AGA KHAN UNIVERSITY

eCommons@AKU

Department of Surgery

Department of Surgery

April 2017

Giant haemangioma of nasopharynx: a rare case outcome.

Haissan Iftikhar

Aga Khan University, haissan.iftikhar@aku.edu

Moghira Siddiqui

Aga Khan University, moghira.siddiqui@aku.edu

Follow this and additional works at: http://ecommons.aku.edu/pakistan_fhs_mc_surg_surg



Part of the [Surgery Commons](#)

Recommended Citation

Iftikhar, H., Siddiqui, M. (2017). Giant haemangioma of nasopharynx: a rare case outcome.. *J Ayub Med Coll Abbottabad*, 29(2), 358-359.

Available at: http://ecommons.aku.edu/pakistan_fhs_mc_surg_surg/648

CASE REPORT

GIANT HAEMANGIOMA OF NASOPHARYNX: A RARE CASE
OUTCOME

Haissan Iftikhar, Moghira Iqbaluddin Siddiqui

Department of Otolaryngology / Head and neck surgery, Aga Khan University, Karachi-Pakistan

A 60-year-old female presented to us with a 5-year history of progressive right sided nasal obstruction and recurrent epistaxis. On examination lesion was seen in the right nostril which was firm and bled on probing. CT-scan paranasal sinuses showed a right sided lesion of nose and naso-pharynx obstructing posterior nasal choanae. Dimensions were reported to be 9×4.1×3.8 cm. A punch biopsy was taken in operating room under general anaesthesia which resulted in profuse bleeding. Suction cautery was used to control bleeding and the nose was packed. The mass was firm to hard and provided resistance during the time of biopsy. On second post-operative day, the mass visibly changed its colour and became blackish in appearance. Patient had an episode of cough in the evening and expelled out the entire mass orally.

Keywords: Hemangioma; Head and neck; Otolaryngology

J Ayub Med Coll Abbottabad 2017;29(2):358-9

INTRODUCTION

Although the hemangiomas can arise anywhere in the head and neck region from the skin to deeper structures such as muscles and bone, hemangiomas arising in the nose are rare. 80% arise from the Kiesselbach's plexus and 15% from the lateral wall of the nasal cavity.¹ Nasal bleeding with obstruction can be associated with benign and malignant lesions. The exact origin of haemangiomas is still debatable. Some have proposed embryonic unipotent cells to be involved while others advocate vascular elongation.² Infantile haemangiomas however ultimately represent endothelial cell proliferation.³

Haemangiomas are classified on the basis of the vessels they contain: Infantile haemangioma (HOI), (cavernous, capillary) or mixed.⁴ Capillary haemangioma are common and are seen in childhood which spontaneously regress and do not need any intervention unless they are symptomatic.² However infantile hemangioma (HOI) is usually seen in adulthood and warrants an intervention if symptomatic.^{3,5,6} In our case the differentials were nasopharyngeal carcinoma, inverted papilloma and HOI.

CASE REPORT

A 60-year-old female presented to our outpatient clinic with a 5-year history of progressive right sided nasal obstruction and epistaxis which was recurrent and profuse. On nasal examination, the lesion was seen in the right nostril which was firm and bled on probing, oral examination showed bulge in soft palate and a mass in nasopharynx. Blood counts were done which revealed no haematological disturbance and normal haemoglobin. CT-scan head and neck with intravenous contrast was done which revealed a lesion occupying the right side of nose, nasopharynx and extending up to the oropharynx (Figure-1) with the dimensions of 9×4.1×3.8 cm. Patient was electively taken for examination under anaesthesia and biopsy. A punch

biopsy was taken in operating room under general anaesthesia which resulted in profuse bleeding. Suction cautery was used to control bleeding and the nose was packed. The mass was firm to hard and provided resistance during the time of biopsy. On post-operative day 2 patients had an episode of cough which led to expelling a large lesion out of her mouth (Figure-2). Biopsy was consistent with haemangioma of infancy. The patient was then symptom free and was subsequently discharged the next day.

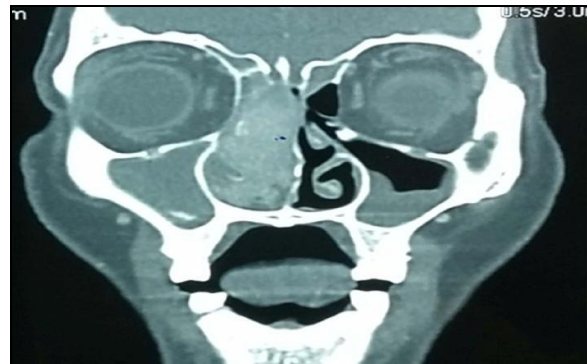


Figure-1: CT-Scan (Coronal cut) showing a large soft tissue enhancing mass that is completely occluding the right nasal passage

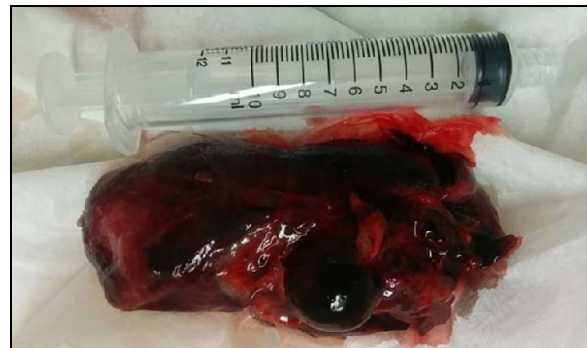

Figure-2: Mass as seen at the time of expulsion.

DISCUSSION

Haemangioma of infancy are slow growing lesion and when symptomatic cause epistaxis, nasal obstruction and at times haemoptysis.^{7,8} The first two symptoms are consistent with our patient. The types of haemangioma vary histologically but have no clinical significance of their histological variation.⁹ Mean age of presentation of HOI (previously named cavernous haemangioma) is in 40s whereas the sex predilection appears to be equal.⁷ The underlying bone is otherwise normal but might be re-modelled due to pressure effect.^{8,10} MRI images show low intensity signal on T1-weighted images and very high intensity signals on T2-weighted images. Angiography is another modality that not only offers a correct diagnosis but can also aid in embolization of the feeding vessels which can prevent excessive bleeding during surgical excision.

The main stay of treatment for haemangioma of Sino nasal and anterior skull base remains surgery which might include arterio-embolization preoperatively. Angioembolization minimizes blood loss intra-operatively.¹¹ In our case angioembolization was not considered as we planned a biopsy initially. The first successful case of endoscopic removal of Sino nasal infantile haemangioma was in 2003.¹² There is now growing evidence and positive outcomes for treatment of Sino nasal tumours: benign and malignant lesions endoscopically.^{13,14}

What makes our case special is its size and auto-expulsion post biopsy. In an attempt to control bleeding intra-operatively we probably were able to cauterize the main blood supply of the mass which resulted in necrosis and the tumour dropped down into the oropharynx to the best of our knowledge we report the first ever case of such expulsion of sino nasal haemangioma post-operatively.

AUTHORS' CONTRIBUTION

HI had substantial contributions to the conception, design of the work and the acquisition, analysis, and

interpretation of data for the work. MIS had critically revised the manuscript for important intellectual content and final approval of the version to be published.

REFERENCES

1. Su K, Zhang W, Shi H, Yin S. Pedunculated cavernous hemangioma originating in the olfactory cleft. *Ear Nose Throat J* 2014;93(9):E29-33.
2. Kovalerchik O, Husain Q, Mirani NM, Liu JK, Eloy JA. Endoscopic nonembolized resection of an extensive sinonasal cavernous hemangioma: A case report and literature review. *Allergy Rhinol (Providence)* 2013;4(3):e179-83.
3. Mulliken JB, Glowacki J. Hemangiomas and vascular malformations in infants and children: a classification based on endothelial characteristics. *Plast Reconstr Surg* 1982;69(3):412-22.
4. Shpitzer T, Noyek AM, Witterick I, Kassel T, Ichise M, Gullane P, *et al.* Noncutaneous cavernous hemangiomas of the head and neck. *Am J Otolaryngol* 1997;18(6):367-74.
5. Caylakli F, Cagici AC, Hurcan C, Bal N, Kizilkilic O, Kiroglu F. Cavernous hemangioma of the middle turbinate: a case report. *Ear Nose Throat J* 2008;87(7):391-3.
6. Webb CJ, Porter G, Spencer MG, Sissons GRJ. Cavernous haemangioma of the nasal bones: an alternative management option. *J Laryngol Otol* 2000;114(4):287-9.
7. Iwata N, Hattori K, Nakagawa T, Tsujimura T. Hemangioma of the nasal cavity: a clinicopathologic study. *Auris Nasus Larynx* 2002;29(4):335-9.
8. Dillon WP, Som PM, Rosenau W. Hemangioma of the nasal vault: MR and CT features. *Radiology* 1991;180(3):761-5.
9. Batsakis JG, Rice DH. The pathology of head and neck tumors: vasoformative tumors, part 9A. *Head Neck Surg* 1981;3(3):231-9.
10. Itoh K, Nishimura K, Togashi K, Fujisawa I, Nakano Y, Itoh H, *et al.* MR imaging of cavernous hemangioma of the face and neck. *J Comput Assist Tomogr* 1986;10(5):831-5.
11. Biller HF, Krespi YP, Som PM. Combined therapy for vascular lesions of the head and neck with intra-arterial embolization and surgical excision. *Otolaryngol Head Neck Surg* 1981;90(1):37-47.
12. Kelley TF. Endoscopic management of an intranasal hemangioma: A case report and literature review. *Otolaryngol Head Neck Surg* 2003;128(4):595-7.
13. Jungheim M, Chilla R. The monthly interesting case--case no. 64. Cavernous hemangioma. *Laryngorhinootologie* 2004;83(10):665-8.
14. Eloy JA, Vivero RJ, Hoang K, Civantos FJ, Weed DT, Morcos JJ, *et al.* Comparison of transnasal endoscopic and open craniofacial resection for malignant tumors of the anterior skull base. *Laryngoscope* 2009;119(5):834-40.

Received: 4 January, 2017

Revised: --

Accepted: 12 February, 2017

Address for Correspondence:

Dr. Moghira Iqbaluddin Siddiqui, Department of Surgery, Section of Otolaryngology, Aga Khan University Hospital, Karachi-Pakistan

Cell: +92 306 2463146

Email: moghira.siddiqui@aku.edu