



3-2023

Application of Multiphase Ct Angiography in Acute Ischemic Stroke

Salman Mansoor

Lister Hospital, East and North Hertfordshire NHS trust, United Kingdom

Follow this and additional works at: <https://ecommons.aku.edu/pjns>

 Part of the [Neurology Commons](#)

Recommended Citation

Mansoor, Salman (2023) "Application of Multiphase Ct Angiography in Acute Ischemic Stroke," *Pakistan Journal of Neurological Sciences (PJNS)*: Vol. 18: Iss. 1, Article 2.

Available at: <https://ecommons.aku.edu/pjns/vol18/iss1/2>



APPLICATION OF MULTIPHASE CT ANGIOGRAPHY IN ACUTE ISCHEMIC STROKE

Salman Mansoor¹

¹.Consultant Stroke Medicine and Neurology, Lister Hospital, East and North Hertfordshire NHS trust, United Kingdom

Correspondence Author: Salman Mansoor Consultant Stroke Medicine and Neurology, Lister Hospital, East and North Hertfordshire NHS trust, United Kingdom **Email:** Salmanmansoor.dr@gmail.com

Date of submission: March 1, 2023 **Date of revision:** March 25, 2023 **Date of acceptance:** March 25, 2023

ABSTRACT

This article explores the use of multiphase CT angiography (CTA) as a valuable tool in acute stroke management. Unlike traditional imaging methods, multiphase CTA provides a more comprehensive view of the neurovascular system and can detect occlusions and aid in treatment decision-making. Recent studies have shown that multiphase CTA has high accuracy in identifying patients who are suitable for endovascular treatment. Furthermore, it has also been used to visualize intracranial aneurysms and track the development of collateral circulation during and after treatment. Despite concerns regarding radiation exposure and image interpretation, multiphase CTA remains an essential imaging modality in the management of acute stroke patients.

Keywords: Multiphase CTA, Acute ischemic stroke, Endovascular thrombectomy, Mechanical thrombectomy, Neuroimaging

INTRODUCTION

Acute stroke is a medical emergency that requires rapid and accurate diagnosis to determine the most appropriate treatment options. The traditional imaging modalities used for acute stroke, such as non-enhanced CT and MRI, have limitations in their ability to differentiate between the various stroke subtypes, and identifying the location and extent of the occlusion.

Multiphase CT angiography (CTA) has emerged as a valuable tool in acute stroke management due to its ability to provide a comprehensive evaluation of the neurovascular system, detect occlusions, and aid in treatment decision-making with greater accuracy and efficiency than traditional imaging.

Technique:

The feasibility of single-phase CTA arises from its simplicity, reduced radiation dosage, and lower requirement for contrast volume. However, it lacks the ability to provide precise information regarding collateral circulation. When it comes to the meticulous evaluation of cerebral vasculature and collateral circulation, the more elaborate technique of multiphase CTA is necessary.

The utilization of multiphase CTA, as a medical imaging modality, involves the administration of contrast agent, coupled with multi-phase CT scans at varying intervals. The vascular system is visualized in the arterial and venous phases, which altogether delivers a comprehensive understanding of vasculature and thereby contributes to the prompt and accurate diagnosis of acute stroke. Furthermore, the technique of multiphase CTA provides clinicians with the ability to evaluate the vascular system in real-time, facilitating expedient identification of any possible anomalies and enabling appropriate therapeutic approach.

The trade-off for such detailed information is a higher radiation dose and an increased demand for contrast volume. Thus, the decision to employ either imaging technique is contingent upon the patient's medical status, clinical manifestation, and the resources accessible at the imaging facility.

The various phases of CTA are depicted in Figure 1 (adopted from Volny et al study) which compared the two modalities.¹

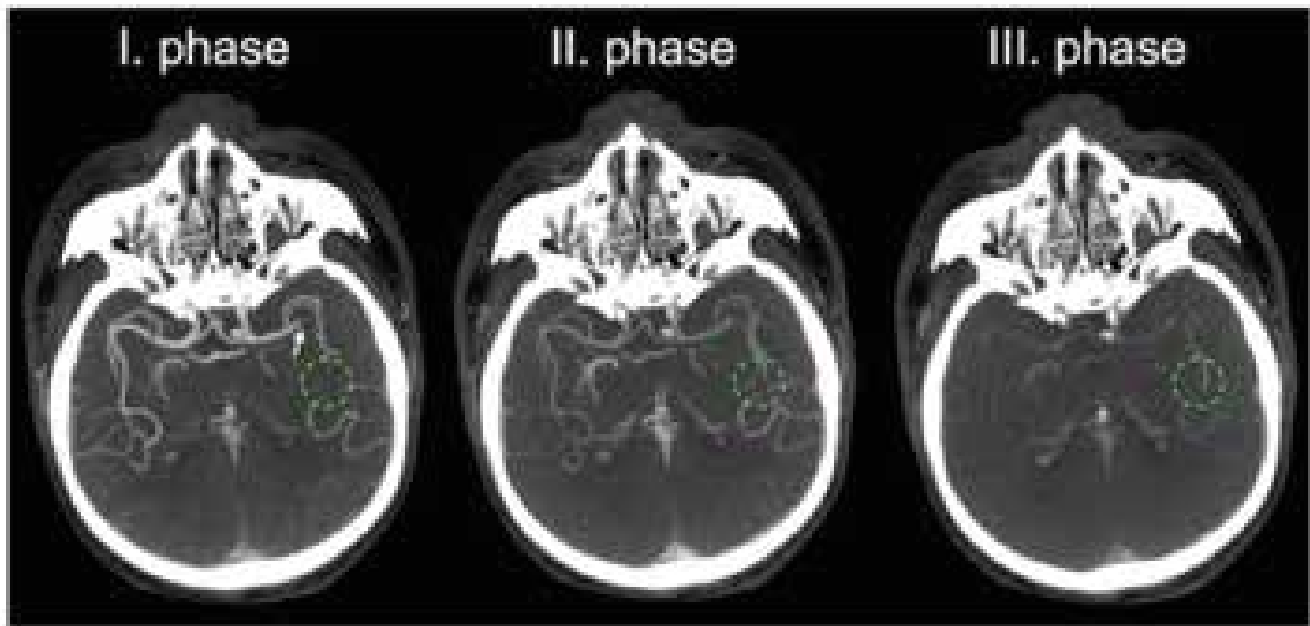


Figure 1: Multiphase CTA in distal or secondary clot detection in MCA. The primary occlusion localized in the distal M1 segment of the left MCA (white arrow) is well detectable on the first phase of multiphase CTA. The distal clot in one of the M2 branches becomes more prominent in the second and third phase (green circle) due to a delayed pial arterial filling within the territory of the occluded artery.

REVIEW

Several recent studies have demonstrated the effectiveness of multiphase CTA in acute stroke management. The effectiveness of multiphase CTA is further under debate and research in ongoing stroke trials. Multiphase CTA has been found useful in selecting appropriate thrombectomy candidates by identifying the location, extent of the occlusion and providing information about the presence of collateral circulation. Menon et al in their paper found using multiphase CTA in conjunction with the Alberta Stroke Program Early CT Score (ASPECTS) resulted in better outcome for patients who underwent endovascular treatment.²

Volny et al in their study compared single phase CTA with multiphase CTA in detecting clots in the anterior circulation there was significant benefit which was noted in M2 clot detection using multiphase imaging and furthermore it was found to be a better tool for clot detection by less experienced stroke physicians.¹ Dundamadappa et al. compared the Multiphase CTA to

Single-phase CTA and showed improved detection of large-vessel occlusion, characterization of collateral status, higher interrater reliability tolerance of patient motion and poor hemodynamics.³

A recent study conducted by Ospel et al. compared the multiphase CTA with CT-perfusion and postulated a benefit of multiphase CTA in comparison to CT-perfusion in clinical decision making for patient who would benefit from endovascular therapy.⁴ Furthermore, they found a very small number <3% patients who were eligible for thrombectomy by CT-perfusion criteria. The pooled analysis from HERMES consortium found a benefit of thrombectomy in patients with larger infarct core. This hypothetically supports that multiphase CTA for thrombectomy may be more pragmatic than CT-perfusion in selecting suitable candidates for intervention rather excluding those who may still benefit.^{4,5}

In addition to its role in diagnosing acute stroke, multiphase CTA is also a valuable tool in monitoring patients during and after treatment. By tracking the development and progression of collateral circulation over time, multiphase CTA can provide insight into the healing process and indicate any potential complications. This information can help guide clinical decision-making, assist with patient management, and improve overall patient outcomes.

One of the key advantages of multiphase CTA over traditional imaging methods is its ability to provide a

more comprehensive view of the intracranial vessels which is the cornerstone of any therapeutic endovascular intervention. In a study by Delgado et al. the authors found that CTA provided better visualization of the aneurysm in nonperimesencephalic subarachnoid hemorrhage as compared to MRA in detecting intracranial aneurysms.⁶

Despite the promise of multiphase CTA in acute stroke management, there are some concerns regarding its use. One major issue is the potential risk of radiation exposure from multiple scans. However, with recent advancements in CT technology, such as the development of low-dose scanning protocols, the risk of radiation exposure has been minimized. Another concern is the interpretation of the multiphase CTA images. Due to the complexity of the technique, specialized training and expertise are required to accurately interpret and analyze the images.

REFERENCES

1. Volny O, Cimflova P, Kadlecova P, Vanek P, Vanicek J, Menon BK, et al. Single-Phase Versus Multiphase CT Angiography in Middle Cerebral Artery Clot Detection-Benefits for Less Experienced Radiologists and Neurologists. *J Stroke Cerebrovasc Dis.* 2017;26(1):19-24.
2. Menon BK, d'Esterre CD, Qazi EM, Almekhlafi M, Hahn L, Demchuk AM, et al. Multiphase CT Angiography: A New Tool for the Imaging Triage of Patients with Acute Ischemic Stroke. *Radiology.* 2015 May;275(2):510-20.
3. Dundamadappa S, Iyer K, Agrawal A, Choi DJ. Multiphase CT Angiography: A Useful Technique in Acute Stroke Imaging-Collaterals and Beyond. *AJNR Am J Neuroradiol.* 2021 Jan;42(2):221-7.
4. Ospel JM, Volny O, Qiu W, Najm M, Hafeez M, Abdalrahman S, et al. Impact of Multiphase Computed Tomography Angiography for Endovascular Treatment Decision-Making on

CONCLUSION

Multiphase CTA is a valuable tool in acute stroke management. Its ability to provide a comprehensive evaluation of the neurovascular system, detect occlusions, and aid in treatment decision-making has made it an essential imaging modality in the management of acute stroke patients. Ongoing clinical trials will continue to evaluate the effectiveness of multiphase CTA, with the ultimate goal of improving patient outcomes.

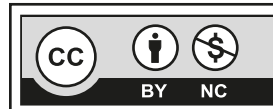
Acknowledgement:

The author graciously acknowledges the invaluable contribution of his distinguished mentors during his fellowship training in stroke medicine at the renowned Calgary Stroke Program. He would like to express his heartfelt gratitude to the esteemed luminaries - Dr. Philip Barber, Dr. Andrew Demchuk, Dr. Bijoy Menon, Dr. Michael Hill, and Dr. Mohammad Almekhlafi - for their unstinted support in helping him grasp the intricacies of advanced imaging techniques, which proved instrumental in writing this article.

- Outcomes in Patients with Acute Ischemic Stroke. *J Stroke.* 2021 Sep 30;23(3):377-87.
5. Menon BK, Hill MD, Davalos A, Roos YBWEM, Campbell BCV, Dippel DWJ, et al. Efficacy of endovascular thrombectomy in patients with M2 segment middle cerebral artery occlusions: meta-analysis of data from the HERMES Collaboration. *J Neurointerv Surg.* 2019 Nov;11(11):1065-9.
 6. Delgado Almandoz JE, Jagadeesan BD, Refai D, Moran CJ, Cross DT, Chicoine MR, et al. Diagnostic yield of computed tomography angiography and magnetic resonance angiography in patients with catheter angiography-negative subarachnoid hemorrhage. *J Neurosurg.* 2012 Aug;117(2):309-15.

Conflict of interest: Author declares no conflict of interest.

Funding disclosure: Nil



This is an Open Access article distributed under the terms of the Creative Commons Attribution-Non Commercial 2.0 Generic License.