



THE AGA KHAN UNIVERSITY

eCommons@AKU

---

Department of Surgery

Department of Surgery

---

March 2016

# Is laparoscopic pyeloplasty a comparable option to treat ureteropelvic junction obstruction (UPJO)? a comparative study.

Mazhar Ali

*Aga Khan University*, [mazhar.ali@aku.edu](mailto:mazhar.ali@aku.edu)

Syed Raziuddin Biyabani

*Aga Khan University*, [raziuddin.biyabani@aku.edu](mailto:raziuddin.biyabani@aku.edu)

Rajab Ali Ghirano

*Aga Khan University*

Wajahat Aziz

*Aga Khan University*, [wajahat.aziz@aku.edu](mailto:wajahat.aziz@aku.edu)

Khurram Mutahir Siddiqui

*Aga Khan University*

Follow this and additional works at: [http://ecommons.aku.edu/pakistan\\_fhs\\_mc\\_surg\\_surg](http://ecommons.aku.edu/pakistan_fhs_mc_surg_surg)



Part of the [Surgery Commons](#), and the [Urology Commons](#)

---

## Recommended Citation

Ali, M., Raziuddin Biyabani, S., Ghirano, R., Aziz, W., Siddiqui, K. (2016). Is laparoscopic pyeloplasty a comparable option to treat ureteropelvic junction obstruction (UPJO)? a comparative study. *JPMA: Journal of the Pakistan Medical Association*, 66(3), 224-227.

**Available at:** [http://ecommons.aku.edu/pakistan\\_fhs\\_mc\\_surg\\_surg/595](http://ecommons.aku.edu/pakistan_fhs_mc_surg_surg/595)

## Is laparoscopic pyeloplasty a comparable option to treat Ureteropelvic junction obstruction (UPJO)? A comparative study

Mazhar Ali Memon, Syed Raziuddin Biyabani, Rajab Ghirano, Wajahat Aziz, Khurram Mutahir Siddiqui

### Abstract

**Objective:** To compare laparoscopic with open pyeloplasty.

**Methods:** The retrospective study was conducted at Aga Khan University Hospital, Karachi, and comprised records of patients who underwent surgical correction of ureteropelvic junction obstruction between during January 2008 and December 2012. Patients with laparoscopic pyeloplasty were placed in group 1 and those with open pyeloplasty in group 2. The groups were compared for operative time, hospital stay, perioperative complications, blood loss, duration of surgery, outcome and follow-up. Data was analysed using SPSS 19.

**Results:** Of the 73 patients, 29(40%) were in group 1, and 44(60%) in group 2. A crossing vessel could be identified in 25(86.2%) in group 1 and in 33(75 %) in group 2. Laparoscopic procedures were associated with a longer mean operating time ( $p=0.04$ ), median estimated blood loss ( $p<0.001$ ) and a shorter mean hospital stay ( $p<0.001$ ). Follow-up mercaptoacetyltriglycinescan was done in 21(74.5%) patients in group 1 and 23(52.2%) in group 2. Only 2(7%) patients in group 1 and 2(4.5%) in group 2 had poor response on mercaptoacetyltriglycine scan. Mean follow-up was  $2.71\pm 1.2$  months. Postoperative complications were 5(13%) in group 1 and 9(20%) in group 2 ( $p=0.141$ ).

**Conclusion:** Laparoscopic pyeloplasty was associated with shorter hospital stay, less pain and less blood loss. The efficacy in term of success rate and perioperative complications of laparoscopic pyeloplasty was comparable to that of open pyeloplasty.

**Keywords:** Laparoscopy, Hydronephrosis/congenital, Minimally invasive surgical procedures. (JPMA 66: 324; 2016)

### Introduction

Ureteropelvic junction obstruction (UPJO) is a condition where flow of urine from the renal pelvis to the proximal ureter is hindered. The incidence of congenital (primary) UPJO is approximately 1 in 500 with a male-to-female ratio of 2:1.<sup>1</sup> If left untreated, UPJO may lead to loss of renal function. The surgical correction of UPJO is essential to prevent further damage of nephrons. Open surgical pyeloplasty is the traditional gold standard for the treatment of UPJO with success reported in more than 90% cases. Minimally invasive endoscopic management has been reported with variable success rate, but high recurrence rate has been reported for endoscopic correction of primary UPJO and thus this modality of treatment has little place in the current management of this anomaly.<sup>2,3</sup> Open pyeloplasty (OP) is associated with morbidity like pain and prolonged convalescence from a flank incision. Laproscopicpyeloplasty (LP) has been shown to duplicate the high success rates achieved with OP.<sup>4,5</sup> Since 1993, when the first LP was performed, published reports have shown comparable results, complication rates and recovery time with OP.<sup>6</sup> LP is now

considered the new gold standard with better success ratio than endopyelotomy, and equal functional outcomes compared to OP.<sup>2,7,8</sup> Use of laparoscopy in urology is not new. However, LP is a technically challenging operation which involves intracorporeal suturing.

The current study was planned to compare the outcomes of LP compared to OP.

### Materials and Methods

The retrospective study was conducted in January 2013 at Aga Khan University Hospital, Karachi, and comprised records of patients who underwent surgical correction of ureteropelvic junction obstruction either through LP or OP between January 2008 and December 2012. Patients with missing or incomplete data were excluded and so were those having secondary UPJO.

Patients whose records were included in the study were divided into two groups; LP in group 1 and OP in group 2.

LP was performed by a single surgeon, while OP was performed by other surgeons with at least >5-year experience in urology.

For LP, first of all rigid cystoscopy was performed in lithotomy position and ureteric orifice was cannulated with 5 Fr ureteric catheter. Retrograde pyelography was done to see the obstruction and ureteric catheter was left

.....  
Department of Surgery, Section Urology, Aga Khan University Hospital, Karachi, Pakistan.

**Correspondence:** Mazhar Ali Memon. Email: drmazharmemon110@gmail.com

at the level of obstruction or beyond that and then the distal end of ureteric catheter was fixed with 16Fr Foley. Position was changed to semi-lateral with ipsilateral side up. Anderson-Hynes (AH) dismembered pyeloplasty was the preferred choice in all but one patient with UPJO. LP was performed using three ports in all the patients through transperitoneal approach. Using the Hasson technique,<sup>9</sup> a 10mm port was placed above the umbilicus, second port (5mm) was placed at the angle between the costal margin and the lateral border of the ipsilateral rectus muscle, and third port (10mm) was placed midway between the umbilicus and the anterior superior iliac spine at the level of the umbilicus.

Colon was mobilised medially by identifying and incising Line of Tolddt, and dissection was done to identify the ureter. Gonadal vessel and psoas were the landmarks for the identification of ureter. The ureter could be distinguished from the gonadal vessels by peristalsis and by the presence of ureteric stent. After identification of ureter it was traced upwards towards the pelvis. Peripelvic fat dissection was done to allow for optimal visualization and enough mobility for a tension free anastomosis with the ureter (Figure). If the crossing vessel was identified, then ureter was divided and transposed anteriorly. The scissors were used to divide the ureter at the ureteropelvic junction (UPJ). The ureter was then spatulated on its lateral aspect (facing the medial aspect of the kidney). Corner sutures were taken first then posterior wall anastomosis was performed in a running fashion with 4-0 polydioxanone suture. Double J stent was passed antegradely and anastomosis completed. Further, 10 Frradivac drain was placed and 10mm port sheath was closed with vicryl 2-0 and skin with polypropylene 2-0.

For open dismembered pyeloplasty, a standard retroperitoneal approach through the subcostal incision was used.

Postoperative management was similar in both groups. Prophylactic antibiotics (third-generation cephalosporin) were routinely prescribed. The Foley catheter was removed 2 days postoperatively. The closed suction drain was subsequently removed if the drain output was less than 30ml in 24 hours after Foley catheter removal. Postoperatively patients were given intravenous (IV) paracetamol and opioid analgesia. Ultrasonography and renal scintigraphy were performed 02 months postoperatively. Double J stent was removed after 06 weeks in both groups.

Operative time, intraoperative estimated blood loss, presenting complaint, preoperative imaging, analgesic use, postoperative hospital stay, crossing vessel,

complications and success rates based on postoperative mercaptoacetyltriglycine (MAG3) scan at 6 months were compared for both groups. The operative time was recorded from the time of the initial skin incision to the final skin suture.

Statistical analysis was done using SPSS 19. Continuous variables were analysed by using student t test or Mann Whitney test, where applicable, and  $p < 0.05$  was taken as statistically significant.

## Results

There were 84 patients identified initially, but 11(13%) patients were excluded for missing or incomplete data. Of the 73(87%) patients in the study, LPrepair was performed on 29(40%) and OP on 44(60%)(Table 1).

Crossing vessel was identified in 33(75%) in group 2 and 25(86.2%) in group 1. Mean operative time in group 2 was  $153 \pm 45$  min and  $178 \pm 60$  min in group 1. Mean blood loss in group 1 was  $54 \pm 17$  ml compared to  $110 \pm 78$  ml in group 2 ( $p = 0.059$ ).

Mean length of stay was  $2.7 \pm 0.5$  days in group 1 compared to  $4.5 \pm 0.9$  days in group 2 ( $p < 0.000$ ).

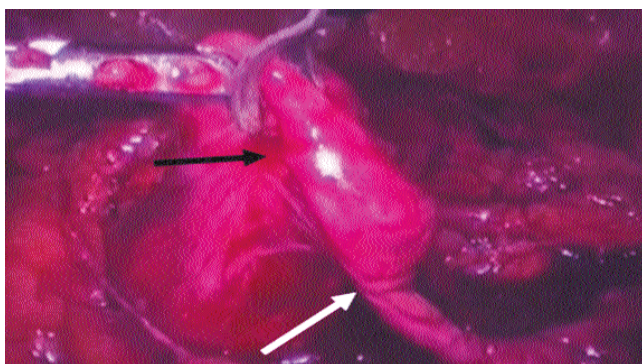
There were 7(16%) complications in group 2 against 5(17%) in group 1. Mean follow-up was  $2.7 \pm 1.2$  months (range: 1-6 months). Postoperative radionuclide scan on follow-up

**Table-1:** Demographics and operative parameters.

Characteristic	Open Approach N=44	% (60%)	Laparoscopic Approach M=29	% (40%)
Median Age (years)	28		30	
Male (n)	17	38.6	13	44.8
Female (n)	27	61.4	16	55.2
Right (n)	24	54.5	06	20.6
Left (n)	20	44.5	23	79.4
<b>Presentation</b>				
Incidental	5	11.3	2	6.8
Flank Pain	39	88.6	27	93.1
<b>Pre-operating Imaging</b>				
Ridionuclide Scan	32	72.7	29	100
Intra-venous Urography	15	34	3	10.3
Computed Tomography Scan	16	36.3	15	51.7
Ultra Sound	21	47.7	19	65.5
<b>Types of Pyeloplasty</b>				
Culp De Weerd	8	18.2	0	0
YV-Foley	2	4.5	1	3.4
Anderson Hynes	34	77.3	28	96.5
Crossing Vessel	33	75	25	86.2
Operative time (Min)	$153 \pm 45$	$178 \pm 60$		
Estimated Blood Loss (mls)	$110 \pm 78$	$54 \pm 17$		

**Table-2:** Postoperative findings.

	Open Approach N=44		Laparoscopic Approach N=29	
Length of stay (days)	4.5+0.9		2.7+0.5	
Complications	n	%	n	%
Urinary Tract Infections	4	9	1	3
JJ displaced	0	0	1	3
Perinephric Haematoma	0	0	1	3
Anastomosis Leak	1	2	1	3
Recurrent PUJO	1	2	1	3
Wound Infection	1	2	0	0
Success	42	95	27	93
Recurrence	2	4	2	6

**Figure:** Black arrow renal pelvis and white arrow narrow part of UPJO.

revealed success in 42(95%) in group 2 compared to 27(93%) (n=27) for OP vs 27(93%) in group 1 (Table-2).

## Discussion

To our knowledge, this is the first study from our region demonstrating safety and efficacy of laparoscopic approach. The first LP was described in 1993.<sup>8</sup> initially, OP was considered the gold standard with high success rate and acceptable outcome.<sup>10,11</sup> The advancement in technology led to widespread use of minimally invasive surgical techniques. A reflection of this trend was the development of LP which is now the preferred treatment modality,<sup>11,12</sup> with advantages of reduced access-related morbidity, improved visualisation, decreased blood loss, less postoperative pain, quicker recovery and better cosmesis. With respect to success rate, LP has provided equivalent results when compared to open surgery.

A crossing vessel is identified as one of the common causes of UPJO irrespective of the choice of surgical approach.<sup>13-16</sup>

In our study the LP group it was the case in had 86.2% patients. The standardised procedure of Anderson-Hynes repair is ideally suitable for crossing vessel.

Existing literature presents contradictory findings with regard to duration of surgical intervention in LP vs OP approach. This maybe a reflection of the learning curve of reconstructive laparoscopy. Some studies showed that LP is a demanding procedure and requires longer duration of time.<sup>8,17</sup> Conversely, others identified no significant difference in duration of surgery for OP versus LP.<sup>18</sup> Our study revealed that it took on average 25 min more to perform LP, and this difference was statistically significant. This review includes the experience of our first 30 cases and the increased operative time maybe a reflection of our learning curve. Literature also supports this finding as LP is a difficult procedure and demands technical expertise compared to OP. Reduced operative time can be achieved by increasing experience of surgeons and by standardisation of operative steps.<sup>19,20</sup> On the other hand, the significantly shorter length of hospital stay (2.7 days) required for LP group is an obvious advantage. This finding can be attributed to the fact that patients undergoing LP experience less postoperative pain, and have quicker recovery.<sup>8,16,19,21,22</sup> Similarly, the reduced blood loss is another advantage of minimally invasive approach and is duplicated in our study. There was a female predominance in our study which is contrary to literature.<sup>16,19</sup> As LP offers unparalleled cosmetic advantage, this may be a reflection of patient's preference or referral pattern.

Existing literature also supports that LP has lower morbidity compared to OP. In general, the reported overall complication rate of the LP ranges from 4% to 12.7%. In the present study the complication rate LP in group was 17% (n=5). There was no intraoperative complications, but there were 2 cases converted to open surgery due to the technical problems that has been reported in earlier studies as well.<sup>15,17,21,23,24</sup>

In the current study the main strength was preoperative renal scintigraphy (MAG-3) in the LP group done in 93% (n=27). Preoperative renal scintigraphy is important to identify patients who will benefit most from repair and also helps in comparison during postoperative follow-up.<sup>8,21</sup>

In our study, 75% (n=22) LP patients got the postoperative MAG-3 in follow-up. Relatively less data is available for radionuclide scan during follow-up.<sup>8</sup> We recommend postoperative radionuclide scan routinely in all patients undergoing LP. As reduction of renal pelvis is not routinely performed during LP, imaging modalities like intravenous pyelogram (IVP) or ultrasonography (USG) may provide erroneous result in this setting.



Conversion to OP is a recognised complication of LP<sup>8,16,21,22</sup>. All patients should be informed about this technical problem. In our series, 3 patients were converted from LP to OP. In all 3 of these cases, the reason was technical difficulty in achieving a tension-free anastomosis.

Despite initial concerns, the success rate of LP is comparable to OP. Previous studies are limited by variable follow-up strategies and definition of success.<sup>12,20,25</sup> We report a success rate of 93% in our LP cohort using radionuclide scan as the primary modality for follow-up.

Our study is limited by a few considerations. Firstly, the small sample size of each group did not allow for subgroup analysis. Secondly, the duration of follow-up was short, so the long-term results of LP could not be inferred.

## Conclusion

LP had equivalent success rate compared to OP but offered all the advantages of minimally invasive treatment. With shorter hospital stay and better cosmetic results, laparoscopic dismembered pyeloplasty has the potential to replace open surgery and, provided there is availability of expertise, it should be considered the first option for the treatment of ureteropelvic junction obstruction.

## References

1. Khan F, Ahmed K, Lee N, Challacombe B, Khan MS, Dasgupta P. Management of ureteropelvic junction obstruction in adults. *Nature Rev Urol* 2014; 11: 629-38.
2. Penn HA, Gatti JM, Hoestje SM, DeMarco RT, Snyder CL, Murphy JP. Laparoscopic versus open pyeloplasty in children: preliminary report of a prospective randomized trial. *J Urol* 2010; 184: 690-5.
3. Zhang X, Li H-Z, Ma X, Zheng T, Lang B, Zhang J, et al. Retrospective comparison of retroperitoneal laparoscopic versus open dismembered pyeloplasty for ureteropelvic junction obstruction. *J Urol* 2006; 176: 1077-80.
4. Shahnawaz AS, Shahzad I, Baloch MU. Our experience with open dismembered pyeloplasty for uretero-pelvic junction obstruction. *Pak J Med Sci* 2014; 30: 153.
5. Eden C, Gianduzzo T, Chang C, Thiruchelvam N, Jones A. Extraperitoneal laparoscopic pyeloplasty for primary and secondary ureteropelvic junction obstruction. *J Urol* 2004; 172: 2308-11.
6. Golda N, Kapoor A, DeMaria J. Laparoscopic pyeloplasty: role of preoperative retrograde pyelography. *J Pediatr Urol* 2008; 4: 162-4.
7. Bauer JJ, Bishoff JT, Moore RG, Chen RN, Iverson AJ, Kavoussi LR. Laparoscopic versus open pyeloplasty: assessment of objective and subjective outcome. *J Urol* 1999; 162: 692-5.
8. Klingler HC, Remzi M, Janetschek G, Kratzik C, Marberger MJ. Comparison of open versus laparoscopic pyeloplasty techniques in treatment of uretero-pelvic junction obstruction. *Eur Urol* 2003; 44: 340-5.
9. Poole GH, Frizelle FA. Modifications To The Hasson Technique. *Aust N Z J Surg* 1996; 66: 770.
10. Psooy K, Pike J, Leonard M. Long-term followup of pediatric dismembered pyeloplasty: how long is long enough? *J Urol* 2003; 169: 1809-12.
11. Schuessler W, Grune M, Tecuanhuey L, Preminger G. Laparoscopic dismembered pyeloplasty. *J Urol* 1993; 150: 1795-9.
12. Jarrett TW, Chan DY, Charambura TC, Fugita O, Kavoussi LR. Laparoscopic pyeloplasty: the first 100 cases. *J Urol* 2002; 167: 1253-6.
13. Srivastava A, Singh P, Maheshwari R, Ansari MS, Dubey D, Kapoor R, et al. Laparoscopic pyeloplasty: a versatile alternative to open pyeloplasty. *Urol Int* 2009; 83: 420-4.
14. Stern JM, Park S, Anderson JK, Landman J, Pearle M, Cadeddu JA. Functional assessment of crossing vessels as etiology of ureteropelvic junction obstruction. *Urology* 2007; 69: 1022-4.
15. Boylu U, Basatac C, Turan T, Onol FF, Gumus E. Comparison of surgical and functional outcomes of minimally invasive and open pyeloplasty. *J Laparoendosc Adv Surg Tech A* 2012; 22: 968-71.
16. Hao G, Xiao J, Yang P, Shen H. Laparoscopic retroperitoneal dismembered pyeloplasty: single-center experience in China. *J Laparoendosc Adv Surg Tech A* 2013; 23: 38-41.
17. Bonnard A, Fouquet V, Carricaburu E, Aigrain Y, El-Ghoneimi A. Retroperitoneal laparoscopic versus open pyeloplasty in children. *J Urol* 2005; 173: 1710-3.
18. Mei H, Pu J, Yang C, Zhang H, Zheng L, Tong Q. Laparoscopic versus open pyeloplasty for ureteropelvic junction obstruction in children: a systematic review and meta-analysis. *J Endourol* 2011; 25: 727-36.
19. Singh O, Gupta SS, Arvind NK. Laparoscopic pyeloplasty: an analysis of first 100 cases and important lessons learned. *Int Urol Nephrol* 2011; 43: 85-90.
20. Abuaz S, Gamé X, Roche J-B, Guillotreau J, Mouzin M, Sallusto F, et al. Laparoscopic pyeloplasty: comparison between retroperitoneoscopic and transperitoneal approach. *Urology* 2010; 76: 877-81.
21. Calvert R, Morsy M, Zelhof B, Rhodes M, Burgess N. Comparison of laparoscopic and open pyeloplasty in 100 patients with pelvi-ureteric junction obstruction. *Surg Endoscop* 2008; 22: 411-4.
22. Simforoosh N, Basiri A, Tabibi A, Danesh A, Sharifi-Aghdas F, Ziaee SA, et al. A comparison between laparoscopic and open pyeloplasty in patients with ureteropelvic junction obstruction. *Urol J* 2004; 1: 165-9.
23. Zhang X, Li HZ, Wang S-G, Ma X, Zheng T, Fu B, et al. Retroperitoneal laparoscopic dismembered pyeloplasty: experience with 50 cases. *Urology* 2005; 66: 514-7.
24. Braga LH, Pace K, DeMaria J, Lorenzo AJ. Systematic review and meta-analysis of robotic-assisted versus conventional laparoscopic pyeloplasty for patients with ureteropelvic junction obstruction: effect on operative time, length of hospital stay, postoperative complications, and success rate. *Eur Urol* 2009; 56: 848-58.
25. Umari P, Lissiani A, Trombetta C, Belgrano E. Comparison of open and laparoscopic pyeloplasty in ureteropelvic junction obstruction surgery: report of 49 cases. *Arch Ital Urol Androl* 2011; 83: 169-74.