



THE AGA KHAN UNIVERSITY

eCommons@AKU

---

Department of Medicine

Department of Medicine

---

January 2014

# Mediastinal Synovial Sarcoma.

Niaz Hussain Soomro  
*Dow University of Health Sciences*

Sanaullah Junejo  
*Dow University of Health Sciences*

Aneeqa Ahsan Zafar  
*Dow University of Health Sciences*

Shirin Siddiqi  
*Dow University of Health Sciences*

Ghulam H  
*Aga Khan University, ghulam.haider@aku.edu*

Follow this and additional works at: [http://ecommons.aku.edu/pakistan\\_fhs\\_mc\\_med\\_med](http://ecommons.aku.edu/pakistan_fhs_mc_med_med)



Part of the [Dermatology Commons](#), and the [Oncology Commons](#)

---

## Recommended Citation

Soomro, N. H., Junejo, S., Zafar, A. A., Siddiqi, S., H, G. (2014). Mediastinal Synovial Sarcoma.. *JSP: Journal of Surgery Paksitan*, 19(1), 45-47.

**Available at:** [http://ecommons.aku.edu/pakistan\\_fhs\\_mc\\_med\\_med/585](http://ecommons.aku.edu/pakistan_fhs_mc_med_med/585)

See discussions, stats, and author profiles for this publication at: <https://www.researchgate.net/publication/281095811>

# Mediastinal Synovial Sarcoma

Article · January 2014

---

CITATIONS

0

---

READS

27

4 authors, including:



[Niaz Hussain Soomro](#)

Dow University of Health Sciences

32 PUBLICATIONS 31 CITATIONS

[SEE PROFILE](#)



[Aneeqa Ahsan Zafar](#)

Dow University of Health Sciences

17 PUBLICATIONS 1 CITATION

[SEE PROFILE](#)

# Mediastinal Synovial Sarcoma

Niaz Hussain Soomro, Sanaullah Junejo, Aneeqa Ahsan Zafar,  
Shirin Siddiqi, Ghulam Haider

## ABSTRACT

*The mediastinum is an uncommon site of synovial sarcoma which is a rare soft tissue malignancy. An 18 year old boy was admitted for right sided chest pain since one year. Based on the CT scan chest findings, tru-cut biopsy of the mass was performed and histopathology initially reported as neurofibroma. The tumor was excised via posterolateral thoracotomy and excisional biopsy established the diagnosis of primary synovial sarcoma arising from the mediastinum. Patient was started on adjuvant chemotherapy at the oncologist tumor board's recommendation and he received 6 cycles of adriamycin and ifosfamide. At last follow up he is free of tumor recurrence.*

*Key words* Soft tissue sarcoma, Mediastinal mass, Mediastinal synovial sarcoma.

## INTRODUCTION:

Synovial sarcoma, which has been named after its microscopic resemblance to normal synovium, is a rare and aggressive malignancy of soft tissues that usually occurs in close proximity to large joints of the extremities though it may be found in almost any part of the body.<sup>1</sup> Its occurrence in the mediastinum was first reported in the early 1990s.<sup>2</sup> Genetic factors, specially chromosomal translocation t(X;18) (p11;q11) are believed to influence the development of this disease.<sup>1,2</sup> Synovial sarcoma represents between 5% and 10% of all soft tissue sarcomas. Herein one such case is reported.

## CASE REPORT:

An 18 year male presented with complaint of pain in right side of the chest for one year, not associated with fever, weight loss or hemoptysis. On examination, patient was of average height and thin built with normal vitals. Examination of the chest showed decreased movements, dull percussion note and absent breath sounds in right lower zone. Rest of the systemic examination was unremarkable.

Chest x-ray showed a homogenous opacity in the right middle and lower zones (Fig-I). C.T scan chest a soft tissue mass, 12 cm x 10 cm, in the right lower

revealed hemithorax, with smooth margins and linear calcification. No definite erosion of ribs or vertebrae noted. Mass was obscuring the dome of diaphragm, extending towards the posterior mediastinum and para-vertebral region. Possibility of a large neurogenic tumor or pleural based mass was suggested and tru-cut biopsy was recommended for further evaluation. Ultrasound guided tru-cut biopsy was done. It was reported as neurofibroma.

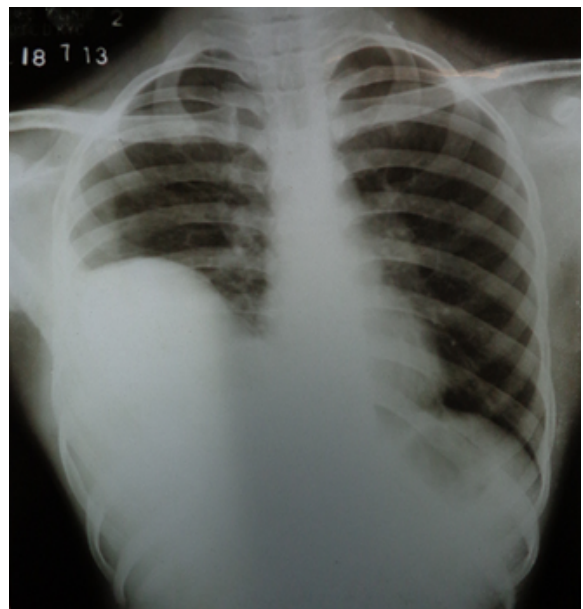


Fig-I: X-ray chest showing homogenous opacity in right lower zone

## Correspondence:

Dr. Niaz Hussain Soomro  
Department of Thoracic Surgery  
Ojha Institute of Chest Disease  
Dow University of Health Sciences  
Karachi  
E mail: soomroniaz@yahoo.com

After preoperative assessment, posterolateral thoracotomy and excision of tumor was performed. The tumor measured about 16 cm x 13 cm. It was firm in consistency, involving posterior mediastinum

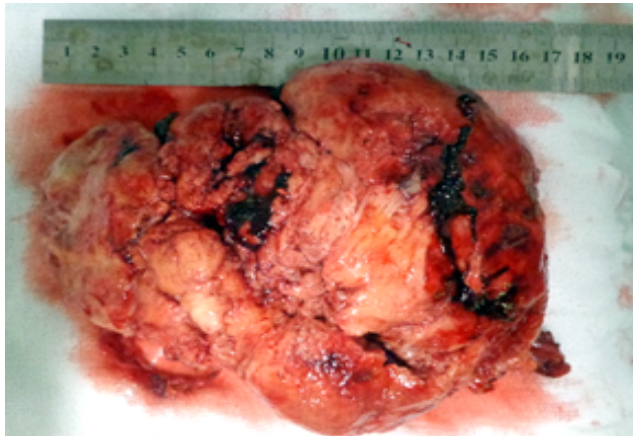


Fig-II: A multinodular tumor removed at Thoracotomy

adherent to the posterolateral chest wall, diaphragm and lungs (Fig-II). It consisted of light brown multinodular firm tissue, and the outer surface had a dark brown haemorrhagic appearance. On morphologic and immunohistochemical features, a diagnosis of spindle cell synovial sarcoma was made.

Postoperative recovery was smooth. The case was discussed in multi-disciplinary tumor board meeting. Board uniformly agreed to give 6 cycles of adjuvant chemotherapy with adriamycin and ifosfamide. Patient is on regular follow up without evidence of residual or recurrent disease.

#### DISCUSSION:

The term synovial sarcoma is a misnomer because the tumor does not arise from the synovium; it only resembles synovial tissue on light microscopy. It appears to arise from multipotent stem cells that are capable of differentiating into mesenchymal and/or epithelial structures and lack synovial differentiation.<sup>1,2</sup>

Only about 1-3 individuals in a million population are diagnosed each year. This disease has the peak incidence before the 30th birthday with male gender predilection.<sup>3</sup> Our patient had similar characteristics.

Histologically, the tumor has been divided into four different subtypes.<sup>4</sup> The biphasic variant is composed of spindle shaped fibroblast like cells and epithelioid cells but majority of tumors are monophasic spindle cell variety that show either spindle cells only or an epithelial component. Our patient was diagnosed to have primary monophasic spindle cell synovial sarcoma.

Surgical removal of tumor with clear margins followed by radiotherapy or chemotherapy is the preferred

mode of treatment. Synovial sarcoma is a chemosensitive tumor. This was used as a neoadjuvant therapy and for recurrence of the tumor.<sup>5</sup> Spurrell et al and Spillane et al suggest that chemotherapy with ifosfamide and doxorubicin have the best response rates.<sup>4</sup> Chemotherapy is highly dependent on the size, grade and location of the tumor. A study conducted by Ferrari et al reported recurrence reduction following radiotherapy.<sup>6</sup> In general, with conventional fractionation radiotherapy doses between 50 and 70 Gy should be administered.<sup>7</sup>

Traditionally, synovial sarcoma has been considered to have a poor prognosis with metastasis occurring in 50% of the cases. The lung is the most common site for metastasis followed by lymph nodes and bone. However, not all synovial sarcomas share the same dismal outcome anymore. Spillane et al. demonstrated that an age >20 year at diagnosis and size > 5 cm were associated with a significantly worse prognosis.<sup>3,8</sup> However, prognosis after aggressive multimodal therapy is good and survival up to 14 years has been documented.<sup>5</sup> The mediastinum is an uncommon site of occurrence of synovial sarcoma that occurred in index case. Aggressive multimodal therapy is recommended and our patient has responded to surgery and chemotherapy.

#### REFERENCES:

1. Siegel HJ, Sessions W, Casillas Jr MA, Said-Al-Naief N, Lander PH, Lopez-Ben R, et al. Synovial-sarcoma Clinicopathologic features treatment and prognosis. *Orthopedics*. 2007;30: 1020-5.
2. Peoc'h M, Le Marc'hardour F, Bost F, Pasquier D, Roux JJ, Pinel N, et al. Primary synovial sarcoma of the mediastinum. A case report with immune histochemistry, ultrastructural and cytogenetic study. *Ann Pathologie*. 1995;15:203-6.
3. Weiss SW, Goldblum J. Malignant soft tissue tumors of uncertain type. In Weiss SW, Goldblum JR. *Enzinger and Weiss's Soft Tissue Tumors*. St Louis, Missouri: CV Mosby. 2001:1483-1571.
4. Spurrell EL, Fisher C, Thomas JM, Judson IR. Prognostic factors in advanced synovial sarcoma: an analysis of 104 patients treated at the Royal Marsden Hospital. *Ann Oncol*. 2005;16:437-44.

5. Van der Mieren G, Willems S, Dumez H, Van Oosterom A. Pericardial synovial sarcoma: 14-year survival with multimodality therapy. *Ann Thorac Surg.* 2004;78:e41-e2.
6. Ferrari A, Gronchi A, Casanova M, Meazza C, Gandola L, Collini P, et al. Synovial sarcoma: A retrospective analysis of 271 patients of all ages treated at a single institution. *Cancer.* 2004;101:627-34.
7. Mullen JR, Zagars GK. Synovial sarcoma outcome following conservation surgery and radiotherapy. *Radiotherapy Oncol.* 1994;33:23-30.
8. Spillane AJ, A'Hern R, Judson IR, Fisher C, Thomas JM. Synovial sarcoma: clinicopathologic, staging and prognostic assessment. *J Clin Oncol.* 2000;18:3794-803.