



THE AGA KHAN UNIVERSITY

eCommons@AKU

Department of Radiology

Medical College, Pakistan

8-2009

Arterio-venous fistula of upper arm observed with injection abscess

Saba Sohail

Misbah Talpur

Follow this and additional works at: https://ecommons.aku.edu/pakistan_fhs_mc_radiol



Part of the [Radiology Commons](#)

Letter to the Editor

Arterio-venous fistula of upper arm observed with injection abscess

Madam, An injection abscess is an iatrogenic infection usually secondary to contaminated injectables or inadequate sterilization protocols.¹ The usual sites are upper arm, hand and buttocks.²⁻⁴ Main presenting features are pain, swelling and fever with mean healing time of two to four days.^{3,4} The reported complications include re-infection, recurrence and discharging sinus.⁴

Despite extensive literature search, there was no report of an injection abscess leading to Arterio-venous (AV) fistula formation. We encountered a young man aged 24 years, non-diabetic, immuno-competent, non-drug user, resident of a slum area who was referred from surgical OPD for x-ray sinogram with provisional diagnosis of injection

abscess sinus. Two weeks ago, he had an injection delivered to right deltoid region by a local practitioner, for abdominal pain. The injection site became inflamed within a day. The swelling and pain did not recede despite using local and oral anti-inflammatory and antibiotic agents and started a sero-purulent discharge. A day before presentation, the discharge turned blood stained. The patient was then referred to Civil Hospital Karachi.

On examination, it was a red looking excoriated tender sinus opening located just above the right deltoid tuberosity oozing a ser-sanguineous discharge on manual pressure. Axillary and cervical lymph nodes were not palpable. After confirming normal coagulation profile and

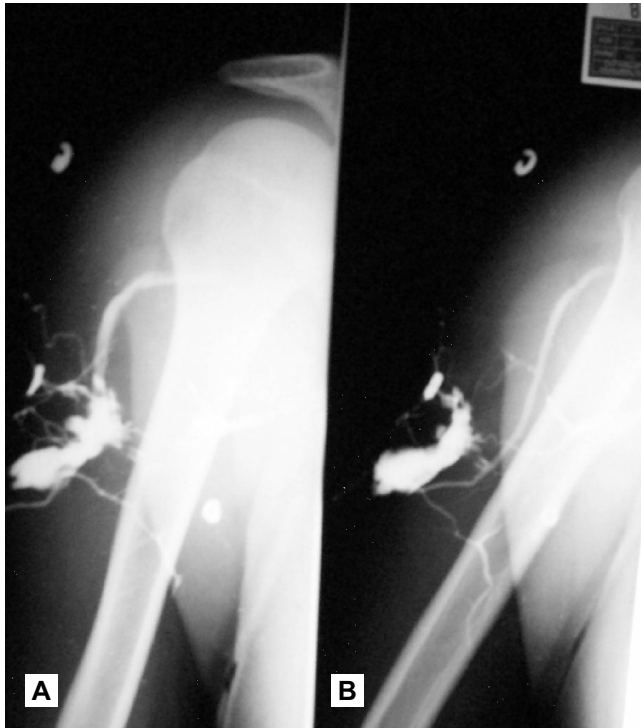


Figure A and B: AV fistula of upper arm demonstrated from injecting into a sinus.

ensuring sterility, a small size feeding tube was introduced into the sinus ostium and 5 mls of non-ionic contrast was slowly injected under fluoroscopic control. On recognizing the vascular anatomy of upper arm, being visualized on fluoroscopic monitor, the procedure was immediately stopped. The connection visualized was the brachial artery and the cephalic vein while the profunda brachii and the anastomosis around scapula was also visualized along with the subclavian vessels (Figure-1A & B). Fluoroscopy showed contrast in the renal calyces confirming entry into the systemic circulation. An immediate complimentary

Doppler examination was performed which confirmed the presence of a communicating channel between the said vessels with arterialized flow in the lesion, establishing the diagnosis of AV fistula. The diagnosis was explained to the patient with an immediate admission through emergency. The patient went home after two hours of uneventful monitoring and did not report back.

The case highlights some important points. First, an AV fistula in connection with injection abscess has not been described before. Kaiser et al. described a single case out of 13 inguinal injection abscesses that had caused necrosis of femoral artery leading to erosion of tunica, bleeding and aneurysm formation requiring synthetic graft.⁵ It cannot be definitely said whether the man already had a silent congenital AV fistula that got unearthed (or rather 'unskinned') by the surrounding infection or it was the squeal of the infection. The loss of follow up also leaves doubt about the definitive management. It cannot be ascertained whether there were any late untoward reactions of contrast administration.

Still, based on this experience, we suggest that a sinus, fistula, abscess or lump that either pulsates or exudes blood, should preferably be excluded for an underlying vascular cause before being cannulated or probed.

Saba Sohail, Misbah Talpur

Radiology Department, Dow University of Health Sciences, Karachi.

References

1. Devi DR, Indumathi VA, Indira S, Babu PR, Sridharan D, Belwardi MR. Injection site abscess due to *M. fortuitum*: a case report. *Ind J Med Microbiol* 2003; 21: 133-4.
2. Siddiqe M, Iqbal SA. Pattern of abscesses at Civil Hospital Karachi. *Pak J Surg* 2005; 21: 15-8.
3. Mirza M, Sarwar M. Tuberculous injection abscess. *Pak J Surg* 2003; 8: 37-8.
4. Chaudhry ZA, Arshad AR, Choudhry AM. Incision drainage of soft tissue