



THE AGA KHAN UNIVERSITY

eCommons@AKU

---

Department of Medicine

Department of Medicine

---

May 2012

# Primary billiary cirrhosis (antimitochondrial antibody negative) leading to secondary amyloidosis.

Om Parkash

Agha Khan University, [om.parkash@aku.edu](mailto:om.parkash@aku.edu)

Aysha Almas

Aga Khan University, [aysha.almas@aku.edu](mailto:aysha.almas@aku.edu)

Follow this and additional works at: [http://ecommons.aku.edu/pakistan\\_fhs\\_mc\\_med\\_med](http://ecommons.aku.edu/pakistan_fhs_mc_med_med)



Part of the [Gastroenterology Commons](#), and the [Internal Medicine Commons](#)

---

## Recommended Citation

Parkash, O., Almas, A. (2012). Primary billiary cirrhosis (antimitochondrial antibody negative) leading to secondary amyloidosis.. *JCPSP: Journal of the College of Physicians and Surgeons--Pakistan*, 22(5), 330-332.

Available at: [http://ecommons.aku.edu/pakistan\\_fhs\\_mc\\_med\\_med/418](http://ecommons.aku.edu/pakistan_fhs_mc_med_med/418)

# Primary Biliary Cirrhosis (Antimitochondrial Antibody Negative) Leading to Secondary Amyloidosis

Om Parkash and Aysha Almas

## ABSTRACT

A 49 years old lady presented with low-grade fever (99-100°F) for 2 years. During this time she was extensively worked-up for pyrexia of unknown origin but no diagnosis could be established. Her Initial blood work-up was all negative except high alkaline phosphatase and gamma GT (374 IU and 195 IU respectively). She later presented to our tertiary care centre with facial swelling, flushing and bilateral pedal swelling for 3 months. Along with generalized body swelling she had frothy urine. She was diagnosed as nephrotic syndrome on the basis of nephrotic range proteinuria.

Her Renal biopsy done for workup of nephrotic was positive for AA amyloid. Also, her gastrointestinal biopsy was suggestive of amyloidosis. As a workup for secondary amyloidosis, her liver biopsy was done which revealed features of primary biliary cirrhosis (PBC).

**Key words:** *Amyloidosis. Proteinuria.*

---

## INTRODUCTION

Amyloidoses are protein conformation disorders, in which different soluble proteins aggregate as extracellular insoluble fibrils.<sup>1</sup> Amyloid fibrils associate with other moieties, including glycosaminoglycans and serum amyloid P component (SAP), forming deposits that disrupt the structure and function of tissues and organs.<sup>2</sup> Systemic amyloidoses are subdivided into familial amyloidosis (AF), secondary amyloidosis (AA) in patients with long-standing infections or inflammatory processes, senile amyloidosis (wild-type ATTR), and immunoglobulin light-chain amyloidosis (AL).<sup>3</sup> Primary amyloidosis (AL) represents the most common form of systemic amyloid deposition and is typically associated with immunocyte dyscrasias such as multiple myeloma, lymphomas, macroglobulinemia and "benign" monoclonal gammopathies.<sup>4</sup>

Secondary systemic AA amyloidosis can complicate chronic inflammatory disorders that are associated with a sustained acute-phase response. AA amyloid fibrils are derived from the acute-phase reactant serum amyloid A (SAA) protein.<sup>1</sup> Associated disorders include adult rheumatoid arthritis, juvenile rheumatoid arthritis, ankylosing spondylitis, Reiter's syndrome, systemic lupus erythematosus, systemic sclerosis, tuberculosis, leprosy, Castleman's disease, bronchiectasis, cystic fibrosis, osteomyelitis, heroin abuse, psoriasis, inflammatory bowel disease and Whipple's disease.<sup>4</sup>

---

*Department of Medicine, The Aga Khan University Hospital, Karachi.*

**Correspondence:** *Dr. Aysha Almas, Department of Medicine, Faculty Office Building (2nd Floor), The Aga Khan University Hospital, Karachi.*

*E-mail: aysha.almas@aku.edu*

*Received June 14, 2011; accepted December 24, 2011.*

Previously, there have been reports on association of cholestasis and amyloidosis, but literature does not report an association of secondary amyloidosis and biopsy proven primary biliary cirrhosis from Pakistan. We report here a case of secondary amyloidosis with primary biliary cirrhosis (antimitochondrial antibody negative) along with extensive gastrointestinal and renal involvement.

## CASE REPORT

A 49 years old lady presented with low-grade fever (99-100°F) for 2 years. During this time she was extensively worked-up for pyrexia of unknown origin but no diagnosis could be established. Her initial blood workup was all negative except high alkaline phosphatase and gamma GT (374 IU and 195 IU respectively). Hepatitis serology, bone marrow, CSF, CT chest; all were normal. CT abdomen showed poorly defined hypodense lesions in right lobe of liver (segment VI and VII), no splenomegaly and no lymphadenopathy. Autoimmune workup (ANA, Anti DNA, ASMA, AMA ANCA) all were negative. CA 125, AFP, CEA and CA 15-3 were all negative.

She later presented to our tertiary care centre with facial swelling, flushing and bilateral pedal swelling for 3 months. Along with generalized body swelling, she had frothy urine. She was diagnosed as nephrotic syndrome on the basis of nephrotic range proteinuria and was started on steroids prior to presentation at our centre. Her fever had subsided in a week after starting steroids.

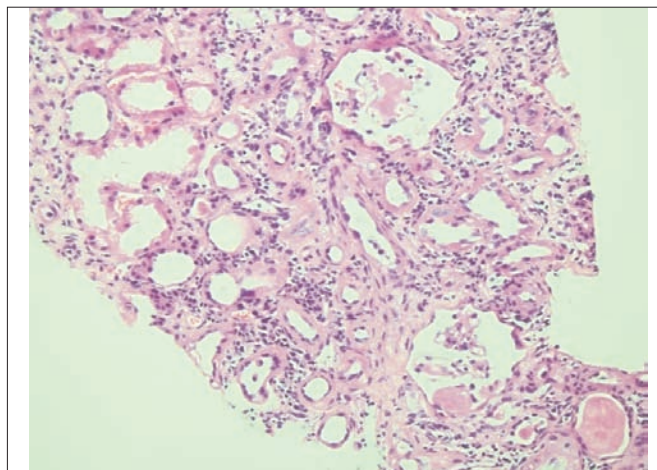
She had a past history of hypertension and had undergone hysterectomy. Her appetite was decreased and she had loose motions occasionally. She was currently on prednisolone, spironolactone, furosemide and simvastatin.

On examination, she was a middle aged lady well preserved. She had blood pressure of 101/68 mmHg. She was afebrile, with respiratory rate of 22 breaths/minute, pulse of 90 beats/minute. She was pale, had puffy face and had ankle oedema. Cardiovascular examination was unremarkable. Chest had decreased air entry at bases. Abdomen was distended with abdominal striae and liver was palpable. Initial laboratory investigations are shown in Table I.

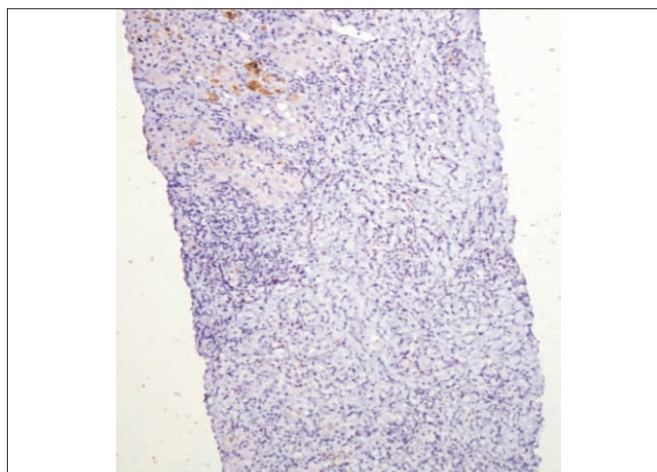
**Table I:** Initial laboratory investigations.

Workup on initial presentation		
Hb: 13.2 g/dl	T bil: 0.4 mg/dl	
WBC: 15.6 X 10E9/L (63% N)	SGPT: 42 IU/L	
Plt: 215 X 10E9/L	AP: 599 IU/L	
BUN: 8 mg/dl	Gamma GT:374 IU/L	
Cr: 0.7 mg/dl	T prot: 3.8 g/dl	
Na: 133 mg/dl	LDH: 812 IU/L	
K: 2.9 mg/dl	UA: 4.3 mg/dl	
Cl: 108 mg/dl	PT/APTT : Normal	
HCO: 21.6 mg/dl	Urine DR: +3 protien	
RBS: 108 mg/dl		
Workup during admission		
Serum protein Electrophoresis: normal	Autoimmune workup	
ESR: 56 mm	ANA	
Hepatitis B sAg: -ve	Anti DNA	
Hepatitis C Ab: -ve	ASMA	-ve
24 Urinary protein: 5.3 gm/day	AMA	
Calcium: 7.2 mg/dl	LKM	
CRP: 3.8 mg/dl	Tumour markers	
Cortisol: 9.80 µg/dl	CEA: 7.41 ng/ml	
Hypercoaguable workup: -ve	Alpha feto protein: 6 IU/ml	
	Bone marrow : Normal	

The initial differential diagnosis on admission was iatrogenic Cushing syndrome, nephrotic syndrome and cholestatic liver. Along with this, the lady had history of pyrexia of unknown origin (PUO) which was the primary disease responsible for the current presentation. The differential diagnosis of PUO at this point was malignancy (solid tumour), lymphoma (which resolved with steroids), autoimmune disease or tuberculosis. The repeat CT chest and abdomen showed portal vein thrombosis, wedge shaped areas in liver and chronic liver parenchymal disease. Further, laboratory investigations sent during the admission are shown in Table I. Renal biopsy was done which was suggestive of amyloidosis (Figure 1). It was positive for AA amyloid. The dilemma still in this patient, was the cause of secondary amyloidosis. Her workup so far was inconclusive (no malignancy, autoimmune workup was negative, no evidence of chronic infection). During this time she again developed increased frequency of loose stools. Stool DR did not show any pus cells. Upper GI endoscopy and colonoscopy were performed. Biopsy of body and antrum of stomach showed non-specific gastritis, duodenum terminal ileum and caecum showed amyloidosis and descending colon showed moderate focal active colitis. At this point the liver biopsy slides



**Figure 1:** Renal biopsy showing amyloid deposits.



**Figure 2:** Liver biopsy with cytochrome and trichrome stain cytochrome.

(which were done earlier) were reviewed after carrying out special stains with trichrome and cytochrome which were not done earlier (Figure 2). The liver biopsy revealed dense acute and chronic portal inflammation (lymphocyte, plasma cell and occasional neutrophils) with interface hepatitis with lobular activity, feathery degeneration of hepatocytes, cholestatic liver cell rosettes and paucity of bile ducts. It was negative for amyloid.

Hence, the final diagnosis was 49 years old female with primary biliary cirrhosis (antimitochondrial antibody negative) leading to secondary amyloidosis. She was treated with ursofac for PBC along with diuretics and ACE inhibitors and anticoagulation.

### DISCUSSION

Hepatic involvement in amyloidosis has been reported previously. Associations have been found with primary biliary cirrhosis and cholestasis from Northern America.<sup>5</sup> We report a case of PBC (AMA negative), leading to amyloidosis with extensive gastrointestinal and renal

involvement. The typical PBC diagnostic criteria includes (i) ALP levels at least twice or  $\gamma$ -glutamyl transpeptidase ( $\gamma$ GT) levels at least five times the upper limit of normal, (ii) positive AMA, and (iii) a liver biopsy showing florid bile duct lesion.<sup>6</sup> However, AMA negative PBC patients appear to have a disease that otherwise is identical to the AMA positive cases.<sup>7</sup> A liver biopsy is necessary for the diagnosis of PBC to be established in the absence of AMA.<sup>8</sup> This patient had AMA negative PBC based on the clinical history of pruritis, high alkaline phosphatase, gamma glutamine transferase and histological finding of PBC (degenerating bile duct epithelium with focal bile duct obliteration, severe lymphocytic interface hepatitis, portal lymphocytic infiltrate).<sup>9</sup>

Previous cases have been reported on PBC leading to amyloidosis, however, this was mainly AMA positive PBC.<sup>5</sup> Clinically patients with PBC with amyloidosis presents as end stage liver disease manifesting as ascites, encephalopathy, and recurrent oesophageal variceal bleeding.<sup>5</sup> Rodriguez-luna reports a case of primary biliary cirrhosis and systemic amyloidosis in which the patient presented with symptoms (ascites, encephalopathy, recurrent variceal bleeding) of end stage liver disease. This patient was referred for liver transplant, before that a renal biopsy was done to identify the cause of the renal dysfunction which showed amyloidosis. Subsequently, liver biopsy also revealed amyloidosis.<sup>5</sup> However, the patient did not present as decompensated cirrhosis, rather only, with symptoms of cholestasis along that gastrointestinal involvement secondary to amyloidosis. The liver biopsy did not show any evidence of amyloidosis, hence this patient had secondary amyloidosis. Jeong reported 2 similar cases who presented with hepatic encephalopathy and on liver biopsy were found to have amyloidosis.<sup>10</sup> Peter reported 5 cases of primary amyloidosis and severe intrahepatic cholestatic jaundice, but amyloid deposits were present on liver biopsy of most of these patients.<sup>11</sup>

Secondary amyloidosis (AA) is associated with long-standing infectious or non-infectious inflammatory disorders and, less frequently, neoplastic disorders.<sup>4</sup> There are case reports on association of primary biliary cirrhosis and cutaneous amyloidosis.<sup>12</sup> However, after extensive literature search we could not find any case of AMA negative PBC associated with secondary amyloidosis. The prognosis of secondary amyloidosis is

dependent on the treatment of the primary disease or inflammatory state. The timely recognition of AMA negative PBC is not only important from a classification standpoint, but it may have implications for therapy. UDCA has been demonstrated in randomized, controlled trials to be an effective therapy for the treatment of PBC.

In summary, amyloidosis is a disease which is usually diagnosed late in its course due to its variable clinical presentation. Moreover, prognosis of secondary amyloidosis is dependant on the primary disease. Primary biliary cirrhosis (AMA negative) as a primary cause is often difficult to diagnose and hence treatment is delayed leading to a complicated course of amyloidosis in such cases.

## REFERENCES

1. Merlini G, Bellotti V. Molecular mechanisms of amyloidosis. *N Engl J Med* 2003; **349**:583-96.
2. Pepys MB. Amyloidosis. *Annu Rev Med* 2006; **57**:223-41.
3. Gertz MA, Rajkumar SV. Primary systemic amyloidosis. *Curr Treat Options Oncol* 2002; **3**:261-71.
4. Gillmore JD, Hawkins PN, Pepys MB. Amyloidosis: a review of recent diagnostic and therapeutic developments. *Br J Haematol* 1997; **99**:245-56.
5. Rodriguez-Luna H, Vargas HE, Williams J, De Petris G, Rakela J, Douglas DD. Primary biliary cirrhosis and systemic amyloidosis, a new association. *Dig Dis Sci* 2004; **49**:1196-200.
6. Boberg KM, Chapman RW, Hirschfield GM, Lohse AW, Manns MP, Schrupf E. Overlap syndromes: the International Autoimmune Hepatitis Group (IAIHG) position statement on a controversial issue. *J Hepatol* 2011; **54**:374-85.
7. Lindor KD. Primary biliary cirrhosis. *Hepatology* 2009; **50**:291-308.
8. Kaplan MM, Gershwin ME. Primary biliary cirrhosis. *N Engl J Med* 2005; **353**:1261-73.
9. Metcalf JV, Mitchison HC, Palmer JM, Jones DE, Bassendine MF, James OF. Natural history of early primary biliary cirrhosis. *Lancet* 1996; **348**:1399-402.
10. Jeong HJ, Hahn EK, Kim E, Park CI. Hepatic amyloidosis: two case reports. *J Korean Med Sci* 1988. **3**:151-5.
11. Peters RA, Koukoulis G, Gimson A, Portmann B, Westaby D, Williams R. Primary amyloidosis and severe intrahepatic cholestatic jaundice. *Gut* 1994; **35**:1322-5.
12. Tafarel JR, Lemos LB, Oliveira PM, Lanzoni VP, Ferraz ML. Cutaneous amyloidosis associated with primary biliary cirrhosis. *Eur J Gastroenterol Hepatol* 2007; **19**:603-5.

.....★.....