



4-2007

Multiple Fractures Upper Body Fractures associated with Extradural Hematomas

Amit Agrawal

B.P. Koirala Institute of Health Sciences, Dharan, Nepal

Akshay Pratap

B.P. Koirala Institute of Health Sciences, Dharan, Nepal

Anand Kumar

B.P. Koirala Institute of Health Sciences, Dharan, Nepal

Amit Thapa

B.P. Koirala Institute of Health Sciences, Dharan, Nepal

Abhishek Sinha

B.P. Koirala Institute of Health Sciences, Dharan, Nepal

Follow this and additional works at: <https://ecommons.aku.edu/pjns>

 Part of the [Neurology Commons](#)

Recommended Citation

Agrawal, Amit; Pratap, Akshay; Kumar, Anand; Thapa, Amit; and Sinha, Abhishek (2007) "Multiple Fractures Upper Body Fractures associated with Extradural Hematomas," *Pakistan Journal of Neurological Sciences (PJNS)*: Vol. 2 : Iss. 1 , Article 4. Available at: <https://ecommons.aku.edu/pjns/vol2/iss1/4>

MULTIPLE FRACTURES UPPER BODY FRACTURES ASSOCIATED WITH EXTRADURAL HEMATOMAS

Amit Agrawal, Akshay Pratap, Anand Kumar, Amit Thapa and Abhishek Sinha

Department of Surgery, B.P. Koirala Institute of Health Sciences, Dharan, Nepal

Correspondence to: Dr. Agrawal, Assistant Professor of Neurosurgery, B.P. Koirala Institute of Health Sciences, Dharan, Nepal. Telephone: 977-25-525555 ext 2047; Fax: 977-25-520251. Email: dramitagrawal@gmail.com

Pak J Neurol Sci 2007; 2(1):11-13

ABSTRACT

All patients with deceleration or crushing injuries involving clavicular and upper-rib fractures must be suspected of having significant multiple organ system trauma, including intracranial trauma, and evaluated accordingly. This case illustrates the importance of careful examination in an individual with a history of being hit by multiple objects, and thus having a possibility of multiple injuries.

Multiple extradural hematomas,^{1,2,3} bilateral clavicle fracture,⁴ first rib fracture,^{5,6,7,8} and second rib fracture,⁹ either alone or in combination, are suggestive of significant and severe trauma. In the present case, the patient sustained multiple injuries due to multiple stones falling on him. Patients with such findings need careful and detailed examination.

CASE REPORT

This 47-year-old male presented when multiple stones fell on him while he was breaking stones in a quarry. He experienced transient loss of consciousness and chest pain. There was no history of vomiting, seizures, ear, nasal or oral bleed, or dyspnea. On examination, pulse rate was 88 per minute, blood pressure was 120/84 mmHg and

respiratory rate was 24 per minute. His chest and cardiac examination were normal, except for mild in-drawing of the intercostal muscles. There were no focal neurologic deficits. Local examination showed crepitus and tenderness over both clavicles and tenderness over both sides of the chest in the upper part. There was a lacerated wound (1 x 1 cm) over the right parietal region, with ecchymosis of the right eye (Figure 1). There were multiple abrasions over the right clavicular region, as well as both upper and the left lower limbs. Chest X-ray showed bilateral clavicle fractures, bilateral first rib fractures, and right second rib fracture (Figures 2 and 3). Cervical and dorsal spine X-rays were normal. Brain CT scan showed right basal temporal and right fronto-parietal extradural haematomas with mass effect and midline shift (Figures 4 and 5). The patient was treated successfully and did well.

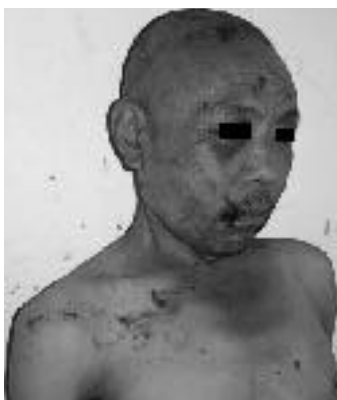

Figure 1: Photograph showing multiple abrasions on scalp and shoulder, and over the right clavicle.

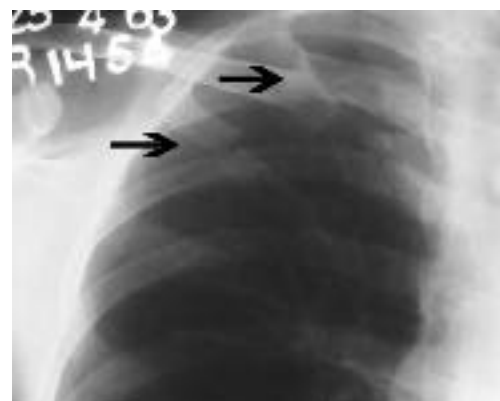

Figure 2: X-ray chest showing fractured right clavicle, and first and second rib (arrows).

DISCUSSION

Fractures of the first rib are very rare and bilateral fractures are even less common. Traumatic fractures usually involve not only the first rib but also the clavicle or scapula.^{5,10} First rib fractures are a harbinger of major trauma as considerable force is required to fracture the first rib, which is protected very well by soft tissue as well as the overlying clavicle and scapula.^{5,6,10} First rib fractures may be isolated or occur in association with other rib fractures and are usually located in an area of anatomical weakness (a shallow depression for the sub-clavian artery).⁷ The mechanism of fracture is either direct trauma to the shoulder (as in the present case) or a sudden violent contraction of juxtacostal muscles. It may even be a chance finding, without any history of trauma, and as such interpreted as a fatigue fracture.⁸

Fracture of the second rib is rare and only a few case reports are available.⁹ Bilaterally fractured clavicles usually result from direct trauma to both shoulders, as in the present case. These fractures heal well with non-operative treatment.⁴

The incidence of multiple extradural hematomas (EDH) has been reported in various studies ranging from 2-25%; these lesions are usually bilateral and presence at more than two sites is extremely rare.^{1,3} It has been

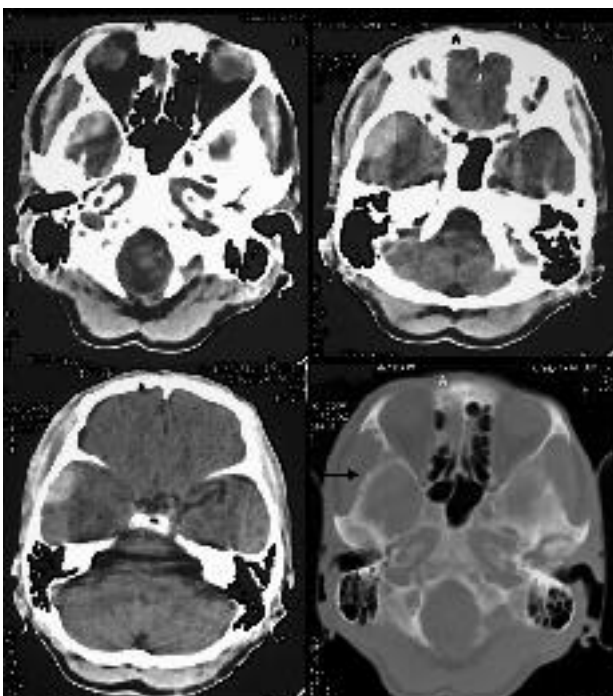


Figure 3: CT scan showing right basal temporal extradural hematoma with overlying fracture of squamous part of temporal bone (arrow).

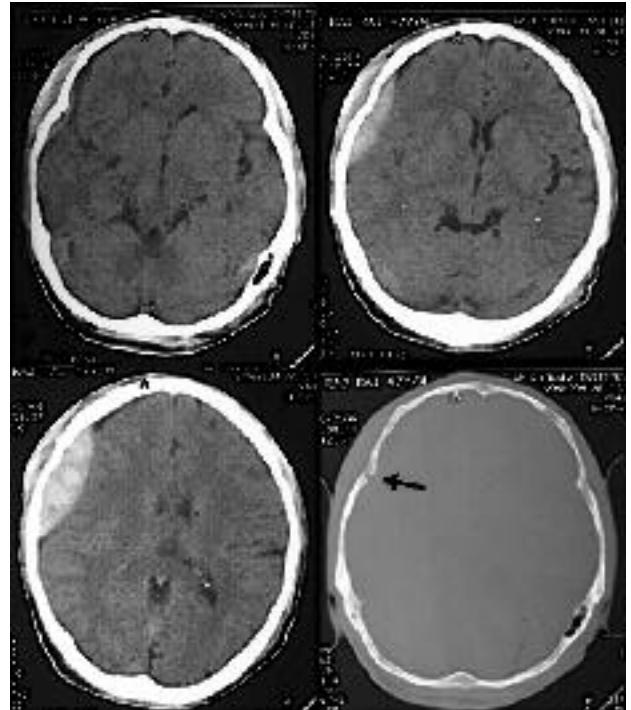


Figure 4: CT scan showing right fronto-parietal extradural hematoma with overlying fracture of sphenoid bone (arrow).

suggested that the force of impact to the head can produce bilateral hematomas, more predominant in the antero-posterior direction than from the lateral direction.^{11,12} In this way, the dura can be detached from two locations by a single directed force, and stripping of dura can occur at the site of impact by the skull bending inwards or outwards.¹¹ This can be further aggravated by the negative intracranial pressure found at the antipode of the compression force.¹³ These factors probably account for a higher frequency of EDH in the frontal region.¹ Indeed, the mechanism may be the same as in coup and contre-coup injuries.¹⁴ In the present case the causes of ipsilateral double extradural hematomas was multiple impacts due to falling stones (a conclusion supported by overlying skull fractures at both sides). Patients with double EDH have a lucid interval less frequently, have a lower Glasgow Coma Score, frequently lack lateralizing findings, and tend to deteriorate more often than individuals with unilateral hematomas.^{11,15}

All patients with deceleration or crushing injuries involving upper-rib fractures must be suspected of having significant multiple organ system trauma and evaluated accordingly.¹⁶ This case illustrates that in a person where there is a history of being hit by multiple objects, a possibility of multiple injuries must be considered.

REFERENCES

1. Huda MF, Mohanty S, Sharma V, et al. Double extradural haematoma: An analysis of 46 cases. *Neurol India* 2004; **52**:450-452.
2. Rivas JJ, Lobatto RD, Sarabia R, et al. Extradural haematoma: analysis of factors influencing the courses of 161 patients. *Neurosurgery* 1988; **23**:44-51.
3. Dharkar SR, Bhargava N. Bilateral epidural hematoma. *Acta Neurochir* 1991; **110**:29-31.
4. Sutherland AG, Knight DJ. Bilateral fractured clavicles--a pair of cases. *Acta Orthop Belg* 2000; **66**:306-7.
5. Dwivedi S, Varma A. Bilateral fracture of the first ribs. *J Trauma* 1983; 538-9.
6. Richardson JD, McElvein RB. First Rib Fracture: A Hallmark of Severe Trauma. *Ann Surg* 1975; **18**:251-254.
7. Albers JE, Rath RK, Glaser RS, et al. Severity of intrathoracic injuries associated with first rib fractures. *Ann Thorac Surg* 1982; **33**:614-18.
8. Lorentzen JE, Movin M. Fracture of the first rib. *Acta Orthop Scand.* 1976; **47**:632-4.
9. Jakubietz MG, Jakubietz RG, Gruenert JG, Langer M. Bilateral non-traumatic second rib fracture after bilateral first rib resection for TOS. *Thorax* 2005; **60**; 259-260.
10. Tsukada A, Uchiyama S, Toriumi H, et al. Nontraumatic bilateral first rib fractures. *Acta Orthop Belg* 1998; **64**:406-8.
11. Frank E, Berger TS, Tew JM Jr. Bilateral epidural hematomas. *Surg Neurol* 1982; **17**:218- 22.
12. Ramzan A, Wani A, Malik AH, Kirmani A, Wani MA. Acute Bilateral Extradural Hematomas. *Neurol India* 2002; **50**: 217-218.
13. Gurdjian ES. Recent advances in the study of mechanism of impact of injury of the head. A summary. *Clin Neurol* 1972; **11**:1-43.
14. Subrahmanian MV, Rajendra Prasad GB, Rao BD. Bilateral extradural hematoma. *Br J Surg* 1975; **62**: 397-400.
15. Rasmussen GL, Holme S. Bilateral epidural hematomas. *Ugeskr Laeger* 1991; **154**:203-4.
16. Poole Jr. GV, Myers RT. Morbidity and Mortality Rates in Major Blunt Trauma to the Upper Chest. *Ann Surg* 1981; **193**:70-75.