



12-2007

Vasculitic Neuropathy Secondary Topolyarteritis Nodosa in Association Withhepatitis B Antigenemia

Azra Zafar

Liaquat National Hospital

Farrukh Shohab Khan

Liaquat National Hospital

Syed Mehfooz Alam

Liaquat National Hospital

Feroza Saleem

Liaquat National Hospital

Follow this and additional works at: <https://ecommons.aku.edu/pjns>

 Part of the [Neurology Commons](#)

Recommended Citation

Zafar, Azra; Khan, Farrukh Shohab; Alam, Syed Mehfooz; and Saleem, Feroza (2007) "Vasculitic Neuropathy Secondary Topolyarteritis Nodosa in Association Withhepatitis B Antigenemia," *Pakistan Journal of Neurological Sciences (PJNS)*: Vol. 2 : Iss. 4 , Article 6.

Available at: <https://ecommons.aku.edu/pjns/vol2/iss4/6>

VASCULITIC NEUROPATHY SECONDARY TO POLYARTERITIS NODOSA IN ASSOCIATION WITH HEPATITIS B ANTIGENEMIA

Azra Zafar,¹ Farrukh Shohab Khan,¹ Syed Mehfooz Alam² and Feroza Saleem¹

Departments of ¹Neurology and ²Medicine, Liaquat National Hospital, Karachi, Pakistan

Correspondence to: Dr. Zafar, Senior Registrar, Liaquat National Hospital, Stadium Road, Karachi, Pakistan. Tel. +92-300-260-1653. Email: thisizazra@yahoo.com

Pak J Neurol Sci 2007; 2(4): 220-22

ABSTRACT

Polyarteritis nodosa (PAN) causes transmural necrotizing inflammation of small- or medium-sized muscular arteries. PAN is also observed as a complication of hepatitis B, hepatitis C, and HIV infection. Disease manifestations are diverse and complex; however, peripheral neuropathy is one of the commonest presenting features. We describe a case of vasculitic neuropathy in a patient with PAN and discuss the association with hepatitis B infection.

CASE REPORT

A 40-year-old man with no known co-morbidities presented with a history of numbness and weakness of both hands and feet for 3 months, along with difficulty in walking and left foot drop for 2 weeks. On systemic inquiry, he was found to have low grade fever, polyarthralgia, skin rash, weight loss and anorexia. He was married and had four children. He was a salesman by profession and had been living in the Middle East for the last 16 years. Sexual history was positive for extramarital contacts.

On examination, he was a middle-aged cachectic male with blood pressure of 150/90 mmHg and pulse of 80 per minute. He was afebrile. Peripheral cyanosis and erythematous macular rashes were noted on both lower extremities. Higher mental functions, cranial nerves, and cerebellar functions were intact. He had significant wasting of the small muscles in both hands. Power was 3/5 in intrinsic hand muscles bilaterally, 4+/5 in the rest of the upper limbs, 1/5 in left ankle dorsiflexion, 3/5 in right ankle dorsiflexion, and 4+/5 in the rest of the lower limb musculature. The left ankle deep-tendon reflex was absent, the right ankle reflex was diminished, and the other deep-tendon reflexes were normal. Sensory loss in a glove-and-stocking distribution was detected in all sensory modalities. He walked with a slapping, high-stepping gait.

Laboratory evaluation showed normocytic normochromic anemia. ESR was 65 mm. Chest X-Ray and urinalysis were

normal. Alanine transaminase was raised at 46 mg/dl. Serology was positive for hepatitis B surface antigen but negative for anti-HCV as well as anti-HIV I and II. Assays for antinuclear antibodies (ANA) and anti double-stranded DNA were also negative. Electromyography and nerve conduction studies showed an asymmetric primarily axonal sensorimotor polyneuropathy. Sural nerve biopsy revealed transmural inflammation and necrosis of medium-sized blood vessels, suggestive of active necrotizing vasculitis (Figure 1).

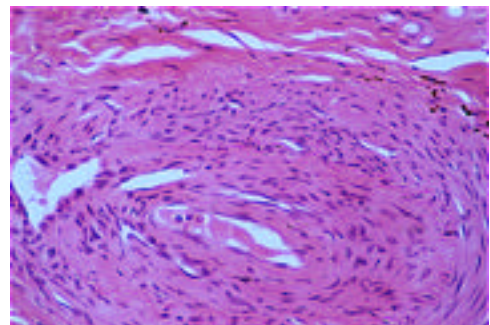


Figure 1. Sural nerve biopsy showing transmural necrotizing inflammation

A diagnosis of vasculitic neuropathy secondary to polyarteritis nodosa in association with hepatitis B antigenemia was made. Our patient fulfilled diagnostic criteria for PAN described by the American college of Rheumatology in 1990.⁹

Treatment was begun with intravenous methyl prednisolone (1 g once daily for 3 days), followed by oral prednisone. He was also started on oral azathioprine and was referred to gastroenterology for management of hepatitis B infection.

DISCUSSION

Vasculitis is inflammation in the vessel wall. The systemic vasculitides represent a highly heterogeneous group of clinicopathological entities. Although vasculitis has many causes, it produces a limited number of histological patterns of vascular inflammation. Clinical expression depends on the site, type and size of vessel involved. Vessels of any type in any organ can be affected, which is reflected in the diversity of signs and symptoms.

In terms of clinical course, the systemic vasculitides range from benign, locally restricted processes (for e.g., cutaneous leukocytoclastic angiitis) to systemic vasculitis leading to life-threatening conditions, such as pulmonary-renal syndrome in antineutrophil cytoplasmic antibody (ANCA)-associated vasculitis.¹

Polyarteritis nodosa or periarteritis nodosa was first described by Kussmaul and Maier in 1866. A focal segmental necrotizing vasculitis of small- and medium-sized arteries, it affects in order of decreasing frequency the peripheral nerves, muscles, joints, skin, kidney, gastrointestinal tract, heart and eyes, and manifests itself by weight loss, fever, asthenia, hypertension, and biological signs of inflammation such as anemia, leukocytosis, thrombocytosis, and increased ESR.^{2,3}

In patients with systemic necrotizing vasculitis, peripheral neuropathy has been well documented.^{4,5} A mononeuropathy or mononeuropathy multiplex as a characteristic feature of ischemic nerve damage has been reported in the earliest papers.⁴ More extensive neuropathy and symmetric polyneuropathy have also been emphasized.⁵ A detailed history, physical examination and focused laboratory investigations are vital in diagnosing vasculitic disorders. Laboratory assessment for ANCA, ANA, complement, cryoglobulins, fecal blood, antibodies to hepatitis B and C, rheumatoid factor, azotemia, hematuria and proteinuria is helpful.⁶

Sergent et al presented substantial evidence which indicated that at least one subset of PAN patients experienced systemic vasculitis as a result of hepatitis B virus-associated immune complex disease.⁷ Guillevin et al in France in a 1981-1992 study also reported that 25-30% of PAN patients are associated with hepatitis B, based on HBsAg positivity.⁸ In 1990, the American

College of Rheumatology proposed a set of PAN classification criteria, which included the presence of HBsAg or HBsAb in serum as part of the criteria.⁹

The definitive diagnosis of systemic vasculitis, however, is dependent on the demonstration of vascular involvement by either biopsy or angiography. Biopsy specimens should be obtained only from clinically involved accessible tissue.¹

Prednisolone-based treatment is well known in PAN. Sometimes a cytotoxic agent and plasmapheresis are added.⁸ Treatment of underlying Hepatitis B infection has also been shown to cure the disease.¹⁰

CONCLUSION

Polyarteritis nodosa is a recognized systemic complication of hepatitis B infection and patients can have serious extrahepatic manifestations even with minimal to moderate hepatic involvement. Nerve biopsy is an important diagnostic tool in confirmation of vasculitic neuropathy.

REFERENCES

1. Gross WL, Trabandt A, Reinhold-Keller E. Diagnosis and evaluation of vasculitis. *Rheumatology* 2000; **39**: 245-52.
2. Kussmaul A, Maier R. ueber eine bisher nicht beschriebene eigenthuemliche Arterienkrankung (Periarteritis nodosa), die mit Morbus Brightii und rapid fortschreitender allgemeiner Muskellaehmung einhergeht. *Deutsch Arch Klin Med* 1866; **1**: 484-518.
3. Lhote F, Guillevin L. Polyarteritis nodosa, microscopic polyangiitis, and Churg Strauss syndrome: clinical aspects and treatment. *Rheum Dis Clin North Am* 1991; **21**: 911-47.
4. Bleehen SS, Lovelace RE, Cotton RE. Mononeuritis multiplex in polyarteritis nodosa. *Q J Med* 1963; **32**: 193-209.
5. Kissel JT, Slivka AP, Warmolts JR, Mendell JR. The clinical spectrum of necrotizing angiopathy of the peripheral nervous system. *Ann Neurol* 1985; **18**: 251-7.
6. Jennette JC, Falk RJ. Small vessel vasculitis. *N Engl J Med* 1997; **337**: 1512-23.
7. Sergent JS, Lockshin MD, Christian CL, Gocke DJ. Vasculitis with hepatitis B antigenemia: long-term observation in nine patients. *Medicine (Baltimore)* 1976; **55**: 1-18.

-
8. Guillevin L, Lhote F, Cohen P, Sauvaget F, Jarrousse B, Lortholary O, et al. Polyarteritis nodosa related to hepatitis B virus. A prospective study with long-term observation of 41 patients. *Medicine* 1995; **74**: 238-53.
 9. Lightfoot RW, Michel BA, Bloch DA, Hunder GG, Zvaifler NJ, Mc Shane DJ, et al. The American College of Rheumatology 1990 criteria for the classification of polyarteritis nodosa. *Arthritis Rheum* 1990; **33**: 1088-93.
 10. Ghoucair J, Hajj G, Abi Karam G. A case of PAN with positive Hbs Ag cured by immunosuppressive and antiviral therapies: a case report. *J Med Liban* 2007; **55**: 50-2.