



THE AGA KHAN UNIVERSITY

eCommons@AKU

Department of Pathology and Laboratory Medicine

Medical College, Pakistan

June 1994

Immunohistochemical Estrogen receptor determination in human Breast carcinoma: correlation with histologic differentiation and age of the patients

Shahid Pervez

Aga Khan University, shahid.pervez@aku.edu

S. Shaikh

Aga Khan University

F. Aijaz

Aga Khan University

S. A. Aziz

Aga Khan University

M. Naqvi

Aga Khan University

Follow this and additional works at: <http://ecommons.aku.edu/>

[See next page for additional authors](#)
[pakistan_fhs_mc_pathol_microbiol](#)

 Part of the [Oncology Commons](#), [Pathological Conditions, Signs and Symptoms Commons](#), [Pathology Commons](#), and the [Women's Health Commons](#)

Recommended Citation

Pervez, S., Shaikh, S., Aijaz, F., Aziz, S. A., Naqvi, M., Hasan, S. H. (1994). Immunohistochemical Estrogen receptor determination in human Breast carcinoma: correlation with histologic differentiation and age of the patients. *Journal of Pakistan Medical Association*, 44(6), 133-136.

Available at: http://ecommons.aku.edu/pakistan_fhs_mc_pathol_microbiol/312

Authors

Shahid Pervez, S. Shaikh, F. Aijaz, S. A. Aziz, M. Naqvi, and Sheema H. Hasan

Immunohistochemical Estrogen Receptor Determination in Human Breast Carcinoma: Correlation with Histologic Differentiation and Age of the Patients

Pages with reference to book, From 133 To 136

S. Pervez, H. Shaikh, F. Aijaz, S.A. Aziz, M. Naqvi, Sheema H. Hasan (Department of Pathology, The Aga Khan University Hospital, Stadium Road, Karachi.)

Abstract

An immunohistochemical assay for the measurement of estrogen receptor (ER) has been evaluated on 290 consecutive human breast biopsy and mastectomy specimens in the year 1992 at The Aga Khan University Hospital laboratories. Immunohistochemical localization of estrogen receptor on frozen/paraffin section was scored in a semi-quantitative fashion incorporating both the intensity and the distribution of specific staining. Histologic grading of the tumour was performed according to Bloom's method. In this study, 21% of the tumours were estrogen receptor negative, 15% were weak positive, 25% intermediate positive and 39% strong positive. Fifty percent of the well differentiated tumours showed strong ER positivity against 27% of the poorly differentiated tumours. Seventy eight percent of all negative estrogen receptors were in patients younger than 50 years of age (pre-menopausal group), while 52% of strong estrogen receptor positivity was observed in patients older than 50 years (post- menopausal). This study demonstrates the value of immunohistochemical method to determine the ER status in patients with advanced breast cancer (JPMA 44:133, 1994).

Introduction

The clinical significance of estrogen receptor assays is well recognized. There is a general agreement that approximately half of the women whose tumours have detectable estrogen receptor (ER) will obtain objective remission from some form of endocrine therapy¹. This number increases to three quarters when progesterone receptor (PR), an estrogen induced protein is included¹. Besides this, a significantly prolonged overall survival among patients with ER-positive tumours has been reported². In these patients, disease free interval (DFI) is prolonged not because ER-positive patients responded better to adjuvant hormonal treatment, but because ER-positive and ER-negative tumours have different biological behaviour. Knowledge of estrogen receptor status is therefore, of both therapeutic and prognostic importance. There are numerous theoretical and practical advantages for the demonstration of estrogen and progesterone receptors by immunohistochemical (IHC) means over cytosol based biochemical assays^{3,4}. Breast cancers are frequently heterogenous both morphologically and in terms of biological behaviour. This is also true for estrogen receptor⁵. A major disadvantage of tissue homogenates used for biochemical ER measurements is that it cannot assess intratumoural heterogeneity. The development of monoclonal antibodies against the ER proteins have been shown to be applicable to the demonstration of ER by IHC method⁶. This technique offers an advantage of a reproducible, easy to interpret staining product which may be scored in a semiquantitative fashion. This study documents the value of IHC method to predict the prognosis and response to hormonal treatment in patients with advanced breast cancer.

Materials and Method

Patient Population

This study group consisted of 290 consecutive human breast biopsy and mastectomy specimens received for ER evaluation in the year 1992 at The Aga Khan University Hospital, Department of Pathology, Karachi. Age of the patients ranged from 22-85 years (median 46 years). The most common type of tumour was infiltrating duct carcinoma (Table I).

Table I. Patient characteristics.

Age (yrs).	Number	%
<50	158	54.5
50-59	68	23.5
60-69	45	15.5
≥70	19	6.5
Histologic type:		
Infiltrating duct Ca	260	90.0
Lobular Ca	15	5.0
Other sub-types	15	5.0
Primary surgical treatment:		
Biopsy and tumourectomy	86	29.8
Simple mastectomy	28	9.6
Mastectomy with axillary dissection	176	60.6

Immunohistochemical procedures

Primary antibodies: Monoclonal antibody directed against human ER protein (rat monoclonal, Abbott Laboratories) was used at recommended dilution on P.S. In some cases where the tumour was already fixed in formalin, anti-estradiol antibody (Signet Rabbit AB Laboratories Inc.) was used. 3-5 um thick frozen sections were cut and mounted on gelatin coated slides. The slides were immediately immersed in 4% formaldehyde-phosphate-buffered saline for 10 minutes at room temperature. This was followed by 3-5 minutes immersion in 100% methanol and 1-3 minutes in acetone at -4°C. For paraffin embedded tumours, 3 um sections were cut and mounted on coated slides. Sections were stained by 3 step PAP (peroxidase anti-peroxidase) technique. Positive and negative controls were included with each panel.

Histological grading of tumour

Histological grading of the tumours (infiltrating ductal carcinomas) was performed according to the method described by Bloom and Richardson⁷ taking into consideration 3 criteria, i.e., tubule formation, nuclear pleomorphism and mitosis, each given a point range from 1-3. Grade is allocated as follows: 3-5 points (grade I, well differentiated, 6-7 points (grade II, moderately differentiated) and 8-9 points

(poorly differentiated).

Semi-quantitative evaluation of immunocytochemical staining

The immunohistochemical localization of ER was scored in a semi- quantitative fashion incorporating both the intensity and the distribution of specific staining as described by Kenneth S. McCarty, Jr. et al.^{6,8}. The evaluations were recorded as percentages of positively stained tumour cells in each of five intensity categories denoted as 0 (no staining), 1 + (weak but detectable), 2 + (mildly distinct), 3 + (moderately distinct) and 4 + (strong). For each tissue, a value designated as HSCORE was derived by summing the percentages of cells staining at each intensity multiplied by the weighted intensity of staining. An HSCORE of <74 was established as negative, between 75-99 as weak positive, 100-119 as intermediate positive, while 120 and more as strong positive. An example from one of the case reports is given below:

Degree of positivity		Percent (%) cells
0	X	35 = 0
1	X	30 = 30
2	X	25 = 50
3	X	10 = 30
4	X	0 = 0
Total score = 110 (intermediate positive for estrogen receptor).		

Results

i) Patterns of staining

Immunohistochemical evaluation using monoclonal antibody to estrogen receptor protein on fresh/frozen tumour sections revealed specific staining localized to nuclei of target cells only (Figure 1).

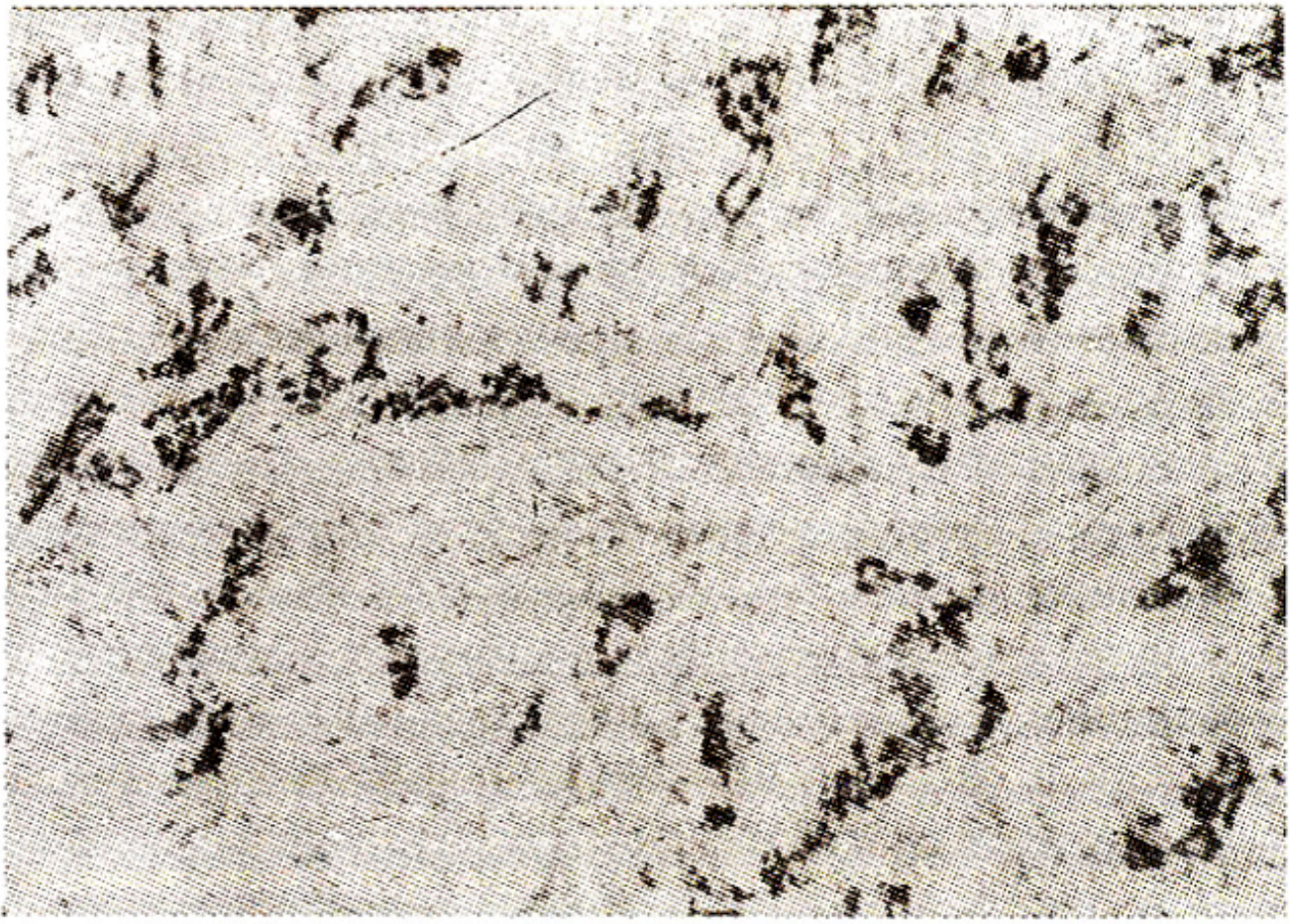


Figure 1(a). Immunohistochemical localization of estrogen receptor (ER) using a monoclonal antibody against ER in an infiltrating ductal carcinoma breast. Note specific staining localized to nuclei of target cells only (Mag x 100).

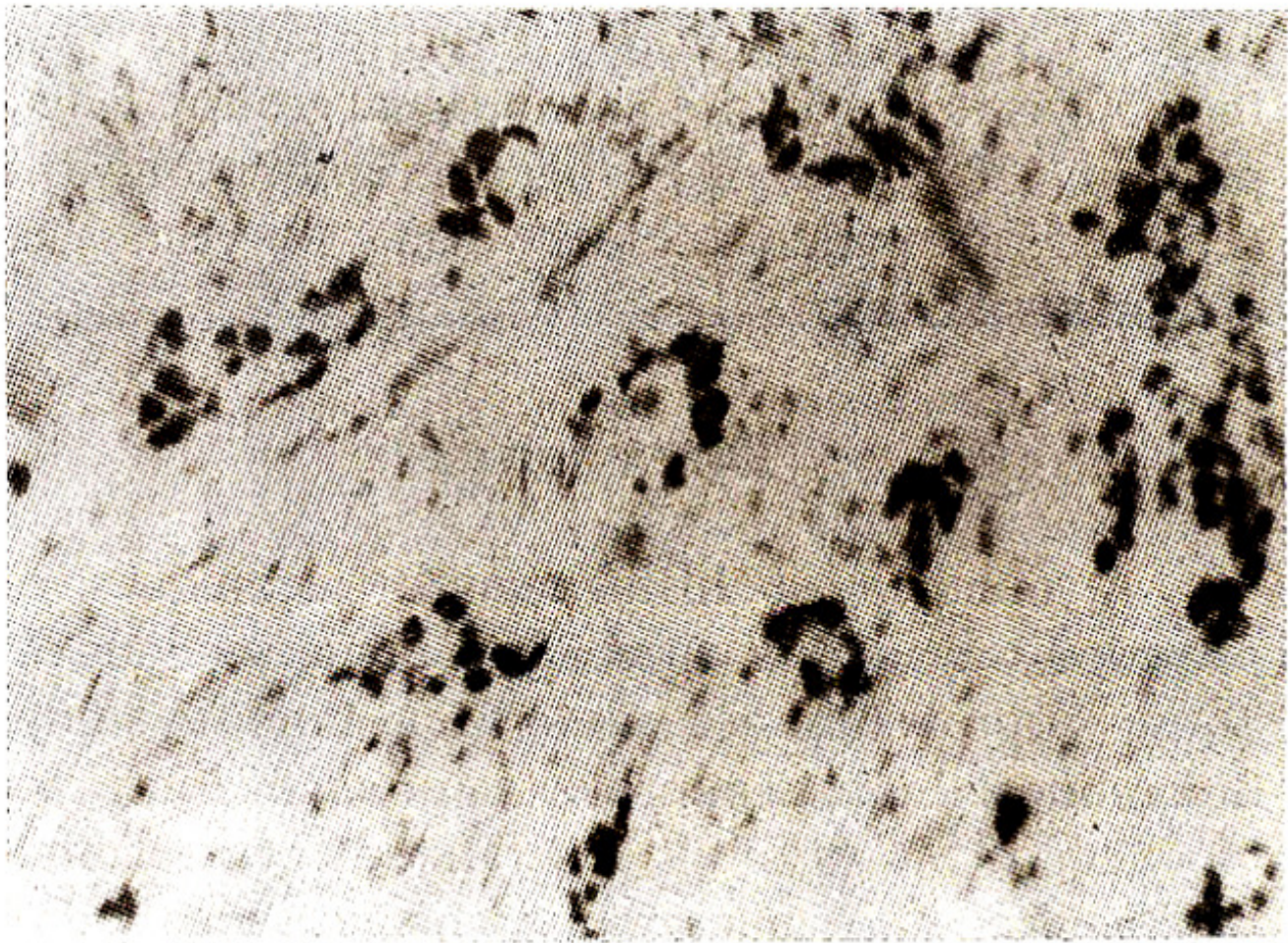


Figure 1 (b). Higher magnification of (a) x 400.

No cytoplasmic staining was seen. In contrast two different staining patterns were observed in formalin fixed/paraffin embedded tumour sections using anti-estradiol antibody. The first pattern consisted of positive reaction products within the cytoplasm in most carcinoma cells. The second pattern demonstrated positive reaction product both in the nucleus and cytoplasm. No staining was observed in paraffin embedded tissues using anti-ER monoclonal antibody even with trypsin digestion.

ii) Histologic grade and estrogen receptor status

In this study, 14% of the tumours (infiltrative duct carcinoma) were graded as grade 1 (well differentiated), 48% as grade 2 (moderately differentiated) and 38% as grade 3 (poorly differentiated). Twenty-one percent (21%) of the total tumours showed negative estrogen receptor status. In positive group, 15% of the tumours were weak positive, 25% intermediate positive and 39% strong positive for ER. 50% of the well differentiated tumours showed strong ER positivity against 27% of the poorly differentiated tumours in positive group (Table II).

Table II. Histologic grade and estrogen receptor (ER) status (infiltrating duct carcinoma breast).

ER status	Histologic grade		
	I	II	III
ER weak positive	6 (20%)	27 (28%)	31 (40%)
ER intermediate positive	9 (30%)	34 (35%)	26 (33%)
ER strong positive	15 (50%)	36 (37%)	21 (27%)
Total	30	97	78

By Chi-square statistical analysis (grade I versus grade III), results are statistically significant, i.e., $P < 0.05$ ($P = 0.023$).

By using Chi-square statistical analysis (grade 1 versus grade 3), results are statistically significant, i.e., $P < 0.05$ (0.023).

iii) Patient age and estrogen receptor status

A significant correlation also exists between ER status and age at the time of diagnosis with 78% of all negative estrogen receptors reported in patients younger than 50 years of age (pre-menopausal group). Fifty-two percent (52%) of strong estrogen receptor positivity was reported in patients older than 50 years (post-menopausal group).

Discussion

A number of histochemical techniques have provided ways to visualize ER in tissue sections^{2-4,6,8}. These approaches are underlying intense study to determine if they can improve the predictive accuracy of biochemical assays for ER. Several studies correlating the biochemical and immunohistochemical methods appeared in literature indicates that a high degree of specificity and sensitivity for ER can be attained by IHC approach with MABs to ER^{6,9}. At the present time, one indisputable application of IHC approach is the very small neoplasm in which the amount of tumour available is inadequate for cytosol-based biochemical methods. Another area of practical use of this method is when a small carcinoma is detected only after the tissue has been processed and embedded in paraffin^{2,10}. One drawback of IHC over biochemical method is that the former is at best semi-quantitative. However, several methods are being employed to quantitate the results of IHC for ER in attempts to facilitate comparison with the cytosol technique. These range from estimating the percentage of neoplastic cell nuclei immunostained to the use of computerized cell analyses system. There is no doubt, however, that the histochemical results have enlarged the pathologists' knowledge of ER distribution within the tumour. Some tumours are composed of both ER positive and ER- negative cells. Observations about heterogeneity of staining enables to improve predictive accuracy in patients whose ER positive tumours may contain significant population of hormone unresponsive cells. A certain number of false positive and false negative results may occur. Anti-factual heterogeneity of immunostaining is not uncommon in formalin fixed tissues. In some cases this may pose problems. Although most positive cases are easily discernible, there are occasional examples of ambiguous results which may benefit from a system which more clearly defines a quantitative threshold more particularly if backed up by clinical response data. The false positives are viewed with somewhat less concern than the false negatives. This is because the modern hormonal therapy, e.g., tamoxifen is relatively free of side effects and the lack of response to therapy becomes

apparent within a few weeks, allowing the clinician to move onto other modalities. The frequency of false positive results may be reduced if hormonal treatment can be reserved for the sub-set of patients with tumours containing both estrogen and progesterone receptors. Evidence from animal models suggests that PR is under the control of ER. Presence of PR indicates that the ER mechanism is not only present but also functional. Because ER-ICA detects ER by its antigenicity, it does not assure that the receptors are functional. False negative results represent patients who could have received tangible benefits from benign therapy. Sampling and handling errors are important reasons for false negativity, while analytical errors can be minimized by performing parallel assays on control material. It has been found that high levels of plasma estrogen may induce false negative results¹¹ because the endogenous estrogen occupies the binding receptor protein. This effect might be diminished by performing biopsies during menses. Biochemical methods are also not foolproof and on occasion ER positivity may in fact be an artefact because of ER presence in adjacent benign tissue. This technique, using anti-ER monoclonal antibodies on fresh/frozen tumour sections demonstrates nuclear localization of the type I, high affinity receptor without convincing evidence for cytoplasmic receptor staining. This finding contrasts with cytoplasmic localization in histochemical methods employing anti-estrogen (anti-estradio) antibodies. These antibodies probably detect type II and III estrogen binding sites rather than the type I high affinity receptor¹². In spite of these problems/criticisms there have been several reports of a good agreement between qualitative results obtained by histochemical method using anti-estradio antibody and biochemical methods^{13,14}. This, probably represents/supports the theory of two step interaction mechanism of the receptor protein. Namely, the steroid hormone first binds with the cytoplasmic receptor protein to form estrogen receptor complex and with subsequent transformation of the receptor protein, the complex translocates into the nucleus to bind with the nuclear chromatin¹⁵. A significantly prolonged overall survival among patients with ER-positive tumours has been reported^{9,16,17}. Disease free interval (DFI) is prolonged in these patients not because ER-positive patients responded better to adjuvant hormonal treatment but because ER positive and ER negative tumours have different biologic properties, e.g., proliferation rate (study in progress in our department using Ki-67 MAb). Several studies assessing proliferation index have shown an association between ER content and tumour differentiation¹⁸⁻²⁰. Meyer et al.¹⁸ found a significant correlation between the low thymidine labelling index and increased ER levels in breast cancer cell. Highly proliferative, poorly differentiated tumour cells showed low ER levels. These observations have been confirmed by Silva et al²⁰ who also found consecutive decrements of ER and PR levels as measure of differentiation of tumour with grade I (well differentiated) having the highest and grade III (poorly differentiated) having the lowest ER and PR levels. The results in our study also indicate a correlation between the level of ER and the degree of differentiation. However, the number of well differentiated tumours in this study represented approximately 1/8th of the total cases and therefore, may not be truly representative. This paper extends the observation that the ER-ICA status relates to patient's age. In the current study, high levels of ER expression were most often observed in patients more than 50 years of age, a result in keeping with the known influence of age on receptor levels^{21,22} - The low level of ER in pre-menopausal patients maybe explained by the higher levels of circulating estrogens with decreased synthesis of ER protein as a result of negative feedback. A major outcome of this study is that about 55% of the population on which ER was evaluated was under 50 years of age. This is in striking contrast to western studies where majority population belonged to elderly group with median age of 67 years² in one study. The data presented in this prospective study show that immunohistochemical localization of ER provides valuable information complementary to that obtained with standard biochemical assays.

Acknowledgement

We are extremely grateful to Mrs. Amina Anwerali for her secretarial help.

References

1. deSombre, E.R. Steroid receptors in breast cancer. In R.W. McDivitt, H.A. Obermsn, L Ozello and N. Kaufman, eds. *The breast*. Baltimore, Williams and Wilkins, pp. 149-174.
2. Anderson, J. and Poulsen, H.S. Immunohistochemical oestrogens receptor determination in paraffin-embedded tissue. Prediction of response to hormonal treatment in advanced breast cancer. *Cancer*, 1989; 64:1901-8.
3. Esteban, J.M., Ksndsraft, P.L, Mehta, P., et al Improvement of the quantification of oestrogen and progesterone receptors in paraffin embedded tumour by image analysis. *Am.J.Clin.Pathol.*, 1993;99:32-8.
4. King, W., DeSombre, ER., Jensen, By., et al. Comparison of immunocytochemical and steroid-binding assays for oestrogen receptor in human breast tumours. *Cancer Res.*, 1985;45:293-304.
5. Davis, B.W., Zsvs, DL, Locher, OW., et al. Receptor heterogeneity of human breast cancer as measured by multiple intratumoural assays of oestrogen and progesterone receptor. *Bur.J.Cancer Clin.Oneol.*, 1984;20:375-82.
6. McCarty, KS., Miller, US., Edwin, B.C., et al. Oestrogen receptor analyses. Correlation of biochemical and immunohistochemical methods using monoclonal anti-receptor antibodies. *Arch. Pathol. Lab. Med.*, 1985;109:716-21.
7. Bloom, H.J.O. and Richardson, W.W. Histological grading and prognosis in breast cancer. *Br.J. Cancer*, 1957;11:359-77.
8. McCarty, KS., Szabo, B., Flowers, J.L, et al. Use of monoclonal anti-estrogen receptor antibody in the immunohistochemical evaluation of human tumours. *Cancer Res. (Suppl)*, 1986;46:4244S-48S.
9. Teach, M., Shswwa, A. and Henderson, R. Immunohistochemical determination of oestrogen and progesterone receptor status in breast cancer *Am.J.Clin.Psthol.*, 1993;99:8-12.
10. Shintsku, P. and Said, J.W. Detection of oestrogen receptors with monoclonal antibodies in routinely processed formalin-fixed paraffin sections of breast carcinoma, use of D Nsse pretreatment to enhance sensitivity of the reaction. *Am.J.Clin.Pathol.*, 1987;87:161-67.
11. Oxley. D.K. Steroid receptor assays in breast cancer. Vol. 1. New Jersey, CPEC., 1982, pp. 1-7.
12. Walker, R.A. The localization of receptors and binding sites with reference to steroids. In *immunocytochemistry, modern methods and applications*. 2nd ed. Van Noorden, Julia M. Polak and Susan; 1986.
13. Walker, R.A, Cove, D.H. and Howell, A. Immunohistochemical detection of oestrogen receptor in human breast carcinoma. *Lancet*, 1980;1:171-73.
14. Pertshuk, L.P., Gaetjen, D.O.E., Carter, A.C., et al. An improved histochemical method for detection of oestrogen receptors in mammary cancer. *Am.J.Clin.Pathol.*, 1979;71:504-8.
15. Jensen, E.V., Suzuki, T., Kawshims, T., et al. A two-step mechanism for the interaction of estradiol with rat uterus. *Proc. Natl. Acad. Sci. USA.*, 1968;59:632-38.
16. Thorpe, SM., Rose, C., Rasmussen, B.B., et al. Steroid hormone receptors as prognostic indicators in primary breast cancer. *Breast Cancer Res. Treat*, 1986; 7 (Suppl):91-8.
17. DeSombre, ER., Thorpe, SM., Rose, C., et al. Prognostic usefulness of oestrogen receptor immunocytochemical assays for human breast cancer. *Cancer Res.*, 1986;40: (Suppl) 4256S-64S.
18. Meyer, S.S., Rao, B.R., Stevens, S.C. and White, W.L., Low incidence of oestrogen receptor in breast carcinomas with rapid rates of cellular replication. *Cancer*, 1977;40:2290-98.
19. Mohammed, R.H., Lskstva, Di., Haus, B., et al. Oestrogen and progesterone receptors in human breast cancer: correlation with histologic subtype and degree of differentiation. *Cancer*,

1986;58:1076-81.

20. Silvs, J.S., Cox, CE., Well, S.A., et st Biochemical correlates of morphologic differentiation in human bresstcsneer. *Surgery*, 1982;92:443-49.

21. Terenius, U, Johansson, H., Rimsten, A., etat Malignant and benign human mammsry disease: oestrogen binding in relation to clinical dats. *Cancer*, 1974;33:1364-68.

22. Oriffiths, K, Nicholson, Ri., Bismey, RW., et al. Oestrogen receptor determinations: studies in relation to rapidly progressive carcinoma of the breast In: V.C. Jordan (ed).,strogen/anti-oestrogen action and breast cancer therapy. W.L Madison, The University of Wisconsin Press, 1986,pp.325-40.