



THE AGA KHAN UNIVERSITY

eCommons@AKU

Section of Neurosurgery

Department of Surgery

6-2020

Permanent pre-operative cerebrospinal fluid diversion in paediatric patients with posterior fossa tumours

Ummey Hani

Saqib Kamran Bakhshi

Muhammad Shahzad Shamim

Follow this and additional works at: https://ecommons.aku.edu/pakistan_fhs_mc_surg_neurosurg



Part of the [Neurology Commons](#), [Neurosurgery Commons](#), [Oncology Commons](#), and the [Surgery Commons](#)

Permanent pre-operative cerebrospinal fluid diversion in paediatric patients with posterior fossa tumours

Hani Tariq, Saqib Bakhshi, Muhammad Shahzad Shamim

Abstract

Management options for obstructive hydrocephalus in children with posterior fossa tumours has been debated upon throughout the course of neurosurgical practice. Permanent pre-operative CSF diversion via ventricular shunts or endoscopic third ventriculostomy have been employed to prevent the possible persistence of hydrocephalus after tumour removal, but is considered unnecessary and even dangerous amongst a large group of neurosurgeons. In this paper, we have reviewed the literature for the merits and demerits of pre-operative permanent CSF diversion in paediatric patients presenting with posterior fossa tumours.

Keywords: Posterior fossa tumor, Ventriculoperitoneal shunt, Endoscopic third ventriculostomy, Hydrocephalus.

Introduction

Posterior Fossa Tumours (PFTs) are the commonest paediatric intracranial neoplasms and typically present with vomiting, cerebellar signs, or more commonly, with obstructive hydrocephalus due to their proximity to the fourth ventricle, and hence, the obstruction of cerebrospinal fluid (CSF) pathways.¹ Although most surgeons would use some form of temporary CSF diversion at the time of surgery to assist in the procedure, the use of permanent pre-operative diversion has been debated.² This is because in up to two-thirds of patients once the tumour is resected and the CSF pathways open up, a permanent CSF diversion is not required. Despite this, in earlier literature, pre-resection permanent CSF diversion has been advocated, commonly with the use of ventricular shunts.^{1,2} This not only subjects a substantial number of patients to a procedure they would not otherwise require, but also predisposes them to the theoretical risk of seeding the peritoneum with tumour cells.^{3,4} A better alternate is either temporary CSF diversion in the form of external ventricular drainage (EVD) or using a pre-resection endoscopic third ventriculostomy (ETV), that has recently gained

popularity, and using permanent diversion only for patients that clearly have hydrocephalus despite surgical removal of tumour.^{1,2}

Review of Evidence

From a historical standpoint, even temporary CSF diversion was not widely recognized until a few decades ago. Albright et al., reviewed the data of 86 patients with PFTs at their center of which 39 underwent a pre-operative CSF diversion procedure, and the rest did not. They concluded that CSF shunting significantly decreased the morbidity and mortality associated with subsequent tumour removal. Of 12 patients with EVDs and 27 with CSF shunts, significantly better post-operative outcomes were seen with patients in the latter group. Operative mortality without pre-operative CSF diversion was 12.8%, compared to 3.7% of those in the diversion group.⁵ This literature is more than 40 years old and clearly, we have recognized the importance of a relaxed brain for safe neurosurgery. Nowadays, almost every patient with pre-operative hydrocephalus undergoes some form of CSF diversion. Twenty years later, Taylor et al., reviewed 287 patients presenting with PFTs at their center and of the 75 patients who underwent a pre-operative CSF drainage procedure, 33 had EVDs, and 42 patients had shunts. Twenty six patients in the former group had persistent hydrocephalus post-tumour resection surgery and required permanent shunting. However, infection, shunt blockage and over-drainage were seen in 2% and 7% of the cases with pre-operative shunting.⁶

On the other hand, Goel et al., reviewed the data of 59 PFT patients with evidence of increased ICP presenting at their center and concluded that pre-resection CSF diversion procedures were not always indicated. Twenty six patients underwent pre-operative shunt surgeries and one patient required a post-operative shunt. Complications were seen in 15 patients, with 5 developing shunt infections, 2 developing shunt blockage warranting revision surgery, and 2 patients developing post-operative tension pneumocephalus, requiring an additional burr-hole; a rather unusual statistic. The author also noticed increased difficulty in tumour removal due to the proximity of tumour to the

.....
Aga Khan University Hospital, Karachi.

Correspondence: Muhammad Shahzad Shamim.

Email: shahzad.shamim@aku.edu

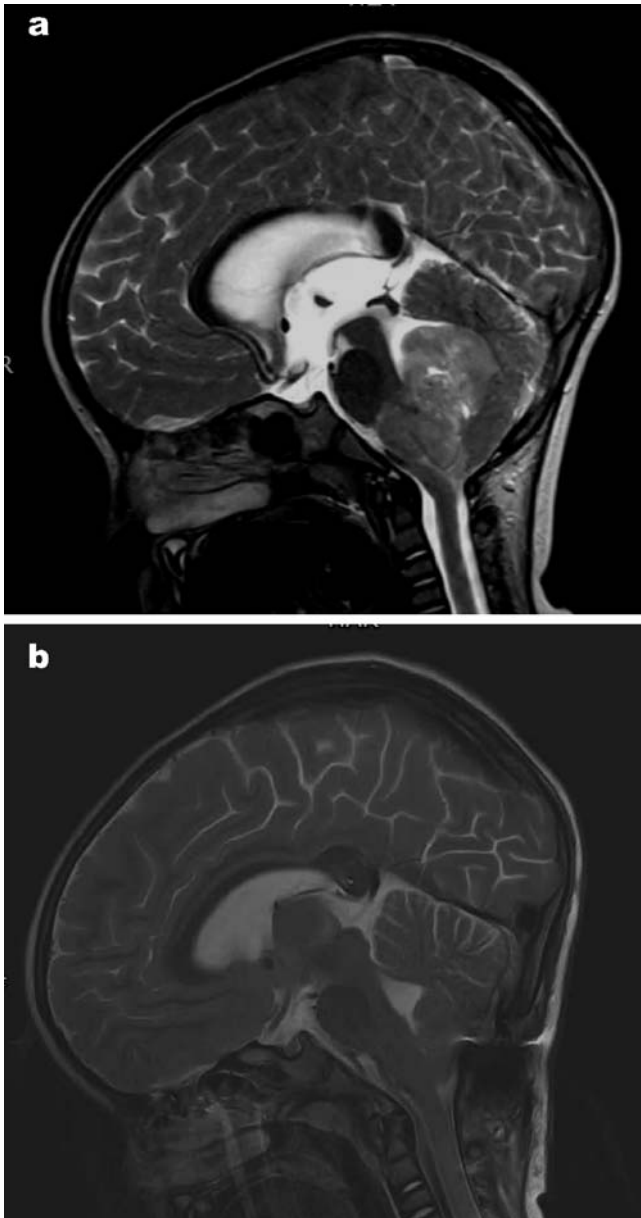


Figure-1a and 1b: Pre-operative and post-operative MR T2WI sagittal images showing a large posterior fossa tumour in a four-year old child, with obstructive hydrocephalus. The post-operative images showed removed tumour and re-opening of CSF pathways with no requirement of a VP shunt.

brainstem following shunt insertion.⁷ Van Calenbergh et al., reviewed the data of 42 patients treated at their center who underwent the placement of ventriculo-subgaleal shunt before tumour removal surgery. They reported no complications with the procedure, concluding it to be safe and effective in providing an adequate period of stability for appropriate tests before elective removal of the tumour. Ten patients however had persistent or new onset hydrocephalus post- tumour resection surgery and

had to undergo permanent shunt placement.⁸

More recently, Ruggiero et al., reviewed 63 patients at his center, 26 with severe associated hydrocephalus underwent CSF diversion with either ETV (n=20) or VP shunt (n=6). One patient in the ETV group developed an intraventricular bleed, but none required permanent shunting. In the 20 patients with associated hydrocephalus who did not undergo pre-operative CSF diversion, 11 developed post-operative complications of pseudo-meningoceles, CSF leaks, and acute or delayed post-operative hydrocephalus. In the rest of the 17 patients with no hydrocephalus and hence, no pre-operative CSF diversion, 4 patients were also noticed to develop the aforementioned post-operative complications. They thus concluded that pre-operative CSF diversion, especially ETV (whenever possible) is beneficial for improving surgical outcomes.⁹

Bhatia et al., published their series of 59 PFT patients treated at their centre of which 37 underwent ETV within 1.5 days of admission as a primary CSF diversion procedure. They noticed significant improvement in symptoms of increased ICP in 87% of the patients (n=32), determining ETV as safe and effective. However, 5 patients experienced ETV failure, with 3 patients developing meningitis and post-procedure haemorrhage.¹⁰ El Beltagy et al., also published their audit of 40 PFT patients who underwent pre-operative CSF diversion. While the authors were amenable to the practice, with the overall success rate of 65%, they also observed a failure rate as large as 35%. These patients required permanent VP shunts, and consequently, longer hospital stays, and delay of adjuvant therapy, questioning if the procedure was justified in the latter half of the sample population.¹¹ In another study, failure of CSF diversion was reported in patients undergoing subtotal tumour resection, or intra-operative practices such as the use of cadaveric dural grafts or leaving the dura open.¹

El-Gaidi et al., in a large series of 301 patients with PFTs, reviewed the results of pre-operative CSF diversion and found no significant difference in the complication rate between ETV and VP shunts. These included intratumoural haemorrhage and upward trans-tentorial herniation, which were associated with poor prognosis, resulting in the death of 3 patients even before they could undergo surgery for tumour resection.² In 2017, Le Fournier et al., analysed patients at his center undergoing treatment for metastatic PFTs, out of which 29 underwent pre-resection CSF drainage via ETV (n=18), VP Shunts (n=4) and EVDs (n=7). CSF diversion failure was seen in 52% of the cases, with recurrence of hydrocephalus in 55% of the ETV group.¹²

As for the theoretical risks associated with peritoneal seeding with a pre-operative VP shunt, the earlier literature suggested a risk of shunt associated seeding in up to 10-20% of patients, however, the numbers have been considered an overestimation and tumour filters are no longer recommended.⁴

Conclusion

In cases of PFT with pre-operative hydrocephalus, some form of CSF diversion is essential to aide in safe tumour resection and has been shown to improve surgical resection and outcomes. The choice is typically between an ETV, an EVD and a VP shunt. ETV has been shown to be effective in majority of patients, and although EVD is also a useful temporary procedure, it carries a higher risk of infection. Routine pre-operative VP shunt is no longer recommended as almost half the patients will not require a post-operative shunt.

References

1. Di Rocco F, Jucá CE, Zerah M, Sainte-Rose C. Endoscopic third ventriculostomy and posterior fossa tumors. *World Neurosurg.* 2013;79:S18. e5-S. e9.
2. El-Gaidi MA, El-Nasr AHA, Eissa EM. Infratentorial complications following preresection CSF diversion in children with posterior fossa tumors. *J Neurosurg Pediatr* 2015;15:4-11.
3. Khan F, Shamim MS, Rehman A, Bari ME. Analysis of factors affecting ventriculoperitoneal shunt survival in pediatric patients. *CHILD NERV SYST.*2013;29:791-802.
4. Berger MS, Baumeister B, Geyer JR, Milstein J, Kanev PM, LeRoux PD. The risks of metastases from shunting in children with primary central nervous system tumors. *J Neurosurg.* 1991;74:872-7.
5. Albright L, Reigel DH. Management of hydrocephalus secondary to posterior fossa tumors. *J. Neurosurg.* 1977;46:52-5.
6. Taylor W, Todd N, Leighton S. CSF drainage in patients with posterior fossa tumours. *Acta neurochirurgica.* 1992;117:1-6.
7. Goel A. Whither preoperative shunts for posterior fossa tumours? *Br J Neurosurg* 1993;7:395-9.
8. Van Calenbergh F, Goffin J, Casaer P, Plets C. Use of a ventriculosubgaleal shunt in the management of hydrocephalus in children with posterior fossa tumors. *CHILD NERV SYST.* 1996;12:34-7.
9. Ruggiero C, Cinalli G, Spennato P, Aliberti F, Cianciulli E, Trischitta V, et al. Endoscopic third ventriculostomy in the treatment of hydrocephalus in posterior fossa tumors in children. *CHILD NERV SYST.* 2004;20:828-33.
10. Bhatia R, Tahir M, Chandler CL. The management of hydrocephalus in children with posterior fossa tumours: the role of pre-resectional endoscopic third ventriculostomy. *Pediatr Neurosurg* 2009;45:186-91.
11. El Beltagy MA, Kamal HM, Taha H, Awad M, El Khateeb N. Endoscopic third ventriculostomy before tumor surgery in children with posterior fossa tumors, CCHE experience. *CHILD NERV SYST.* 2010;26:1699-704.
12. Le Fournier L, Delion M, Esvan M, De Carli E, Chappé C, Mercier P, et al. Management of hydrocephalus in pediatric metastatic tumors of the posterior fossa at presentation. *CHILD NERV SYST.* 2017;33:1473-80.