



THE AGA KHAN UNIVERSITY

eCommons@AKU

Department of Pathology and Laboratory Medicine

Medical College, Pakistan

November 1998

Primary Cutaneous Actinomycosis

Anjum Kanjee

Jinnah Postgraduate Medical Centre

Zamaz Wahid

Civil Hospital Karachi

Shahid Pervez

Aga Khan University, shahid.pervez@aku.edu

Follow this and additional works at: http://ecommons.aku.edu/pakistan_fhs_mc_pathol_microbiol



Part of the [Bacterial Infections and Mycoses Commons](#), and the [Pathology Commons](#)

Recommended Citation

Kanje, A., Wahid, Z., Pervez, S. (1998). Primary Cutaneous Actinomycosis. *Journal of Pakistan Medical Association*, 48(11), 347-349.

Available at: http://ecommons.aku.edu/pakistan_fhs_mc_pathol_microbiol/299

Primary Cutaneous Actinomycosis

Pages with reference to book, From 347 To 349

Anjum Kanjee (Department of Pathology, Jinnah Postgraduate Medical Centre, Karachi.)

Zamaz Wahid (Department of Dermatology, Civil Hospital, Karachi.)

Shahid Pervez (Department of Pathology, Aga Khan University Hospital, Karachi.)

Actinomycosis is a chronic granulomatous disease caused mainly by *Actinomyces israelii*. It is characterized by formation of multiple draining sinuses with discharge of characteristic yellow sulphur granules. There are five clinical types depending on the primary site of infection, namely cervicofacial, thoracic, abdominal, primary cutaneous and pelvic. Primary cutaneous actinomycosis is very uncommon. A case of primary cutaneous actinomycosis is reported here.

Case Report

A forty year old farmer presented with multiple nodules and discharging sinuses on lower abdomen, buttocks, scrotal and penile skin (Figures 1 and 2).

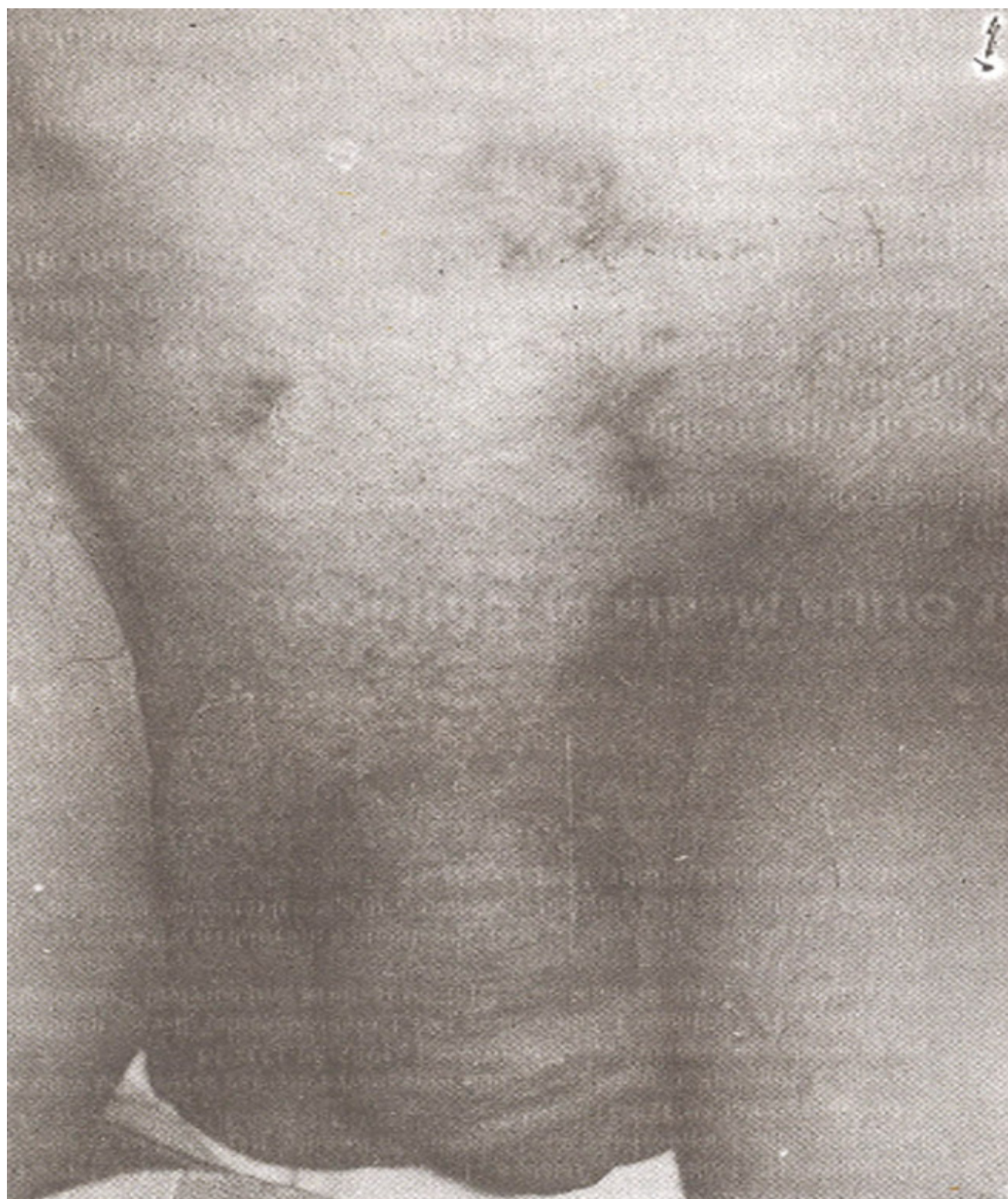

Figure 1. Multiple nodules and discharging sinuses on lower abdomen, scrotal and penile skin.

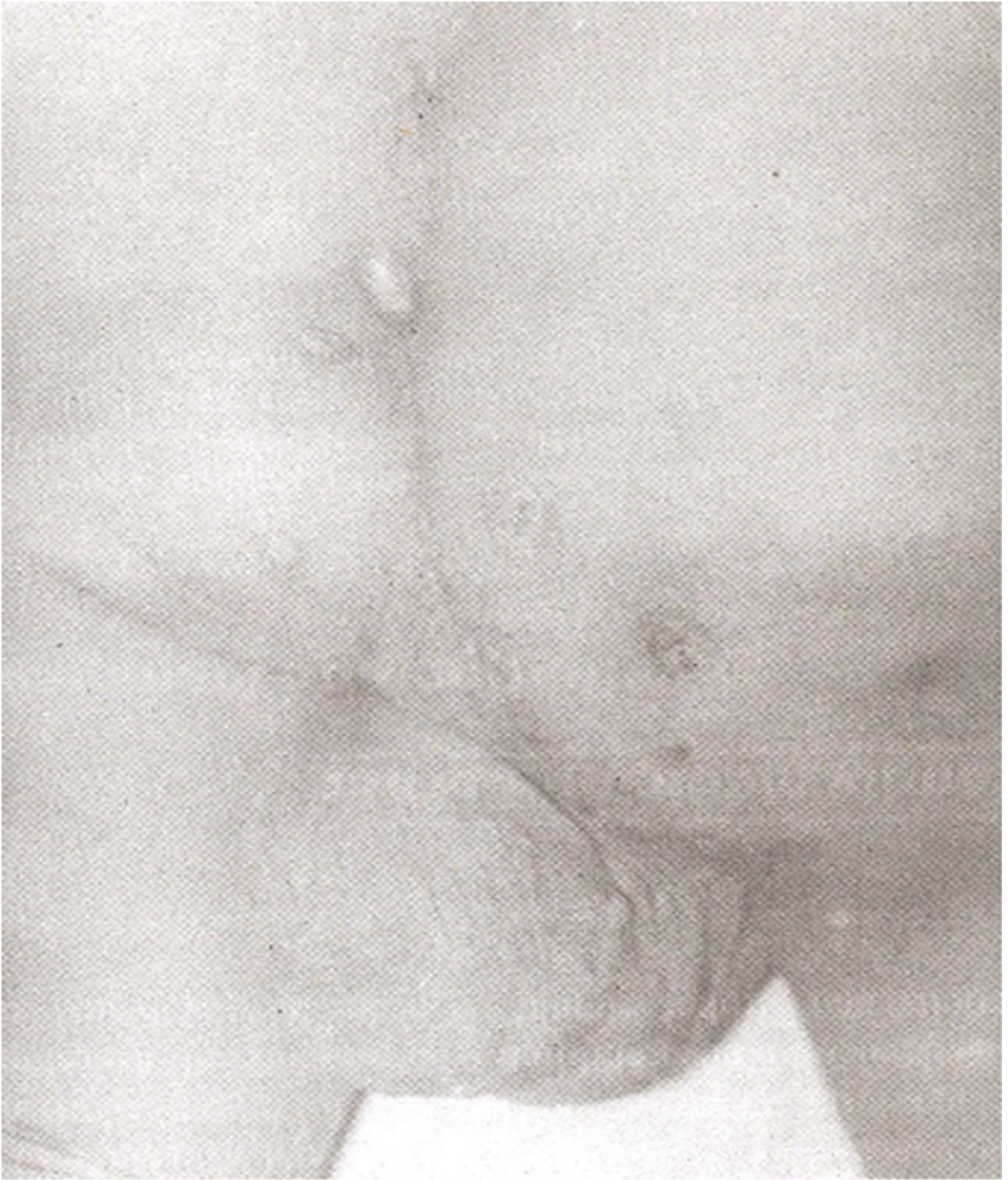

Figure 2. Nodules and sinuses involving the buttock and scrotum.

These lesions had gradually appeared over a period of 10 years. The regional lymph nodes were not enlarged. General physical and systemic examination was unremarkable. Preliminary investigations showed normal X-ray chest, haemoglobin level of 14.2 G%, ThC 8,200/mm³ and ESR of 79 mm in first hour. X-ray lumbar and sacral spines showed degenerative changes in pelvic and hip joints as

well as in the lumbar and sacral spines. No biochemical abnormality was detected on routine laboratory testing. Barium studies were normal. Skin biopsy was performed from the lower abdomen. H&E stained section of the skin showed typical dark stained actinomycotic colonies surrounded by abundant polymorph neutrophils

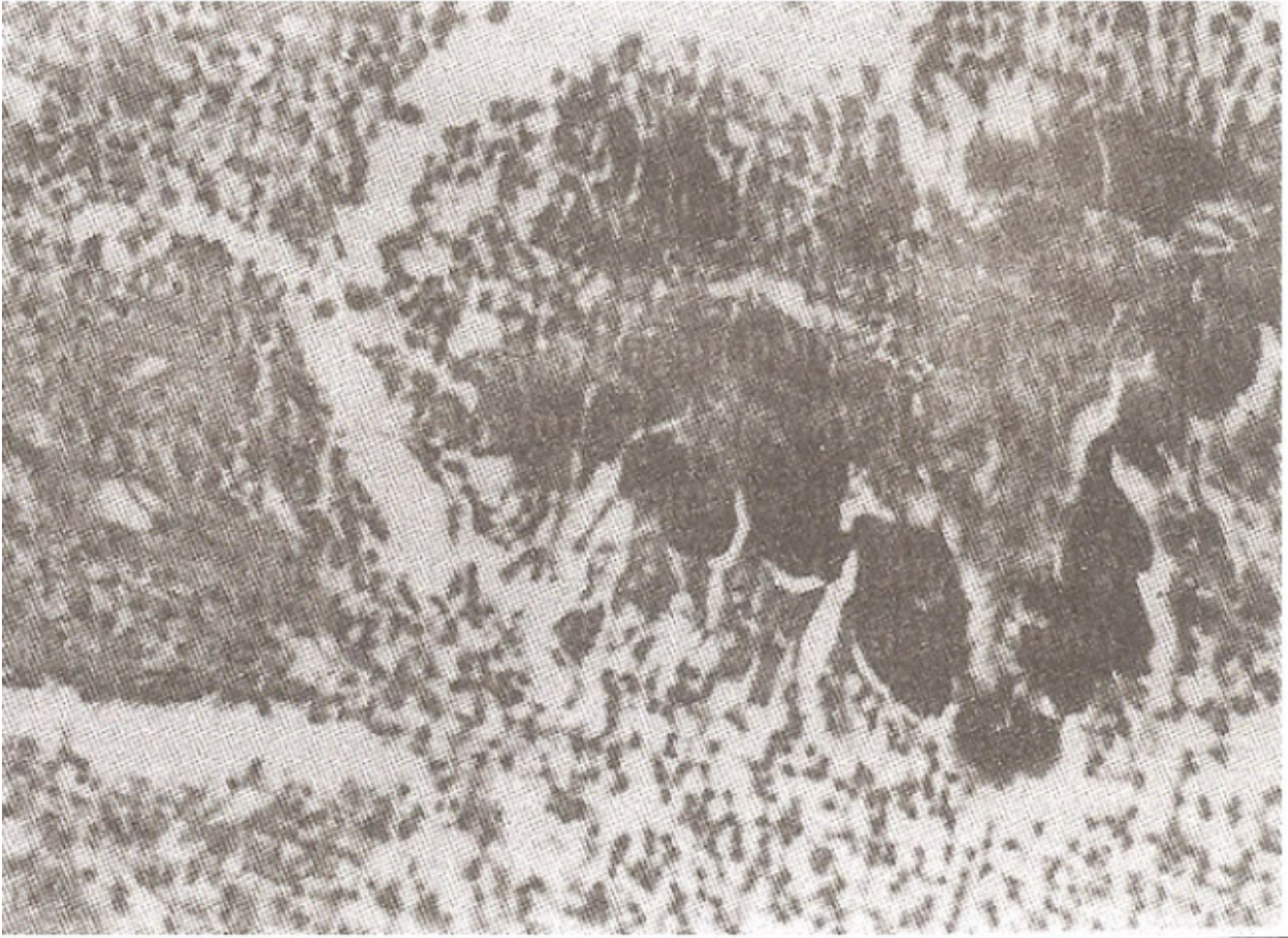


Figure 3. H & E stained sections showing typical dark stained actinomycotic colonies (magnification= 20x).

(Figure 3 H&E magnification = 20x). Culture on sheep blood agar in anaerobic conditions yielded the colonies of *Actinomyces israelii*. The patient was given 10 million units of benzylpenicillin in an infusion daily for 6 weeks. This was followed by surgical excision of sinuses. He is now on 5 million units of oral penicillin and has shown considerable improvement.

Discussion

Actinomycosis is caused by Gram positive filamentous branching bacteria. These are not fungi¹ as previously thought because they reproduce by division and not by formation of spores or budding. Actinomyces are the normal commensals of mouth and intestines. The infection is therefore acquired endogenously following trauma. The most common organism infecting man^{2,3} is *Actinomyces israelii* which is an anaerobe. *Actinomyces bovis*, *actinomyces naes-lundii*, *Arachnia proprionica* and *bifidobacterium eriksonii* are rarer organisms causing disease in *Actinomyces meyeri* infection has also been reported which presented as a leg abscess and a pulmonary lesion⁴. Actinomycosis was first reported in humans by Israel in 1878⁵. In 1891 Wolff and Israel were successful in culturing the

microorganism⁶.

Five clinical types of actinomycosis are recognised depending on the portal of entry of the organisms.

* Cervicofacial variety usually follows dental extraction. There is an indurated nodule on the cheek and submaxillary region. Later on there is formation of multiple sinuses with discharge of characteristic yellow sulphur granules. There is usually no enlargement of lymph nodes. Sometimes acute inflammation occurs.

* Thoracic variety follows inhalation of organisms into a diseased lung. Pulmonary actinomycosis simulates tuberculosis or malignancy with symptoms of fever, chest pain and haemoptysis. It may extend to the chest wall to form sinuses with discharge of sulphur granules.

Abdominal variety most commonly affects the caecum. It presents as a hard mass in right iliac fossa. Later on there is formation of multiple sinuses. This condition needs to be differentiated from tuberculosis, amoeboma, Crohn's disease and malignancy.

* Pelvic actinomycosis is becoming increasingly common with the use of intrauterine contraceptive devices.

* Primarily cutaneous actinomycosis is the least common variety. The lesions are in the form of subcutaneous nodules and discharging sinuses and these are usually present on exposed skin. Regional lymphadenopathy may occur.

In all types of actinomycosis there may be constitutional symptoms like fever, night sweats, chills, anorexia and weight loss. Anaemia of normochromic, normocytic variety may be present. The erythrocyte sedimentation rate is frequently raised. Leukocytosis is mild or absent⁶. Actinomycosis is diagnosed by finding the characteristic sulphur granules in the pus, exudate or tissue sections. These sulphur granules are formed by aggregates of organisms held together by calcium phosphate of host origin. The granules can be crushed and stained to reveal the gram positive branching filaments of Actinomyces. Crushed granules or discharging pus should be cultured anaerobically in glucose-thioglycollate broth or sheep blood agar. On agar plates, *A. israelii* produces white glistening lobulated colonies while the colonies of *A. bovis* have an entire edge. In the tissues the picture is that of suppurating fibrotic inflammatory process. The sulphur granules can occasionally be recognised. The colonies are surrounded by chronic granulomatous infiltrate with giant cells and sometimes macrophages.

The organism is sensitive to many antibiotics, which need to be given for weeks to reach the bacteria within fibrotic tissue and granules. It is sensitive to penicillin, tetracyclines, sulphonamides, streptomycin, rifampicin, erythromycin and chloramphenicol⁷. Penicillin is the drug of choice. High dose intravenous penicillin is required. In severe cases 10-12 million units of penicillin are given by intravenous infusion over a period of 12 hours daily for 4-6 weeks. This is followed by surgery to drain abscesses or excise sinuses and then oral phenoxymethyl penicillin in a dose of 4 to 6 g should be given daily. The treatment is usually given for a period of 6-8 months⁸. Prognosis of disease is good apart from the effect of fibrosis. Prolonged treatment with penicillin generally cause complete recovery⁹.

References

1. Farthina MJG, Jeffnes DJ, Anderson J. Infectious diseases, tropical medicine and sexually transmitted diseases. In Clinical Medicine. A textbook for medical students and doctors. Kumar PJ, and Clark ML (eds) UK, Bailliere Tindall, 1994, p.36.
2. Brock DW, Georg LK, Brown SM, et al. Actinomycosis caused by *Archamia propionica*. Report of 11 cases. Am. J. Clin. Pathol., 1973; 59:66-77.
3. Eng, RHK, Corrado ML, Cleri D, et al. Infections caused by *actinomyces viscosus*. Am. J. Clin. Pathol., 1981 ;75:113-16.
4. Machet L, Machet MC, Esteve E. *Actinomyces meyeri* cutaneous actinomycosis with pulmonary

localization. *Ann. Dermatol., Venereol*, 1993; 120:896-9.

5. Utz JP Shadomy HI. Deep fungal infections. In: *Dermatology in general medicine*. Fitzpatrick, Risen Wolff, Freedberg, Austen (eds) New York, McGraw Hill Book Company, 1993 ;2:2248-50.

6. Slack 3M, Genescser MA. *Actinomyces, Filamentous bacteria*. Minneapolis, Burgess, 1975.

7. Peabody JW, Seabury ill. Actinomycosis and nocardiosis. *Am. J. Med.*, 1960;28:99-115.

8. Hay RJ, Roberts SOB, Mackenzie DWR. Mycology. In: *Textbook of dermatology*. Champion, Burton, Ebling (eds). Vol 2. Oxford, Blackwell, 1992, pp. 1213-14.

9. Benammar S, Helardot PG, Sapin E, et al. Childhood actinomycosis report of two cases. *Eur. J. Pediatr. Surg.*, 1995;5:180-83.