



THE AGA KHAN UNIVERSITY

eCommons@AKU

---

Section of Gastroenterology

Department of Medicine

---

1-1-2021

## Updates on the diagnosis and management of hepatocellular carcinoma

Aimun Raees  
*Aga Khan University*

Muhammad Kamran  
*Fazaia Ruth Pfau Medical College, Karachi, Pakistan*

Hasan Özkan  
*Ankara University, School of Medicine, Ankara, Turkey*

Wasim Jafri  
*Aga Khan University, wasim.jafri@aku.edu*

Follow this and additional works at: [https://ecommons.aku.edu/pakistan\\_fhs\\_mc\\_med\\_gastroenterol](https://ecommons.aku.edu/pakistan_fhs_mc_med_gastroenterol)



Part of the [Digestive System Diseases Commons](#), [Gastroenterology Commons](#), and the [Hepatology Commons](#)

---

### Recommended Citation

Raees, A., Kamran, M., Özkan, H., Jafri, W. (2021). Updates on the diagnosis and management of hepatocellular carcinoma. *Euroasian Journal of Hepato-gastroenterology*, 11(1), 32-40.  
Available at: [https://ecommons.aku.edu/pakistan\\_fhs\\_mc\\_med\\_gastroenterol/300](https://ecommons.aku.edu/pakistan_fhs_mc_med_gastroenterol/300)

# Updates on the Diagnosis and Management of Hepatocellular Carcinoma

Aimun Raees<sup>1</sup>, Muhammad Kamran<sup>2</sup>, Hasan Özkan<sup>3</sup> , Wasim Jafri<sup>4</sup> 

## ABSTRACT

**Introduction:** Globally, the incidence, as well as mortality, related to hepatocellular carcinoma (HCC) is on the rise, owing to relatively few curative options. Underlying cirrhosis is the most common etiology leading to HCC, but risk factors of cirrhosis show great regional variability. Over the years, there has been a steady development in the diagnostic and therapeutic modalities of HCC, including the availability of a wide range of systemic chemotherapeutic agents. We aim to review the recent advancements in the diagnostic and therapeutic strategies for HCC.

**Methodology:** The literature search was done using databases PubMed, Cochrane, and Science Direct, and the latest relevant articles were reviewed.

**Findings:** Screening of HCC is a pivotal step in the early diagnosis of the disease. Current guidelines recommend using ultrasound and alpha fetoprotein but various new biomarkers are under active research that might aid in diagnosing very small tumors, not picked up by the current screening methods. Treatment options are decided based upon the overall performance of the patient and the extent of the disease, as per the Barcelona classification. There are very few options that offer a cure for the disease, ranging from liver resection and transplantation to tumor ablation. Downstaging has proven to have a significant role in the course of the disease. An attempt to control the disease can be made via radiological interventions, such as transarterial chemoembolization, transarterial radioembolization, or radiation therapy. For advanced disease, sorafenib used to be the only option until a couple of years ago. Recently, many other systemic agents have received approval as first-line and second-line therapies for HCC. Genomics is an area of active clinical research as understanding the mutations and genomics involved in the evolution of HCC might lead to a breakthrough therapy.

**Keywords:** Contrast-enhanced ultrasound, Genomics, Hepatocellular carcinoma, Immune checkpoint inhibitors, Lenvatinib, Metabolomics, Microwave ablation, Nivolumab, Transarterial radioembolization.

*Euroasian Journal of Hepato-Gastroenterology* (2021): 10.5005/jp-journals-10018-1335

## INTRODUCTION

Hepatocellular carcinoma (HCC) is one of the most lethal cancers as its incidence has been on the rise for the past 10 years, making it the sixth most commonly diagnosed cancer worldwide and the fourth leading cause of cancer-related deaths annually.<sup>1</sup> In 2018, the total number of new HCC cases globally was approximately 670,000, with 625,000 HCC related deaths.<sup>2</sup> It is the most common primary liver neoplasm with cirrhosis being the main underlying etiology. The risk factors of cirrhosis are significantly variable. Chronic hepatitis B virus (HBV) and aflatoxin exposure are common risk factors for cirrhosis in Asia and Africa<sup>3</sup> whereas in developed countries like USA, Europe, and Japan, chronic hepatitis C virus (HCV) along with alcoholic and nonalcoholic liver disease are more frequently identified.<sup>4,5</sup> The only effective way to reduce the risk of HCC is to promote a healthy lifestyle along with adhering to the treatment of chronic hepatitis.<sup>6</sup> Additionally, vaccination against HBV is another crucial step towards eliminating the risk of development of HCC. HCC is considered to have a poor prognosis because most cases are usually subclinical at the early stages when potentially curative treatment options are available and by the time of detection, they have reached to an advanced stage with very limited options of treatment remaining. This review article aims to analyze the recent advancements in the diagnosis and treatment of HCC and the available evidence to support the new therapeutic modalities.

<sup>1,4</sup>The Aga Khan University Hospital, Karachi, Pakistan

<sup>2</sup>Fazaia Ruth Pfau Medical College, Karachi, Pakistan

<sup>3</sup>Department of Gastroenterology, Ankara University, School of Medicine, Ankara, Turkey

**Address reprint requests to:** Wasim Jafri, The Aga Khan University Hospital, Karachi, Pakistan, e-mail: wasimjafri87@gmail.com

**How to cite this article:** Raees A, Kamran M, Özkan H, *et al.* Updates on the Diagnosis and Management of Hepatocellular Carcinoma. *Euroasian J Hepato-Gastroenterol* 2021;11(1):32–40.

**Source of support:** Nil

**Conflict of interest:** None

## METHODS

PubMed, Cochrane, and Science Direct databases were searched using keywords HCC, liver-directed therapies, systemic therapy, and immunotherapy. Relevant information from peer-reviewed articles was included. Appropriate reference articles were also retrieved. Non-English articles and non-human studies were excluded.

## Diagnosis

The aim of surveillance programs is to detect early tumors in patients with a good prognosis profile. This reduces cancer-related morbidity and mortality and increases survival rate, as curative treatments can be readily offered at this point in time. Surveillance is recommended

in all patients with cirrhosis irrespective of etiology. However, patients having chronic HBV in the absence of underlying cirrhosis also require regular surveillance, since HBV is an independent risk factor for HCC with a yearly incidence of more than 0.2%.<sup>7</sup> The average tumor doubling time is 4 to 6 months; hence, most of the clinical guidelines suggest 6 monthly surveillance in patients with cirrhosis.<sup>8-10</sup> Tumor markers add value to surveillance as they are non-invasive yet objective evaluation tools. The recommended investigation for surveillance is ultrasonography with or without serum alpha-fetoprotein (AFP) levels, as combination of the two modalities amplifies the rate of detection of early HCC. Ultrasonography is widely available, easily tolerated, and cost-effective with a sensitivity of 58 to 80% when performed by an expert.<sup>11-14</sup> Having said that, AFP is only 80% specific in diagnosing HCC, and the operator and equipment dependence of ultrasonography may raise false suspicions and add to the overall cost.<sup>15</sup> Moreover, AFP can be normal in about 40% of patients with early disease<sup>16</sup> while sensitivity of ultrasonography falls to only 30% for tumors <2 cm tumors.<sup>17</sup> This lead to the search of other tumor markers such as lectin-bound alpha-fetoprotein (AFP-L3), glypican 3, des-gamma carboxyprothrombin (DCP), osteopontin, annexin A2, acylcarnitine, alpha-fucosidase, Dickkopf 1, and Golgi protein 73. These have been studied and proven to be useful but none of these were superior in accuracy when compared to AFP.<sup>18,19</sup> According to a study, more than 35% of patients with very early HCC have elevated levels of DCP,<sup>20</sup> while another study claims that combination of DCP with AFP significantly improves the detection rate of HCC. The specificity of the DCP is 91% in contrast to 70% for AFP; however, sensitivity is significantly low (41%).<sup>21</sup> AFP-L3 has been found to be remarkably specific for HCC and is associated with more aggressive and infiltrative tumors.<sup>22</sup> A recent meta-analysis showed moderate accuracy of Dickkopf-1 for detecting HCC.<sup>23</sup> Abnormally expressed circular RNAs are novel biomarkers being studied for detection of early HCC.<sup>24</sup> A panel of seven micro-RNAs has shown high diagnostic accuracy in HBV-related HCC.<sup>25,26</sup> A study done in Egypt demonstrated vascular endothelial growth factor (VEGF) as a promising serum marker for HCC.<sup>27</sup> Besides biochemical markers, a serological model called GALAD score has also been introduced, which uses age, sex, and tumor markers for the diagnosis of HCC. It has emerged as a beneficial tool in a few studies but has not been externally validated so far.<sup>28</sup>

HCC is only cancer that requires only imaging to reach a definitive diagnosis. Almost all guidelines recommend an image-based diagnosis of HCC. On a background of liver cirrhosis, a definite diagnosis of HCC can be made if characteristic features such as arterial phase hyperenhancement while washout during delayed venous phase is present in a triphasic imaging study.<sup>29,30</sup> Either a contrast-enhanced computed tomography (CT) scan or magnetic resonance imaging (MRI) can be done, as both have similar diagnostic accuracy. The sensitivity and specificity of triphasic CT scan are 81 and 93%, respectively, while that of MRI is 91 and 95%, respectively.<sup>31</sup> Use of hepatobiliary contrast agents (gadoxetic acid and gadobenate dimeglumine) in MRI can further enhance sensitivity, but specificity may be lower than extracellular contrast agents for small HCC.<sup>32,33</sup> A major limitation of CT scan is the intense exposure to radiation. Besides CT and MRI, contrast-enhanced ultrasound (CEUS) has also proven to be highly sensitive for the diagnosis of HCC.<sup>34,35</sup> A recent multicenter prospective study and a meta-analysis, both report excellent diagnostic accuracy and high specificity of CEUS for the diagnosis of HCC.<sup>36</sup> However, CEUS may be unable to distinguish intrahepatic cholangiocarcinoma from HCC.

In 2011, a standardized system was first proposed for the interpretation and reporting of liver lesions. This system, endorsed by the American College of Radiology, is called Liver Image Reporting and Data System (LI-RADS) which classifies liver lesions into five categories based on contrast uptake and washout. It ranges from LR-1 lesions that are definitely benign, to LR-5 lesions that are conclusive of HCC. LI-RADS can be applied on CT, MRI, or CEUS. The system was recently updated in 2018.<sup>37</sup> LI-RADS is also utilized for the assessment and reporting of tumor response after treatment.

Quite often, atypical lesions are encountered that do not exhibit specific vascular profile and thus cannot be characterized via LI-RADS system. It is also essential to note that LI-RADS cannot be applied if the liver is noncirrhotic.<sup>38</sup> In both of these cases, a diagnostic biopsy becomes necessary. A false-negative rate of biopsies is around 30% due to the poor yield of the sample; hence, a negative biopsy is not adequate to rule out HCC.<sup>39</sup> A group of immunohistochemical stains including glutamine synthetase, glypican-3, and heat shock protein<sup>40</sup> should be requested as it increases specificity to 100% while sensitivity may still be suboptimal.<sup>41,39</sup>

Metabolomics is an evolving technology that involves a detailed examination of metabolites in a biological sample, also analyzing at the same time the variations in the metabolic profile as a result of exposure to the disease or drug.<sup>42</sup> There is growing interest in the role of metabolomics in predicting early HCC, and metabolomics studies have been carried out in common liver disorders like alcoholic liver disease, cirrhosis, and nonalcoholic fatty liver disease.<sup>43</sup> It is expected that such studies may be useful in decreasing the occurrence of HCC in at-risk population.

### Staging

Prognostication of disease is critical before planning therapeutic strategies for HCC. For this purpose, several staging systems have been designed.<sup>44</sup> The Barcelona Clinic Liver Cancer (BCLC) system has been the most widely recognized and extensively validated classification since its first publication in 1999.<sup>45,46</sup> It incorporates tumor burden, degree of liver dysfunction, and patient's performance status based on the Eastern Cooperative Oncology Group (ECOG) for determination of cancer stage and patient prognosis. It classifies patients into five stages starting from 0 (very early), A (early), B (intermediate), C (advanced) to D (terminal) stage.<sup>47</sup> Both EASL and AASLD recommend using the BCLC system for HCC staging and prognostic assessment. **Table 1** shows the latest version of the BCLC staging system.

**Table 1:** The Barcelona Clinic Liver Cancer (BCLC) system for staging of HCC

Stage	Tumor burden	Liver function (CTP score)	ECOG score
0 (very early)	Single lesion <2 cm	Child-Pugh A	
A (early)	Single or three lesions <3 cm		0
B (intermediate)	Multinodular tumor	Child-Pugh A or B	
C (advanced)	Portal invasion/extrahepatic spread		1–2
D (terminal)	Extensive disease	Child-Pugh C	3–4

## Treatment

While opting for therapeutic strategies, the main intention is to improve quality of life. The modality of treatment is chosen according to the clinical status of the patient based on the BCLC system. HCC is a complex disease with diverse therapeutic options available; hence, it is advised to refer HCC patients to multidisciplinary care teams that include hepatologists, surgeons, interventional radiologists, and oncologists to develop an effective treatment strategy.

## Curative Therapy

For patients with BCLC stage 0 to A, curative treatments can be offered. Potential curative options include liver resection (LR), liver transplant (LT), and ablation. Ablation can be done through radiofrequency waves (RFA), microwave (MWA), cryotherapy, or alcohol injection.

### Liver Resection

In patients with very early stage HCC without portal hypertension or high bilirubin, LR is the treatment of choice. Decompensated cirrhosis and vascular invasion are contraindications to LR. The proportion of patients who fulfill the criteria for resection is usually 5 to 10%. Potential complications can be liver failure, infection, thrombosis, or bleeding. The rate of survival depends upon the operator experience and disease status at the time of surgery, but the 5-year overall survival (OS) is estimated to be around 25 to 69.5%.<sup>48,49</sup> The main demerit is a high recurrence rate of HCC, approximately 60 to 100%.<sup>50</sup> No adjuvant or neoadjuvant therapies have been approved yet to decrease the risk of recurrence after resection. Laparoscopic surgery is a less invasive alternative to open resection, with reduced chances of postprocedure complications and similar outcomes as open surgery<sup>51,52</sup> but trials are needed for its validation. A randomized control trial that compared open LR with laparoscopic surgery concluded that the laparoscopic method was superior to open surgery in terms of safety with equivocal oncological outcome.<sup>53</sup> According to a recent meta-analysis, laparoscopic LR provides comparable survival rates as conventional open approach.<sup>54</sup>

### Liver Transplantation

Liver transplantation provides the best outcome to cirrhotic patients with early HCC. Besides removing tumor tissue, it also has the added benefit of simultaneously curing cirrhosis. As per EASL and AASLD guidelines, patients are selected based upon Milan's criteria that includes HCC <5 cm or three nodules less than 3 cm each with no microvascular invasion on imaging.<sup>55</sup> The result of LT is dependent on various factors such as tumor burden, ischemia time during surgery, and use of immunosuppressive drugs.<sup>56,57</sup> Shortage of organ availability is the main limiting factor resulting in candidates being dropped out from the waiting list. Although associated with higher postoperative morbidity and early mortality, LT delivers an excellent 5-year OS rate of >70%.<sup>58-60</sup> The recurrence rates are low, approximately 10 to 18%.<sup>61,62</sup> The practice of liver transplantation continues to evolve with the promotion of live organ donation.

### Ablation

Patients with stage 0-A disease, unsuitable for surgery due to elevated portal pressure, anatomic location of tumor, or comorbidities, should undergo ablation. Ablation is a minimally invasive approach that may use RFA, MWA, alcohol, laser, or

cryotherapy. The basic underlying mechanism is alteration of temperature leading to tumor necrosis. RFA is considered the first line therapy<sup>63</sup> and is recommended by both EASL and APASL. Complications may be intra-abdominal hemorrhage, liver failure, infection, tumor seeding, or biliary tract injury.<sup>64</sup> It is a very safe procedure with <0.5% mortality.<sup>65</sup> Limitations include location of tumor close to vessels, gallbladder, stomach, colon, or any other viscera.<sup>66</sup> The 5-year OS and recurrence rates of RFA are very similar to that of LR.<sup>67</sup>

Microwave ablation (MWA) is a novel approach that has shown outstanding results in the management of HCC. It offers similar advantages as that of RFA as well as several other benefits like higher degree of tumor necrosis, ability to treat larger tumors, reduced procedure time, and feasibility to perform in tumors located close to viscera or biliary tree.<sup>68</sup> According to the available literature, there is no statistically significant difference in efficacy and complication rates between MWA and RFA.<sup>69-71</sup> A recent RCT also endorsed non-inferiority of MWA in terms of safety and local recurrence.<sup>72</sup>

## Noncurative Therapy

For patients who are not eligible for curative treatments, several other therapies are advocated to decrease tumor burden and to prolong long-term survival. These include both palliative interventions and systemic therapies.

## Locoregional Therapy

### Transarterial Chemoembolization

The vascular supply of HCC is derived from the hepatic artery, while the rest of the liver parenchyma is supplied mainly by the portal vein. This difference in vascular supply is the basic principle of all embolization therapies as devascularization of tumor tissue is acquired without affecting normal tissue. This is achieved via drugs, embolic, or radioactive particles.<sup>73</sup> Guidelines have recommended transarterial chemoembolization (TACE) as the standard option for patients with HCC of BCLC stage B as it has shown great survival benefit.<sup>74-76</sup>

Conventional-TACE (cTACE) uses injection of chemotherapeutic agents, such as doxorubicin, cisplatin, or mitomycin, mixed with lipiodol into hepatic artery and completely obstructing it with gelatin sponge, thus inducing ischemia and cytotoxicity leading to tumor necrosis.<sup>77</sup> Patients with portal vein thrombosis or extrahepatic disease, high localized tumor burden (>10 cm), or eGFR <30 mL/minute are not considered good candidates for the procedure.<sup>73-79</sup> Postembolization syndrome is a frequently occurring complication, characterized by fever, abdominal pain, nausea, and vomiting. It is usually mild and responds well to antipyretic and analgesic therapy.<sup>80</sup>

TACE with drug-eluting beads (DEB-TACE) is a modified version of conventional TACE in which polyvinyl alcohol hydrogel is used to seal off the artery. This causes a sustained release of chemotherapeutic drugs thus increasing cytotoxicity to tumor cells while reducing exposure to rest of the hepatic parenchyma and circulatory system.<sup>81,82</sup> It is a better-tolerated procedure with improved results and less severe adverse events even though the rate of complications remains same as cTACE. The 5-year OS is reported to be 18 to 28.7 months with cTACE and 30 to 40 months with DEB-TACE.<sup>76,83</sup> DEB-TACE is not considered superior to cTACE.<sup>84</sup>

TACE with degradable starch microspheres (DSM-TACE) is a novel technique that uses a completely degradable, hydrophilic starch matrix that is able to reach at arteriolar or capillary level due to its small diameter causing transient occlusion of small arteries. This limited-time occlusion reduces the chances of systemic toxicity and postembolization syndrome.<sup>85</sup> Some studies have shown its potential safety and efficacy proposing it as a second-line liver-directed therapy for patients with intermediate- to advanced-stage HCC.<sup>86,87</sup> A prospective study showed a median OS of 36 months after DSM-TACE but randomized control trials are needed to validate these results.

**Transarterial Radioembolization**

Transarterial radioembolization (TARE), a form of selective internal radiation therapy, is a highly advanced liver-directed therapy, that uses intra-arterial injection of radioactive spheres (loaded with Yttrium-90, iodine-131, or rhenium-188) to cause radiation-induced tumor necrosis.<sup>88</sup> The magnitude of ischemia is comparatively lesser in comparison to TACE, hence decreasing the chances and severity of postembolization syndrome. It is indicated for BCLC-B disease and unlike other radiological procedures, this intervention can also be done in patients with portal vein thrombosis or high tumor burden (bilobar disease). Patients not amenable to TARE are the ones with metastatic HCC, decompensated cirrhosis, prior radiation to liver, and significant hepatointestinal and hepatopulmonary shunts (>20%).<sup>89</sup> Postprocedure complications include liver failure, radiation pneumonitis, biliary complications, radioembolization induced liver disease, and postembolization syndrome.<sup>90</sup> The survival benefit is not reported to be very different from TACE ranging from 14 to 16.9 months, but TARE demonstrated reduced toxicity and longer time to progression of disease (13.3 vs 8.4 months).<sup>91,92</sup>

**Stereotactic Body Radiation**

Historically, radiation therapy has never been a part of treatment algorithms in HCC. However, enormous technological developments over the last few decades have led to the introduction of stereotactic body radiation therapy (SBRT) as a promising treatment for HCC. It has been added to the NCCN guidelines for the treatment of patients with nonresectable tumors with portal vein thrombosis or extrahepatic metastases.<sup>93</sup> A recent clinical audit showed excellent results of SBRT in terms of safety and efficacy for large inoperable HCCs.<sup>94</sup> It has also shown great benefits in palliation of symptomatic patients with metastatic lesions.<sup>95</sup> The limitations to

SBRT include location of tumor near important organs like biliary tree or gastrointestinal tract increasing the risk of radiation induced inflammation and bleeding. Radiation induced liver disease, defined as hepatomegaly, ascites, and cholestasis, is a known complication of SBRT which can be fatal in 5 to 13% cases.<sup>96,97</sup> According to a recent meta-analysis and a phase 2 clinical trial, the local control of HCC achieved by SBRT is equivalent to that of RFA.<sup>98,99</sup> Studies have exhibited a median overall survival of 8 to 17 months after SBRT.<sup>100</sup> However, there is still a paucity of data on long term survival beyond 2 years. No progression of disease was seen upto 1 to 3 years in 87 to 100% of cases.<sup>101</sup>

**Systemic Therapy**

Systemic therapy is the cornerstone of treatment for patients with advanced disease who are not surgical candidates or fit for liver directed therapies. Over the past couple of years, systemic therapy has immensely evolved, with multiple new drugs being approved while others are under evaluation. Figure 1 shows currently available drugs for systemic therapy.

**Multikinase Inhibitors**

These drugs exert antiproliferative, antiangiogenic and apoptotic properties by blocking RAF signaling along with VEGF, platelet growth factor and KIT.

**First-line Therapy**

**Sorafenib**

Sorafenib remained the only standard of care for patients with BCLC-C disease, since its approval in 2007. Although it was first discovered in 1990 but only gained FDA approval after the phase 3 sorafenib HCC assessment randomized protocol trial that proved an increase in OS when compared with placebo (median OS 10.7 vs 7.9 months, respectively) in patients with advanced HCC.<sup>102</sup> The trial also indicated that sorafenib was potentially effective against HCC regardless of tumor burden, ECOG class, liver status, AFP levels, or previous therapy.<sup>103,104</sup> The reported time to radiologic progression was 5.5 months with sorafenib vs 2.8 months with placebo. However, the overall response rate (ORR) was low. Commonly encountered side effects were diarrhea, weight loss, arterial hypertension, fatigue, and hand-foot syndrome. Around 30% patients do not tolerate sorafenib due to the side effects. Improved outcomes were observed in patients who developed dermatological side effects.<sup>105</sup>

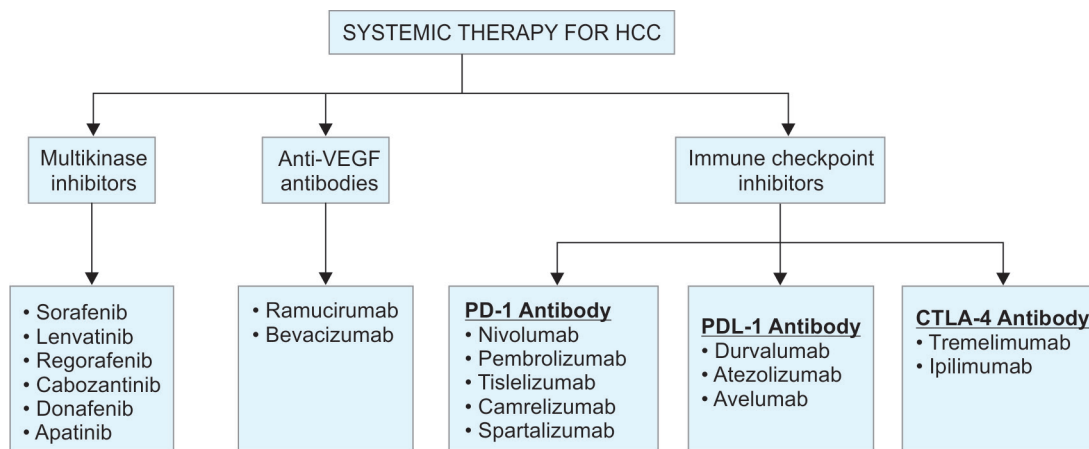


Fig. 1: Systemic therapy for HCC



### *Lenvatinib*

Lenvatinib is another oral tyrosine kinase inhibitor that acts on VEGFR 1 to 3, FGFR 1-4, RET, KIT, and PDGFR alpha. Its ability to inhibit fibroblast growth factor receptors distinguishes it from sorafenib. Lenvatinib gained approval as first-line therapy for advanced HCC in 2018 on the basis of phase 3 REFLECT trial. The study included unresectable HCC, BCLC-B and C patients with no prior systemic therapy, and patients with greater than 50% liver impairment and portal or biliary invasion were excluded. The results affirmed non-inferiority of lenvatinib to sorafenib in terms of median OS (13.6 vs 12.3 months, respectively). Lenvatinib also demonstrated longer progression-free survival (7.3 vs 3.6 months), time for tumor progression (7.4 vs 3.7 months), and higher objective response rate (18.8 vs 6.5%) as well as better outcome in patients with AFP greater than 200 ng/mL. Adverse event profile was similar to that of sorafenib.<sup>106</sup>

### *Donafenib*

Donafenib is a novel multikinase inhibitor that has revealed great anti-tumor activity and favorable tolerability. An open label, randomized, phase 2/3 clinical trial from China demonstrated significantly longer OS with donafenib compared to sorafenib (12.1 vs 10.2 months, respectively). Frequent adverse events with donafenib were hand-foot skin reaction, deranged liver functions, thrombocytopenia, and diarrhea.<sup>107</sup> Donafenib is currently pending approval by the FDA.

## Second-line Therapy

### *Regorafenib*

Regorafenib was the first drug that showed survival benefit as second-line treatment and was approved by FDA in 2017, after the results of a phase 3 trial (RESOURCE) which showed significant improvement in OS 10.6 vs 7.8 months with placebo, for patients who had disease progression on sorafenib. It is also a multikinase inhibitor with more profound antiangiogenic activity as it blocks both VEGF and TIE pathways. Mostly encountered side effects were hypertension, diarrhea, fatigue, and hand-foot reaction.<sup>108</sup>

### *Cabozantinib*

Cabozantinib is a multikinase inhibitor that has stronger activity against MET and AXL signaling pathways. The approval of cabozantinib was based on a phase 3 trial (CELESTIAL) that evaluated its efficacy in patients who progressed on or did not tolerate sorafenib. The study demonstrated improved median OS (10.2 vs 8.0 months), progression-free survival (5.2 vs 1.9 months), and objective response rate (4 vs 1%). Adverse events commonly noted were palmar-plantar erythrodysesthesia, hypertension, fatigue, and diarrhea.<sup>109</sup>

## Anti-VEGF Antibodies

### *Ramucirumab*

Ramucirumab is a monoclonal recombinant IgG1 antibody against VEGFR-2. A phase 3 study REACH-2 examined its action in patients with advanced HCC with AFP levels greater than 400 ng/mL. The results were improved median OS (8.5 vs 7.3 months), progression-free survival (2.8 vs 1.6 months), and objective response rate (5 vs 1%).<sup>110</sup> Ramucirumab received FDA approval as second-line agent against advanced HCC in May 2020.

### *Bevacizumab*

It has recently been approved by FDA to be utilized as a combination drug with atezolizumab against advanced HCC.

## Immunotherapy

Immunotherapy consists of immune checkpoint inhibitors that have the potential to target checkpoint proteins on immune and cancer cells. It is broadly classified, according to their target immune cells, into three types, programmed cell death protein-1 (PD-1), programmed cell death 1 ligand 1 (PDL-1), and cytotoxic T-lymphocyte associated protein 4 (CTLA-4) antibodies.

### *Nivolumab*

Nivolumab is a monoclonal antibody that blocks PD1-receptor. It gained accelerated approval as second-line therapy in 2017 based on a phase 2 study (CheckMate 040). Later, the phase 3 study (CheckMate 459) demonstrated the efficacy and safety of nivolumab in patients with advanced HCC who failed sorafenib therapy. According to the trial, the median OS was 16.4 vs 14.7 months with placebo, progression-free survival was 3.7 vs 3.8 months, and ORR was 20%. Fewer adverse effects were encountered compared to sorafenib which included rash, elevated liver and pancreatic enzymes, and pruritis.<sup>111</sup>

### *Pembrolizumab*

On the basis of a phase 2 clinical trial, KEYNOTE-224, pembrolizumab received accelerated FDA approval in 2018. The study compared pembrolizumab with best supportive care in patients who developed progression on sorafenib and demonstrated improved median OS of 12.9 vs 10.6 months in the control group, progression-free survival 4.9 vs 2.0 months, and ORR of 17%. Side effects were similar to that of nivolumab and tolerated well.

## Combination Therapy

The IMbrave150 is considered a breakthrough study as it leads to the approval of the first combination therapy for HCC, simultaneously paving the way for further advancements in this field giving a ray of hope to the patients of HCC. Combination therapy is a field of continuous medical expansion, multiple trials using different drug combinations are ongoing and their outcomes are intently awaited.

### *Atezolizumab + Bevacizumab*

This combination was approved in May 2020 as the first-line therapy against advanced HCC, bringing a revolution to HCC therapy with the idea that synergistic anti-tumor activity exerted by two drugs can be superior to single-drug therapy. The study (IMbrave150) compared combination of atezolizumab (PDL-1 inhibitor) and bevacizumab (anti-VEGF antibody) with sorafenib in patients with locally advanced or metastatic HCC. Results of the trial showed progression-free survival of 6.8 vs 4.3 months with sorafenib and ORR of 27.3 vs 11.9%, respectively. Commonly reported adverse effects with the combination are hypertension, hepatitis, fever, and proteinuria.<sup>112</sup>

### *Nivolumab + Ipilimumab*

Nivolumab is a PD-1 inhibitor and ipilimumab is a CTLA-4 inhibitor and their combination gained accelerated approval in 2020. The trial CheckMate 040 reported an ORR of 31% and 24 months OS rate was 40%. Adverse events included fatigue, diarrhea, rash, pruritis, dyspnea, weight loss, abdominal pain, headache, arthralgia, vomiting, and musculoskeletal pain.<sup>113</sup>

### Other Potential Combination Therapies

The concept of combination therapies is rapidly accelerating as agents from different groups are being investigated for their potential activity against HCC. LEAP-002 is studying the effects of lenvatinib and pembrolizumab in advanced HCC.<sup>114</sup> Combination therapy with durvalumab and tremelimumab is also underway.<sup>115</sup> Provisional results from a phase 2 study of camrelizumab plus FOLFOX look promising.<sup>116</sup> The possibilities are endless, hence a good number of combination therapies are undergoing trials currently (Table 2).

### Genomic Therapy

The paucity of treatment options for HCC patients has stimulated the researchers to look into all possibilities that can potentially provide beneficial results. Genetic mutations associated with HCC are currently being studied in depth with the idea of targeting these specific mutations.<sup>117</sup> Epigenetic alterations induced by DNA methylation seem to be reversible, thus presenting a possible target against which therapeutic strategies can be developed. DNA methylation inhibitors, azacytidine, and decitabine are currently being studied for HCC. A phase 1/2 trial conducted on decitabine showed favorable results.<sup>118</sup> A phase 2 trial using a combination of guadecitabine, sorafenib, and oxaliplatin is currently ongoing (NCT03257761).<sup>119</sup>

The dysregulation of histones is also under active investigation, and drugs to modify their course are underway. Histone deacetylase inhibitors, such as belinostat and resminostat, are under trial. (NCT00321594, NCT00943449) Needless to say, it is only the tip of the iceberg and provides a future landscape in the treatment of HCC. It is expected that advancements in this field could lead to the development of revolutionary therapies with the best possible outcomes.

### CONCLUSION

HCC is a universal health burden due to the rapidly rising mortality rate associated with it. According to the latest numbers, it is estimated that its incidence will continue to grow. It is crucial to devise therapeutic strategies that could control the disease and prolong the survival of patients. Fortunately, systemic therapy has advanced rapidly over the past few years. However, the advent of immunotherapy has proven to be a game changer. The role of genomic and adoptive cell therapy is still unclear. A lot of in-depth research is therefore needed to further enhance our perception of the disease at molecular and genetic levels, in order to explore new treatment options for HCC.

**Table 2:** Ongoing trials on combination therapies for HCC

Sl. No	Combination	Trial number
1	Lenvatinib + pembrolizumab	NCT03713593
2	Durvalumab + tremelimumab	NCT03298451(HIMALAYA)
3	Nivolumab + ipilimumab	NCT01658878
4	Cabozantinib + atezolimumab	NCT03755791(COSMIC-312)
5	Sintilimab + IBI305	NCT04072679
6	Camrelizumab SHR-1210 + apatinib	NCT02942329
7	SBRT + Camrelizumab + apatinib	ChiCTR1900027102

### ORCID

Hasan Ozkan  <https://orcid.org/0000-0002-5203-2528>

Wasim Jafri  <https://orcid.org/0000-0002-8902-2761>

### REFERENCES

1. Bray F, Ferlay J, Soerjomataram I, et al. Global cancer statistics 2018: GLOBOCAN estimates of incidence and mortality worldwide for 36 cancers in 185 countries. *Cancer J Clin* 2018;68(6):394–424. DOI: 10.3322/caac.21492.
2. Gordan JD, Kennedy EB, Abou-Alfa GK, et al. Systemic therapy for advanced hepatocellular carcinoma: ASCO guideline. *J Clin Oncol* 2020;38(36):4317–4345. DOI: 10.1200/JCO.20.02672.
3. Jafri W, Kamran M. Hepatocellular carcinoma in Asia: a challenging situation. *Euroasian J Hepatogastroenterol* 2019;9(1):27–33. DOI: 10.5005/jp-journals-10018-1292.
4. El-Serag HB. Epidemiology of viral hepatitis and hepatocellular carcinoma. *Gastroenterology* 2012;142(6):1264–1273.e1. DOI: 10.1053/j.gastro.2011.12.061.
5. Dogan S, Gurakar A. Liver Transplantation update: 2014. *Euroasian J Hepatogastroenterol* 2015;5(2):98–106. DOI: 10.5005/jp-journals-10018-1144.
6. Kanwal F, Kramer JR, Duan Z, et al. Trends in the burden of nonalcoholic fatty liver disease in a United States cohort of veterans. *Clin Gastroenterol Hepatol* 2016;14(2):301–308.e1–e2. DOI: 10.1016/j.cgh.2015.08.010.
7. European Association For The Study Of The Liver and European Organisation For Research And Treatment Of Cancer. EASL-EORTC clinical practice guidelines: management of hepatocellular carcinoma. *J Hepatol* 2012;56(4):908–943. DOI: 10.1016/j.jhep.2011.12.001.
8. European Association for the Study of the Liver. Electronic address: easloffice@easloffice.eu and European Association for the Study of the Liver. EASL clinical practice guidelines: management of hepatocellular carcinoma. *J Hepatol* 2018;69(1):182–236. DOI: 10.1016/j.jhep.2018.03.019.
9. Marrero JA, Kulik LM, Sirlin CB, et al. Diagnosis, staging, and management of hepatocellular carcinoma: 2018 practice guidance by the American Association for the Study of Liver Diseases. *Hepatology* (Baltimore, Md.) 2018;68(2):723–750. DOI: 10.1002/hep.29913.
10. Omata M, Cheng AL, Kokudo N, et al. Asia-Pacific clinical practice guidelines on the management of hepatocellular carcinoma: a 2017 update. *Hepatol Int* 2017;11(4):317–370. DOI: 10.1007/s12072-017-9799-9.
11. Pocha C, Dieperink E, McMaken KA, et al. Surveillance for hepatocellular cancer with ultrasonography vs. computed tomography -- a randomised study. *Aliment Pharmacol Ther* 2013;38(3):303–312. DOI: 10.1111/apt.12370.
12. Singal A, Volk ML, Waljee A, et al. Meta-analysis: surveillance with ultrasound for early-stage hepatocellular carcinoma in patients with cirrhosis. *Aliment Pharmacol Ther* 2009;30(1):37–47. DOI: 10.1111/j.1365-2036.2009.04014.x.
13. Chou R, Cuevas C, Fu R, et al. Imaging techniques for the diagnosis of hepatocellular carcinoma: a systematic review and meta-analysis. *Ann Intern Med* 2015;162(10):697–711. DOI: 10.7326/M14-2509.
14. Lersritwimanmaen P, Nimanong S. Hepatocellular carcinoma surveillance: benefit of serum alpha-fetoprotein in real-world practice. *Euroasian J Hepatogastroenterol* 2018;8(1):83–87. DOI: 10.5005/jp-journals-10018-1268.
15. Zhang B, Yang B. Combined alpha fetoprotein testing and ultrasonography as a screening test for primary liver cancer. *J Med Screen* 1999;6(2):108–110. DOI: 10.1136/jms.6.2.108.
16. Wang M, Devarajan K, Singal AG, et al. The Doylestown algorithm: a test to improve the performance of AFP in the detection of hepatocellular carcinoma. *Cancer Prev Res (Philadelphia, PA)* 2016;9(2):172–179. DOI: 10.1158/1940-6207.CAPR-15-0186.
17. Abdelaziz AO, Nabil MM, Omran DA, et al. Hepatocellular Carcinoma Multidisciplinary Clinic-Cairo University (HMC-CU) score: a new simple

- score for diagnosis of HCC. *Arab J Gastroenterol* 2020;21(2):102–105. DOI: 10.1016/j.ajg.2020.04.001.
18. Oka H, Saito A, Ito K, et al. Multicenter prospective analysis of newly diagnosed hepatocellular carcinoma with respect to the percentage of Lens culinaris agglutinin-reactive alpha-fetoprotein. *J Gastroenterol Hepatol* 2001;16(12):1378–1383. DOI: 10.1046/j.1440-1746.2001.02643.x.
  19. Tsuchiya N, Sawada Y, Endo I, et al. Biomarkers for the early diagnosis of hepatocellular carcinoma. *World J Gastroenterol* 2015;21(37):10573–10583. DOI: 10.3748/wjg.v21.i37.10573.
  20. Jang ES, Jeong SH, Kim JK, et al. Diagnostic performance of alpha-fetoprotein, protein induced by vitamin K absence, osteopontin, Dickkopf-1 and its combinations for hepatocellular carcinoma. *PLoS One* 2016;11(3):e0151069. DOI: 10.1371/journal.pone.0151069.
  21. Ishii M, Gama H, Chida N, et al. Simultaneous measurements of serum alpha-fetoprotein and protein induced by vitamin K absence for detecting hepatocellular carcinoma. *South Tohoku District Study Group. Am J Gastroenterol* 2000;95(4):1036–1040. DOI: 10.1111/j.1572-0241.2000.01978.x.
  22. Khien VV, Mao HV, Chinh TT, et al. Clinical evaluation of lentil lectin-reactive alpha-fetoprotein-L3 in histology-proven hepatocellular carcinoma. *Int J Biol Markers* 2001;16(2):105–111. <https://doi.org/10.1177%2F172460080101600204>
  23. Li Z, Mou L, Gao H, et al. Diagnostic accuracy of serum dickkopf-1 protein in diagnosis hepatocellular carcinoma: an updated meta-analysis. *Medicine* 2019;98(32):e16725. DOI: 10.1097/MD.00000000000016725.
  24. Yu G, Yang L, Zhou J, et al. Abnormally expressed circular RNAs are promising biomarkers for diagnosis of hepatocellular carcinoma: a meta-analysis. *Clin Lab* 2019;65(11):10.7754/Clin.Lab.2019.190354. DOI: 10.7754/Clin.Lab.2019.190354.
  25. Zhou J, Yu L, Gao X, et al. Plasma microRNA panel to diagnose hepatitis B virus-related hepatocellular carcinoma. *J Clin Oncol* 2011;29(36):4781–4788. DOI: 10.1200/JCO.2011.38.2697.
  26. Akkiz H. The emerging role of Micro RNAs in hepatocellular carcinoma. *Euroasian J Hepatogastroenterol* 2014;4(1):45–50. DOI: 10.5005/jp-journals-10018-1095.
  27. Hamdy MN, Shaheen KY, Awad MA, et al. Vascular endothelial growth factor (VEGF) as a biochemical marker for the diagnosis of hepatocellular carcinoma (HCC). *Clin Pract* 2020;17(1):1441–1453. DOI: <https://doi.org/10.1186/s43066-020-00073-5>
  28. Berhane S, Toyoda H, Tada T, et al. Role of the GALAD and BALAD-2 serologic models in diagnosis of hepatocellular carcinoma and prediction of survival in patients. *Clin Gastroenterol Hepatol* 2016;14(6):875–886.e6. DOI: 10.1016/j.cgh.2015.12.042.
  29. Khalili K, Kim TK, Jang HJ, et al. Optimization of imaging diagnosis of 1-2 cm hepatocellular carcinoma: an analysis of diagnostic performance and resource utilization. *J Hepatol* 2011;54(4):723–728. DOI: 10.1016/j.jhep.2010.07.025.
  30. Furlan A, Marin D, Vanzulli A, et al. Hepatocellular carcinoma in cirrhotic patients at multidetector CT: hepatic venous phase versus delayed phase for the detection of tumour washout. *Br J Radiol* 2011;84(1001):403–412. DOI: 10.1259/bjr/18329080.
  31. Sun H, Song T. Hepatocellular carcinoma: advances in diagnostic imaging. *Drug Discov Ther* 2015;9(5):310–318. DOI: 10.5582/ddt.2015.01058.
  32. Vietti Violi N, Lewis S, Liao J, et al. Gadoxetate-enhanced abbreviated MRI is highly accurate for hepatocellular carcinoma screening. *Eur Radiol* 2020;30(11):6003–6013. DOI: 10.1007/s00330-020-07014-1.
  33. Kim DH, Choi SH, Kim SY, et al. Gadoxetic acid-enhanced MRI of hepatocellular carcinoma: value of washout in transitional and hepatobiliary phases. *Radiology* 2019;291(3):651–657. DOI: 10.1148/radiol.2019182587.
  34. Schellhaas B, Bernatik T, Bohle W, et al. Contrast-enhanced ultrasound algorithms (CEUS-LIRADS/ESCU LAP) for the noninvasive diagnosis of hepatocellular carcinoma - a prospective multicenter DEGUM study. CEUS-Algorithmen für den kontrastverstärkten Ultraschall (CEUS-LIRADS/ESCU LAP) in der nichtinvasiven Diagnostik des hepatozellulären Karzinoms – eine prospektive, multizentrische DEGUM-Studie. *Ultraschall Med* (Stuttgart, Germany: 1980), 2020;42(2):178–186. DOI: 10.1055/a-1198-4874.
  35. Burak KW, Sherman M. Hepatocellular carcinoma: consensus, controversies and future directions. A report from the Canadian Association for the Study of the Liver Hepatocellular Carcinoma Meeting. *Can J Gastroenterol Hepatol* 2015;29(4):178–184. DOI: 10.1155/2015/824263.
  36. Shin J, Lee S, Bae H, et al. Contrast-enhanced ultrasound liver imaging reporting and data system for diagnosing hepatocellular carcinoma: a meta-analysis. *Liver Int* 2020;40(10):2345–2352. DOI: 10.1111/liv.14617.
  37. Chernyak V, Fowler KJ, Kamaya A, et al. Liver imaging reporting and data system (LI-RADS) version 2018: imaging of hepatocellular carcinoma in at-risk patients. *Radiology* 2018;289(3):816–830. DOI: 10.1148/radiol.2018181494.
  38. Forner A, Vilana R, Ayuso C, et al. Diagnosis of hepatic nodules 20 mm or smaller in cirrhosis: prospective validation of the noninvasive diagnostic criteria for hepatocellular carcinoma. *Hepatology* (Baltimore, Md.) 2008;47(1):97–104. DOI: 10.1002/hep.21966.
  39. Tremosini S, Forner A, Boix L, et al. Prospective validation of an immunohistochemical panel (glypican 3, heat shock protein 70 and glutamine synthetase) in liver biopsies for diagnosis of very early hepatocellular carcinoma. *Gut* 2012;61(10):1481–1487. DOI: 10.1136/gutjnl-2011-301862.
  40. Sangiovanni A, Manini MA, Iavarone M, et al. The diagnostic and economic impact of contrast imaging techniques in the diagnosis of small hepatocellular carcinoma in cirrhosis. *Gut* 2010;59(5):638–644. DOI: 10.1136/gut.2009.187286.
  41. Wang F, Numata K, Nakano M, et al. Diagnostic value of immunohistochemical markers in four-grade histological classification of hepatocellular carcinoma. *Res Square* 2020. DOI: 10.21203/rs.3.rs-99711/v1.
  42. Clish CB. Metabolomics: an emerging but powerful tool for precision medicine. *Cold Spring Harb Mol Case Stud* 2015;1(1):a000588. DOI: 10.1101/mcs.a000588.
  43. Beyoğlu D, Idle JR. Metabolomic and lipidomic biomarkers for premalignant liver disease diagnosis and therapy. *Metabolites* 2020;10(2):50. DOI: 10.3390/metabo10020050.
  44. Tellapuri S, Sutphin PD, Beg MS, et al. Staging systems of hepatocellular carcinoma: a review. *Indian J Gastroenterol* 2018;37(6):481–491. DOI: 10.1007/s12664-018-0915-0.
  45. Faria SC, Szklaruk J, Kaseb AO, et al. TNM/Okuda/Barcelona/UNOS/CLIP International Multidisciplinary Classification of Hepatocellular Carcinoma: concepts, perspectives, and radiologic implications. *Abdom Imaging* 2014;39(5):1070–1087. DOI: 10.1007/s00261-014-0130-0.
  46. Llovet JM, Bru C, Bruix J. Prognosis of hepatocellular carcinoma: the BCLC staging classification. *Seminars in liver disease* 1999;19(3):329–338. DOI: 10.1055/s-2007-1007122.
  47. Fonseca AL, Cha CH. Hepatocellular carcinoma: a comprehensive overview of surgical therapy. *J Surg Oncol* 2014;110(6):712–719. DOI: 10.1002/jso.23673.
  48. Vitale A, Peck-Radosavljevic M, Giannini EG, et al. Personalized treatment of patients with very early hepatocellular carcinoma. *J Hepatol* 2017;66(2):412–423. DOI: 10.1016/j.jhep.2016.09.012.
  49. Lee EC, Kim SH, Park H, et al. Survival analysis after liver resection for hepatocellular carcinoma: a consecutive cohort of 1002 patients. *J Gastroenterol Hepatol* 2017;32(5):1055–1063. DOI: 10.1111/jgh.13632.
  50. Zhang H, Han J, Xing H, et al. Sex difference in recurrence and survival after liver resection for hepatocellular carcinoma: a multicenter study. *Surgery* 2019;165(3):516–524. DOI: 10.1016/j.surg.2018.08.031.
  51. Morise Z, Aldrighetti L, Belli G, et al. Laparoscopic repeat liver resection for hepatocellular carcinoma: a multicentre propensity score-based study. *Br J Surg* 2020;107(7):889–895. DOI: 10.1002/bjs.11436.





52. Ruzzenente A, Bagante F, Ratti F, et al. Minimally invasive versus open liver resection for hepatocellular carcinoma in the setting of portal vein hypertension: results of an international multi-institutional analysis. *Ann Surg Oncol* 2020;27(9):3360–3371. DOI: 10.1245/s10434-020-08444-3.
53. El-Gendi A, El-Shafei M, El-Gendi S, et al. Laparoscopic versus open hepatic resection for solitary hepatocellular carcinoma less than 5 cm in cirrhotic patients: a randomized controlled study. *J Laparoendosc Adv Surg Tech A* 2018;28(3):302–310. DOI: 10.1089/lap.2017.0518.
54. Solaini L, Bocchino A, Cucchetti A, et al. Anatomic laparoscopic liver resection in the scenario of the hepatocellular carcinoma: a systematic review and meta-analysis. *J Laparoendosc Adv Surg Tech A* 2020;30(10):1076–1081. DOI: 10.1089/lap.2020.0562.
55. Mazzaferro V, Bhoori S, Sposito C, et al. Milan criteria in liver transplantation for hepatocellular carcinoma: an evidence-based analysis of 15 years of experience. *Liver Transpl* 2011;17(Suppl. 2):S44–S57. DOI: 10.1002/lt.22365.
56. Fahrner R, Dondorf F, Ardelit M, et al. Liver transplantation for hepatocellular carcinoma - factors influencing outcome and disease-free survival. *World J Gastroenterol* 2015;21(42):12071–12082. DOI: 10.3748/wjg.v21.i42.12071.
57. Mazzaferro V, Llovet JM, Miceli R, et al. Predicting survival after liver transplantation in patients with hepatocellular carcinoma beyond the Milan criteria: a retrospective, exploratory analysis. *Lancet Oncol* 2009;10(1):35–43. DOI: 10.1016/S1470-2045(08)70284-5.
58. Facciuto ME, Rochon C, Pandey M, et al. Surgical dilemma: liver resection or liver transplantation for hepatocellular carcinoma and cirrhosis. Intention-to-treat analysis in patients within and outwith Milan criteria. *HPB* 2009;11(5):398–404. DOI: 10.1111/j.1477-2574.2009.00073.x.
59. Guy J, Kelley RK, Roberts J, et al. Multidisciplinary management of hepatocellular carcinoma. *Clin Gastroenterol Hepatol* 2012;10(4):354–362. DOI: 10.1016/j.cgh.2011.11.008.
60. Ofosu A, Gurakar A. Current concepts in hepatocellular carcinoma and liver transplantation: a review and 2014 update. *Euroasian J Hepatogastroenterol* 2015;5(1):19–25. DOI: 10.5005/jp-journals-10018-1123.
61. Sapisochin G, Castells L, Dopazo C, et al. Single HCC in cirrhotic patients: liver resection or liver transplantation? Long-term outcome according to an intention-to-treat basis. *Ann Surg Oncol* 2013;20(4):1194–1202. DOI: 10.1245/s10434-012-2655-1.
62. Al-Ameri AAM, Wei X, Wen X, et al. Systematic review: risk prediction models for recurrence of hepatocellular carcinoma after liver transplantation. *Transpl Int* 2020;33(7):697–712. DOI: 10.1111/tri.13585.
63. Mazzaferro V, Regalia E, Doci R, et al. Liver transplantation for the treatment of small hepatocellular carcinomas in patients with cirrhosis. *N Engl J Med* 1996;334(11):693–699. DOI: 10.1056/NEJM199603143341104.
64. Kasugai H, Osaki Y, Oka H, et al. Severe complications of radiofrequency ablation therapy for hepatocellular carcinoma: an analysis of 3,891 ablations in 2,614 patients. *Oncology* 2007;72(Suppl. 1):72–75. DOI: 10.1159/000111710.
65. Maeda M, Saeki I, Sakaida I, et al. Complications after radiofrequency ablation for hepatocellular carcinoma: a multicenter study involving 9,411 Japanese patients. *Liver Cancer* 2020;9(1):50–62. DOI: 10.1159/000502744.
66. Shiina S, Tateishi R, Arano T, et al. Radiofrequency ablation for hepatocellular carcinoma: 10-year outcome and prognostic factors. *Am J Gastroenterol* 2012;107(4):569–577; quiz 578. DOI: 10.1038/ajg.2011.425.
67. Hasegawa K, Kokudo N, Makuuchi M, et al. Comparison of resection and ablation for hepatocellular carcinoma: a cohort study based on a Japanese nationwide survey. *J Hepatol* 2013;58(4):724–729. DOI: 10.1016/j.jhep.2012.11.009.
68. Lucchina N, Tsetis D, Ierardi AM, et al. Current role of microwave ablation in the treatment of small hepatocellular carcinomas. *Ann Gastroenterol* 2016;29(4):460–465. DOI: 10.20524/aog.2016.0066.
69. Tan W, Deng Q, Lin S, et al. Comparison of microwave ablation and radiofrequency ablation for hepatocellular carcinoma: a systematic review and meta-analysis. *Int J Hyperthermia* 2019;36(1):264–272. DOI: 10.1080/02656736.2018.1562571.
70. Glassberg MB, Ghosh S, Clymer JW, et al. Microwave ablation compared with radiofrequency ablation for treatment of hepatocellular carcinoma and liver metastases: a systematic review and meta-analysis. *Onco Targets Ther* 2019;12:6407–6438. DOI: 10.2147/OTT.S204340.
71. Ricci AD, Rizzo A, Bonucci C, et al. The (eternal) debate on microwave ablation versus radiofrequency ablation in BCLC-A hepatocellular carcinoma. *In Vivo (Athens, Greece)* 2020;34(6):3421–3429. DOI: 10.21873/invivo.12181.
72. Kamal A, Elmoety AAA, Rostom YAM, et al. Percutaneous radiofrequency versus microwave ablation for management of hepatocellular carcinoma: a randomized controlled trial. *J Gastrointest Oncol* 2019;10(3):562–571. DOI: 10.21037/jgo.2019.01.34.
73. Forner A, Gilabert M, Bruix J, et al. Treatment of intermediate-stage hepatocellular carcinoma. *Nat Rev Clin Oncol* 2014;11(9):525–535. DOI: 10.1038/nrclinonc.2014.122.
74. Llovet JM, Bruix J. Systematic review of randomized trials for unresectable hepatocellular carcinoma: chemoembolization improves survival. *Hepatology (Baltimore, Md.)* 2003;37(2):429–442. DOI: 10.1053/jhep.2003.50047.
75. Llovet JM, Real MI, Montaña X, et al. Arterial embolisation or chemoembolisation versus symptomatic treatment in patients with unresectable hepatocellular carcinoma: a randomised controlled trial. *Lancet (London, England)* 2002;359(9319):1734–1739. DOI: 10.1016/S0140-6736(02)08649-X.
76. LoCM, Ngan H, Tso WK, et al. Randomized controlled trial of transarterial lipiodol chemoembolization for unresectable hepatocellular carcinoma. *Hepatology (Baltimore, Md.)* 2002;35(5):1164–1171. DOI: 10.1053/jhep.2002.33156.
77. Bruix J, Sala M, Llovet JM, et al. Chemoembolization for hepatocellular carcinoma. *Gastroenterology* 2004;127(5 Suppl 1):S179–S188. DOI: 10.1053/j.gastro.2004.09.032.
78. Boyvat F. Interventional radiologic treatment of hepatocellular carcinoma. *Exp Clin Transplant* 2017;15(Suppl. 2):25–30. DOI: 10.6002/ect.TOND16.L8.
79. Gao ZH, Bai DS, Jiang GQ, et al. Review of preoperative transarterial chemoembolization for resectable hepatocellular carcinoma. *World J Hepatol* 2015;7(1):40–43. DOI: 10.4254/wjh.v7.i1.40.
80. Puppala S. Management of post-embolization syndrome. In: Kessel D, Ray C, editors. *Transcatheter embolization and therapy. Techniques in interventional radiology*. London: Springer; 2010. DOI: 10.1007/978-1-84800-897-7\_13.
81. Lammer J, Malagari K, Vogl T, et al. Prospective randomized study of doxorubicin-eluting-bead embolization in the treatment of hepatocellular carcinoma: results of the PRECISION V study. *Cardiovasc Intervent Radiol* 2010;33(1):41–52. DOI: 10.1007/s00270-009-9711-7.
82. Varela M, Real MI, Burrel M, et al. Chemoembolization of hepatocellular carcinoma with drug eluting beads: efficacy and doxorubicin pharmacokinetics. *J Hepatol* 2007;46(3):474–481. DOI: 10.1016/j.jhep.2006.10.020.
83. Malagari K, Pomoni M, Moschouris H, et al. Chemoembolization with doxorubicin-eluting beads for unresectable hepatocellular carcinoma: five-year survival analysis. *Cardiovasc Intervent Radiol* 2012;35(5):1119–1128. DOI: 10.1007/s00270-012-0394-0.
84. Raoul JL, Forner A, Bolondi L, et al. Updated use of TACE for hepatocellular carcinoma treatment: how and when to use it based on clinical evidence. *Cancer Treat Rev* 2019;72:28–36. DOI: 10.1016/j.ctrv.2018.11.002.
85. Haubold J, Reinboldt MP, Wetter A, et al. DSM-TACE of HCC: evaluation of tumor response in patients ineligible for other systemic or loco-regional therapies. *DSM-TACE des HCC: Bewertung des Tumoransprechens von Patienten mit Kontraindikationen gegen andere systemische oder lokoregionale Therapien*. *Rofo* 2020;192(9):862–869. DOI: 10.1055/a-1111-9955.

86. Gross A, Albrecht T. Transarterial chemoembolisation (TACE) with degradable starch microspheres (dsm) and anthracycline in patients with locally extensive hepatocellular carcinoma (hcc): safety and efficacy. *Cardiovasc Intervent Radiol* 2020;43(3):402–410. DOI: 10.1007/s00270-019-02364-w.
87. Iezzi R, Pompili M, Rinninella E, et al. TACE with degradable starch microspheres (DSM-TACE) as second-line treatment in HCC patients dismissing or ineligible for sorafenib. *Eur Radiol* 2019;29(3):1285–1292. DOI: 10.1007/s00330-018-5692-8.
88. Levi Sandri GB, Ettorre GM, Giannelli V, et al. Trans-arterial radioembolization: a new chance for patients with hepatocellular cancer to access liver transplantation, a world review. *Transl Gastroenterol Hepatol* 2017;2:98. DOI: 10.21037/tgh.2017.11.11.
89. Cappelli A, Pettinato C, Golfieri R. Transarterial radioembolization using yttrium-90 microspheres in the treatment of hepatocellular carcinoma: a review on clinical utility and developments. *J Hepatocell Carcinoma* 2014;1:163–182. DOI: 10.2147/JHC.S50472.
90. Sundram FX, Buscombe JR. Selective internal radiation therapy for liver tumours. *Clin Med (London, England)* 2017;17(5):449–453. DOI: 10.7861/clinmedicine.17-5-449.
91. Abdel-Rahman O, Elsayed Z. Yttrium-90 microsphere radioembolisation for unresectable hepatocellular carcinoma. *Cochrane Database Syst Rev* 2020;1(1):CD011313. DOI: 10.1002/14651858.CD011313.pub3.
92. Salem R, Lewandowski RJ, Kulik L, et al. Radioembolization results in longer time-to-progression and reduced toxicity compared with chemoembolization in patients with hepatocellular carcinoma. *Gastroenterology* 2011;140(2):497–507.e2. DOI: 10.1053/j.gastro.2010.10.049.
93. Benson AB, D'Angelica MI, Abbott DE, et al. NCCN guidelines insights: hepatobiliary cancers, version 1.2017. *J Natl Compr Canc Netw* 2017;15(5):563–573. DOI: 10.6004/jnccn.2017.0059.
94. Chopra S, George K, Engineer R, et al. Stereotactic body radiotherapy for inoperable large hepatocellular cancers: results from a clinical audit. *Br J Radiol* 2019;92(1101):20181053. DOI: 10.1259/bjr.20181053.
95. Yeung CSY, Chiang CI, Wong NSM, et al. Palliative liver radiotherapy (RT) for symptomatic hepatocellular carcinoma (HCC). *Sci Rep* 2020;10(1):1254. DOI: 10.1038/s41598-020-58108-1.
96. Culleton S, Jiang H, Haddad CR, et al. Outcomes following definitive stereotactic body radiotherapy for patients with Child-Pugh B or C hepatocellular carcinoma. *Radiother Oncol* 2014;111(3):412–417. DOI: 10.1016/j.radonc.2014.05.002.
97. Song JH, Jeong BK, Choi HS, et al. Defining radiation-induced hepatic toxicity in hepatocellular carcinoma patients treated with stereotactic body radiotherapy. *J Cancer* 2017;8(19):41551. DOI: 10.7150/jca.21561.
98. Yoon SM, Kim SY, Lim YS, et al. Stereotactic body radiation therapy for small ( $\leq 5$  cm) hepatocellular carcinoma not amenable to curative treatment: results of a single-arm, phase II clinical trial. *Clin Mol Hepatol* 2020;26(4):506–515. DOI: 10.3350/cmh.2020.0038.
99. Lee J, Shin IS, Yoon WS, et al. Comparisons between radiofrequency ablation and stereotactic body radiotherapy for liver malignancies: meta-analyses and a systematic review. *Radiother Oncol* 2020;145:63–70. DOI: 10.1016/j.radonc.2019.12.004.
100. El Alfy E, Bondiau PY, Rostom YA, et al. Results of stereotactic body radiotherapy (SBRT) for management of primary and secondary hepatic tumors: analysis of early outcomes. *J Clin Oncol* 2015;33(15 Suppl.). DOI: 10.1200/jco.2015.33.15\_suppl.e15160.
101. Bujold A, Massey CA, Kim JJ, et al. Sequential phase I and II trials of stereotactic body radiotherapy for locally advanced hepatocellular carcinoma. *J Clin Oncol* 2013;31(13):1631–1639. DOI: 10.1200/JCO.2012.44.1659.
102. Llovet JM, Ricci S, Mazzaferro V, et al. Sorafenib in advanced hepatocellular carcinoma. *N Engl J Med* 2008;359(4):378–390. DOI: 10.1056/NEJMoa0708857.
103. Raoul JL, Bruix J, Gretten TF, et al. Relationship between baseline hepatic status and outcome, and effect of sorafenib on liver function: SHARP trial subanalyses. *J Hepatol* 2012;56(5):1080–1088. DOI: 10.1016/j.jhep.2011.12.009.
104. Bruix J, Raoul JL, Sherman M, et al. Efficacy and safety of sorafenib in patients with advanced hepatocellular carcinoma: subanalyses of a phase III trial. *J Hepatol* 2012;57(4):821–829. DOI: 10.1016/j.jhep.2012.06.014.
105. Reig M, Torres F, Rodriguez-Lope C, et al. Early dermatologic adverse events predict better outcome in HCC patients treated with sorafenib. *J Hepatol* 2014;61(2):318–324. DOI: 10.1016/j.jhep.2014.03.030.
106. Kudo M, Finn RS, Qin S, et al. Lenvatinib versus sorafenib in first-line treatment of patients with unresectable hepatocellular carcinoma: a randomised phase 3 non-inferiority trial. *Lancet (London, England)* 2018;391(10126):1163–1173. DOI: 10.1016/S0140-6736(18)30207-1.
107. Bi F, Qin S, Gu S, et al. Donafenib versus sorafenib as first-line therapy in advanced hepatocellular carcinoma: an open-label, randomized, multicenter phase II/III trial. *J Clin Oncol* 2020;38(15\_suppl):4506–4506. DOI: 10.1200/JCO.2020.38.15\_suppl.4506.
108. Bruix J, Qin S, Merle P, et al. Regorafenib for patients with hepatocellular carcinoma who progressed on sorafenib treatment (RESORCE): a randomised, double-blind, placebo-controlled, phase 3 trial. *Lancet (London, England)* 2017;389(10064):56–66. DOI: 10.1016/S0140-6736(16)32453-9.
109. Abou-Alfa GK, Meyer T, Cheng AL, et al. Cabozantinib in patients with advanced and progressing hepatocellular carcinoma. *N Engl J Med* 2018;379(1):54–63. DOI: 10.1056/NEJMoa1717002.
110. Zhu AX, Kang YK, Yen CJ, et al. Ramucicromab after sorafenib in patients with advanced hepatocellular carcinoma and increased  $\alpha$ -fetoprotein concentrations (REACH-2): a randomised, double-blind, placebo-controlled, phase 3 trial. *Lancet Oncol* 2019;20(2):282–296. DOI: 10.1016/S1470-2045(18)30937-9.
111. El-Khoueiry AB, Sangro B, Yau T, et al. Nivolumab in patients with advanced hepatocellular carcinoma (CheckMate 040): an open-label, non-comparative, phase 1/2 dose escalation and expansion trial. *Lancet (London, England)* 2017;389(10088):2492–2502. DOI: 10.1016/S0140-6736(17)31046-2.
112. Finn RS, Qin S, Ikeda M, et al. Atezolizumab plus bevacizumab in unresectable hepatocellular carcinoma. *N Engl J Med* 2020;382(20):1894–1905. DOI: 10.1056/NEJMoa1915745.
113. Yau T, Kang YK, Kim TY, et al. Efficacy and safety of nivolumab plus ipilimumab in patients with advanced hepatocellular carcinoma previously treated with sorafenib: the Check Mate 040 randomized clinical trial. *JAMA Oncol* 2020;6(11):e204564. DOI: 10.1001/jamaoncol.2020.4564.
114. Llovet JM, Kudo M, Cheng AL, et al. Lenvatinib (len) plus pembrolizumab (pembro) for the first-line treatment of patients (pts) with advanced hepatocellular carcinoma (HCC): phase 3 LEAP-002 study. *J Clin Oncol* 2019;37(15\_suppl.):TPS4152. DOI: 10.1200/JCO.2019.37.15\_suppl.TPS4152.
115. Kelley RK, Abou-Alfa GK, Bendell JC, et al. Phase I/II study of durvalumab and tremelimumab in patients with unresectable hepatocellular carcinoma (HCC): phase I safety and efficacy analyses. *J Clin Oncol* 2017;35(15\_suppl):4073–4073. DOI: 10.1200/JCO.2017.35.15\_suppl.4073.
116. Qin S, Chen Z, Liu Y, et al. A phase II study of anti-PD-1 antibody camrelizumab plus FOLFOX4 or GEMOX systemic chemotherapy as first-line therapy for advanced hepatocellular carcinoma or biliary tract cancer. *J Clin Oncol* 2019;37(15\_suppl):4074–4074. DOI: 10.1200/JCO.2019.37.15\_suppl.4074.
117. Adeniji N, Dhanasekaran R. Genomic Landscape of HCC. *Curr Hepatol Rep* 2020;1–4. DOI: 10.1007/s11901-020-00553-7
118. Mei Q, Chen M, Lu X, et al. An open-label, single-arm, phase I/II study of lower-dose decitabine based therapy in patients with advanced hepatocellular carcinoma. *Oncotarget* 2015;6(18):16698–16711. DOI: 10.18632/oncotarget.3677.
119. Liu A, Wu Q, Peng D, et al. A novel strategy for the diagnosis, prognosis, treatment, and chemoresistance of hepatocellular carcinoma: DNA methylation. *Med Res Rev* 2020;40(5):1973–2018. DOI: 10.1002/med.21696.