



THE AGA KHAN UNIVERSITY

eCommons@AKU

Section of Neurosurgery

Department of Surgery

2-2001

Vestibular schwannomas: Clinical presentation, management and outcome

M S. Awan

H U. Qureshi

A A. Sheikh

M M. Ali

Follow this and additional works at: https://ecommons.aku.edu/pakistan_fhs_mc_surg_neurosurg



Part of the [Neurology Commons](#), [Neurosurgery Commons](#), [Otolaryngology Commons](#), and the [Surgery Commons](#)

Vestibular Schwannomas: Clinical Presentation, Management and Outcome

M.S. Awan, H.U. Qureshi, A.A. Sheikh, M.M. Ali (Sections of Neurosurgery and Otolaryngology. Department of Surgery, The Aga Khan University, Karachi.)

Abstract

Objective: To review the demographic trends clinical spectrum, diagnosis, management and outcome of patients with vestibular Schwannoma and to identify areas where improvements are needed.

Methods: All patients with vestibular schwannoma admitted to the Aga Khan University Hospital over the past 11 years were reviewed retrospectively.

Results: The age range of majority of 22 patients analyzed, was 41-50 years (23%). Hearing loss was the most common presenting symptom (96%). Other clinical features included cranial nerve palsies (59%) and headache (55%). Fifty percent had signs of raised intracranial pressure. Neuroimaging revealed "Stage IV b" (tumor distorting the brainstem and compressing the 4th ventricle) in 50% cases. Neurosurgical intervention was carried out in 86%; mainly using the retrosigmoid approach. Postoperative complications included facial nerve palsy in 13 (65%) and hydrocephalus in 5 (25%) patients. Hearing determined clinically was preserved in three patients (14%). One patient died during the inpatient stay.

Conclusion: Presentation of these patients is late and the outcome is poor (JPMA 51:63; 2001).

Introduction

Vestibular Schwannoma is a benign tumor arising from the schwann cells of the vestibular nerves, usually within the internal auditory canal, It accounts for about eight percent of all intracranial tumors and its incidence is estimated to be around one to five per 100,000 people per year¹.

Hearing loss is the most common initial symptom of this tumor²⁻⁴. Usually there is a gradual hearing reduction, but a sudden loss can occur or the hearing may be fluctuant¹. Other symptoms include tinnitus, dizziness, unsteadiness and a sensation of fullness in the ear. As the tumor enlarges, it begins to impinge upon the trigeminal nerve, subsequently loss of corneal sensation and numbness or altered sensation on the face and tongue develops. With larger tumors, symptoms of raised intracranial pressure, involvement of the seventh and various caudal cranial nerves may occur¹. Diagnosis is based on clinical presentation and supporting evidence from various audiometric studies including brainstem evoked response potentials and neuroimaging.

In the early twentieth century, the picture was one of the unmitigated gloom, with large tumors presenting late and removed with such dreadful results that even to consider operating on a fit person with a small tumor was regarded inappropriate⁵. With advances in diagnostic and surgical techniques, the quest for preservation of the facial nerve and maintenance of useful hearing in certain cases has become possible⁵.

This study presents the demographic trends, clinical spectrum, diagnostic modes, management modalities and outcome of patients with vestibular schwannoma and to provide an authentic account of the local pattern of disease and results of management and comparison of local results with current international standards to identify the areas where improvements are needed.

Patients and Methods

This is a retrospective log review of all patients presenting with Vestibular Schwannoma over the last 11 years. Selection of patients was based on the ICD-9-CM code of classification. Diagnosis was made on clinical presentation, imaging and confirmatory histopathology reports, where available in all operated patients. All patients presenting with Vestibular Schwannoma over the last 11 years were included in our study. Major variables reviewed were age, gender, symptom presentation, clinical assessment, audiometry, laboratory and radiological investigation, tumor size at presentation, modalities of treatment, postoperative complications and outcome.

Data extraction performas were prepared to retrieve information for this purpose. If patients were admitted on multiple occasions with vestibular schwannoma, only the first admission was reviewed. Patients on admission were classified into three clinical stages: Involvement of cranial nerve VIII alone (Mild), multiple cranial nerve palsies (Moderate) and raised intracranial pressure, with or without multiple cranial nerve palsies (Severe).

Radiological staging on computerized tomography/ magnetic resonance imaging followed this criteria⁵: T1: Intrameatal tumor, T2: Intra-extrameatal tumor, T3a: Filling the cerebellopontine cistern, T3b: Reaching the brainstem, T4a: Compressing the brainstem and T4b: Distorting the brainstem and compressing the 4th ventricle.

Statistical analysis

Data entry and analysis was carried out using the SPSS software (Release 8.0, standard version, copyright SPSS Inc., 1989-97). All descriptive data is presented in the form of frequency tables and figures. All percentages that are given in the text have been rounded up to the nearest whole number.

Results

Demographics

Twenty-two patients with vestibular schwannoma were admitted to Aga Khan University Hospital between January 1989 and December 1999. Their mean age was 47 years (SD±13) and the male to female ratio 1 : 1.4. The age and gender distribution is summarized in Figure 1.

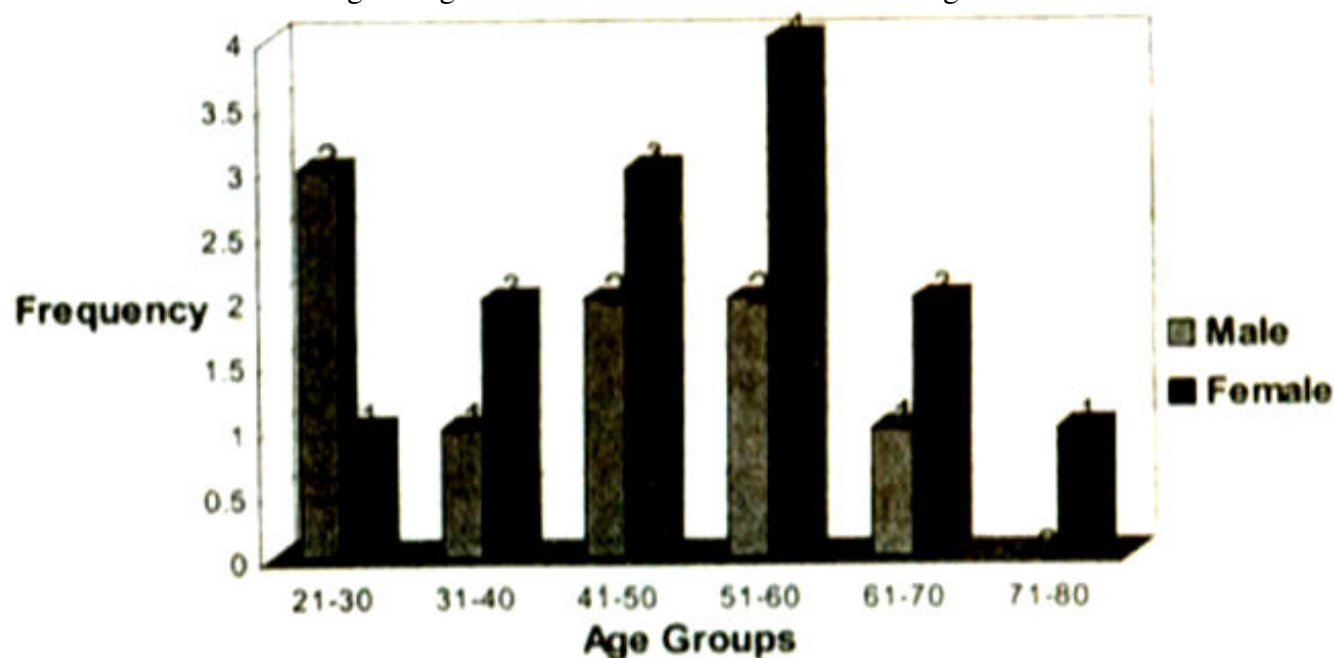


Figure 1 Age and gender distribution of 22 patients with vestibular schwannoma

Majority of the patients (58%) were from Karachi City, 18% belonged to North West Frontier Province (NWFP) and Afghanistan, 14% belonged to Balochistan and 5% each to Sind and Punjab.

Clinical Presentation

The major clinical features are shown in Figure 2.

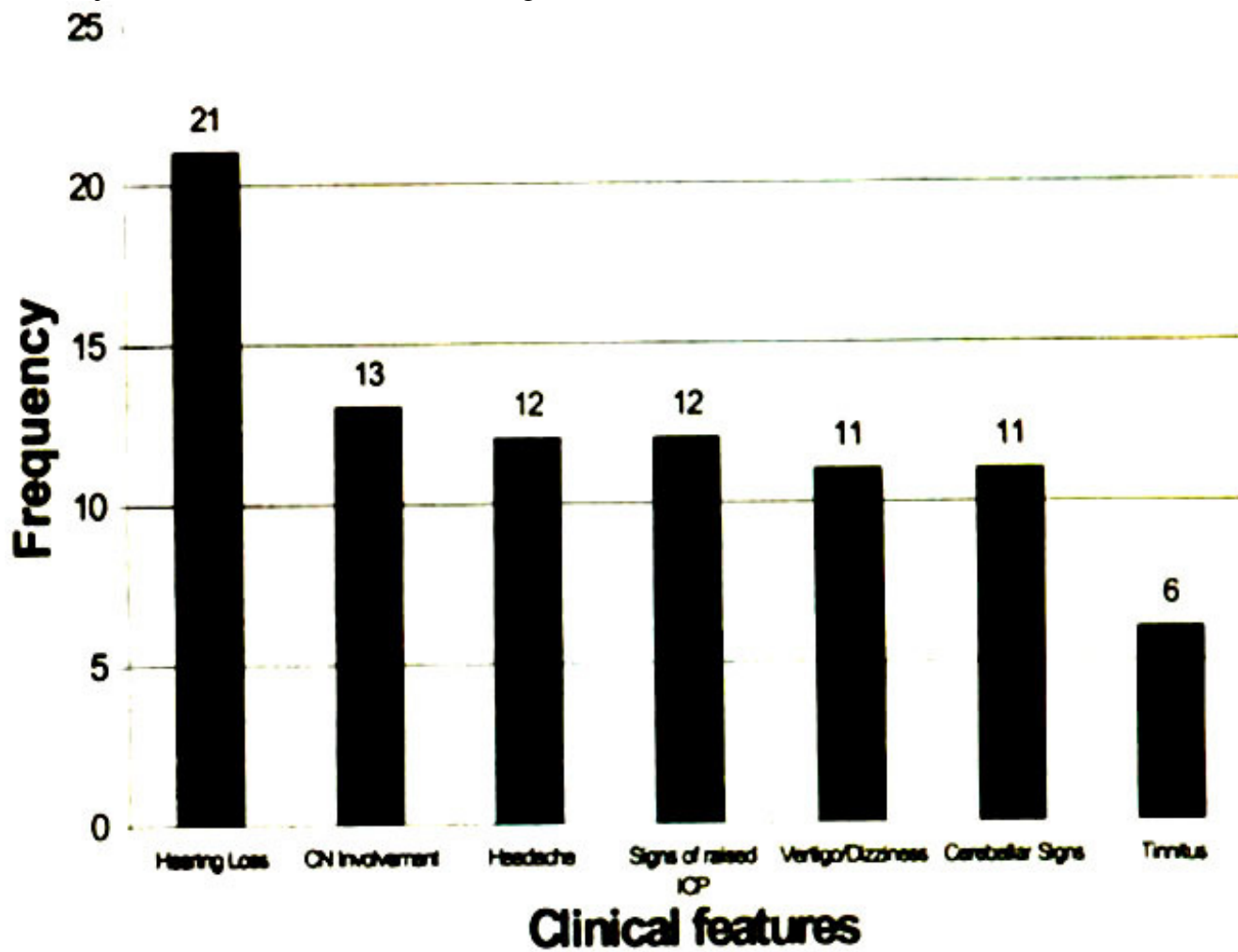


Figure 2 Clinical presentation of 22 patients with vestibular schwannoma

Hearing loss, was present in 21 patients (96%), right side was involved in 10 patients (48%) and the left in 11(52%) patients. The mean duration of hearing loss prior to presentation was 104 weeks. Amongst the 19 patients (87%) in whom the character of the hearing loss was recorded, 17 (89%) had a history of progressive hearing loss and 2 patients (11%) had an acute attack with total deafness. Twelve patients (55%) reported to have headaches. Eighty two percent of these had episodic headaches while 9% each had continuous and morning headaches respectively. The mean duration of headaches was 37 weeks. Vertigo was reported in 11 patients (50%) with mean duration of 92 weeks. All of these patients complained of a positional vertigo. Tinnitus was present in 6 patients (27%).

Amongst the signs, 13 patients (59%) had cranial nerve involvement. The frequency distribution of the various cranial nerve palsies is summarized in Figure 3.

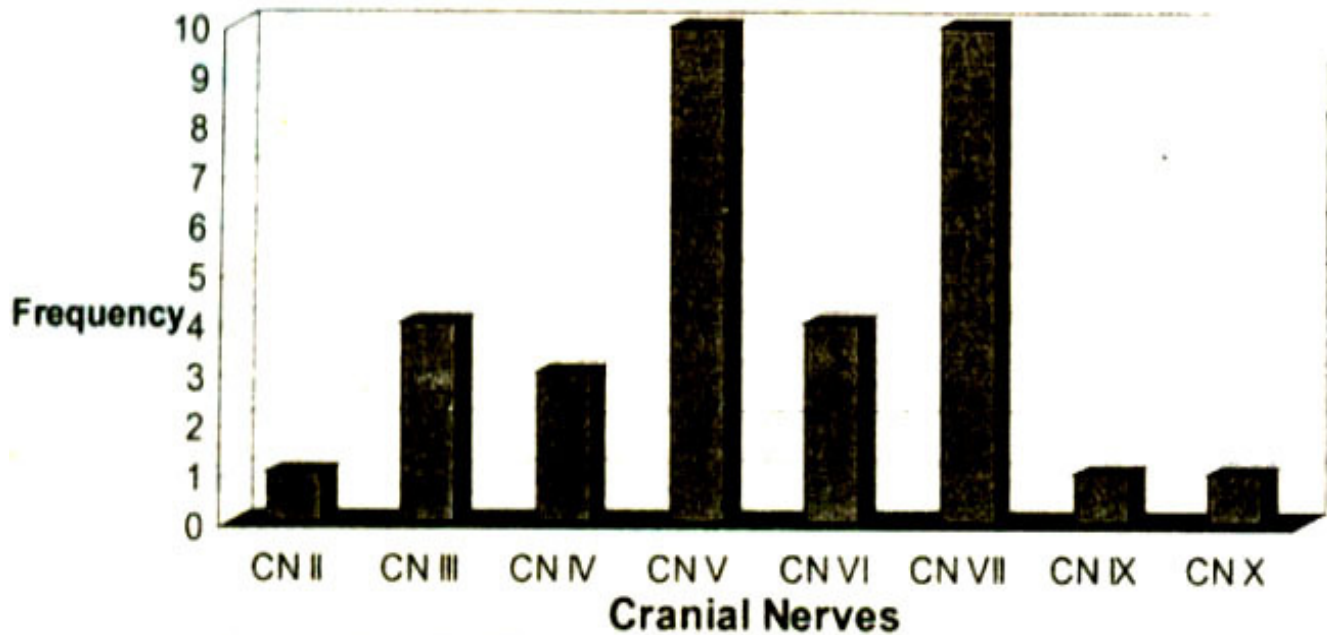


Figure 3 Cranial nerve involvement in 22 patients with vestibular schwannoma.

The trigeminal and facial nerves were the most commonly involved, with 10 patients in each group. With respect to the trigeminal nerve, diminished or absent corneal reflex was identified in 7 (70%), altered sensation of face in 6 (60%), weakness of muscle of mastication in 2 (20%) and neuralgia in one (10%) patient.

Amongst those with facial nerve palsy, weakness of facial muscles was identified in eight patients (80%), anesthesia of external auditory canal in two (20%) and taste impairment in one (10%). Cerebellar signs were present in 11 patients (50%). Nine patients (81%) had gait disturbances, 4 (36%) had nystagmus and 2 (18%) had ataxia.

Clinically, raised intra cranial pressure was suspected in 12 patients. Clinical features pointing towards raised intracranial pressure were headaches in all, nausea / vomiting in 9 patients (75%), papilledema in three (25%) and drowsiness in another three (25%) cases. Two patients (9%) had some peripheral motor deficit while one (5%) had both motor and sensory deficits. All patients were categorized into mild, moderate and severe presentations. Six patients (27%) had a mild, 5 (23%) had moderate and 11(50%) had a severe presentation.

One patient (5%) gave a history of head trauma prior to his symptoms. None of the patients had a recorded positive family history for any kind of malignancy.

Comorbids were identified in nine of our patients (41%). Amongst these, 6 patients (66%) had hypertension, 4 (44%) diabetes mellitus and one (11%) each had asthma and ischemic heart disease. Only one patient (11%) had neurofibromatosis with a unilateral tumor. A total of three patients had multiple comorbids.

Diagnosis

Audiometric studies were performed in 5 patients (23%). On pure tone audiometry (PTA), all had a "dead ear". Brainstem evoked response audiometry was done in two patients (40%). Latency of response waves and interauricular latency of greater than 0.2 milliseconds was identified in both cases. Diagnostic imaging was performed in 21 patients, which included computed tomography in 11 (52%) and magnetic resonance imaging in 7 (33%) patients. One patient had CT and roentgenography (4%) and 2 (10%) had both CT and MRI done.

The size of the tumor, as determined by imaging, was categorized into less than 2x3 cms and greater than 2x3 cms. Six patients (29%) had a tumor less than 2x3 cms while 15 (71%) had a larger sized

tumor. Radiological staging, as defined earlier, has been summarized in Table 1.

Table 1. Radiological Staging of 21 patients undergoing neuroimaging.

Stage of the tumor	Frequency	%
T1	1	4.5
T2	3	13.6
T3a	3	13.6
T3b	1	4.5
T4a	0	0
T4b	9	40.9
Don't Know	4	18.2

Amongst the 18 patients in which staging was recorded, majority (50%) had a stage T4b tumor. Imaging reports commented on hydrocephalus in 19 patients; 9 patients (47%) were reported to have hydrocephalus. The location of jugular foramen in relation to the tumor was not reported in any of the radiology reports.

Surgical management alone was done in 19 patients (86%) and a combination of surgery and radiotherapy was done in two patients (9%). One patient (5%) was managed conservatively. Suboccipital retrosigmoid approach was most favored, being performed in 19 patients (91%). In one patient (5%) tumor removal was by the translabyrinthine approach. In another patient only VP shunting procedure was performed for symptomatic relief of hydrocephalus.

Intraoperatively, the tumor was found to be adherent to adjacent tissues in 11 (55%), vascular in 10 (50%), encapsulated in 4 (20%) and hemorrhagic in 3 (15%) patients. In one patient each, the tumor was found to be cystic and necrotic, respectively. All excised tumors sent for histopathology were schwannomas. None of the samples revealed any form of malignant change.

Postoperatively, radiological imaging was done in 10 patients (48%) only. Amongst these, 3 (30%) had a complete resection and 7 (70%) showed a partial / subtotal resection of tumor. Hearing preservation determined clinically was found to be intact in 3 patients (14%). A variety of postoperative complications were identified; these have been listed in Table 2.

Table 2. Postoperative complications in 19 patients undergoing neurosurgery.

Post-operative Complications	Frequency	%
Facial Palsy	12	63
Hydrocephalus	5	26
CSF Leakage	4	21
Vertigo	4	21
Seizures	2	11
Meningitis	2	11

Amongst the postoperative complications, facial nerve palsy was identified in 13 patients (65%) and hydrocephalus in 5 (25%). One patient (5%) died during his inpatient stay in the hospital.

Discussion

This study has brought forth many important aspects of vestibular schwannomas particularly those which revolve around a late presentation and an advanced staged tumor. The fact that only 22 patients surfaced to the AKUH in the last 11 years can possibly be explained by the inaccessibility to the health care system available to a majority of our population. Screening and referral systems are also inadequate. These factors give an erroneous picture of true incidence of this tumor next to negligible. Other Western studies in contrast have enrolled more than 1000 patients in a time frame of 16 years⁶. In this series of 22 patients the mean age, range and the male to female ratio is similar to other reported series⁶⁻⁹, but vestibular schwannoma were associated with pregnancy¹⁰. The association between ethnicity and the incidence of this tumor has not yet been reported. In this series 18% of patients belonged to the NWFP and Afghanistan, indicating to establish this pattern a further prevalence study is needed.

The symptomatology in this series is consistent with Western data. The proportion of patients with hearing loss and dizziness/vertigo are similar to other studies^{1-3,5,9} which report a range of 80-96% for hearing loss and 37-61% for dizziness which is similar to this study where 96% had hearing loss and 50% dizziness. However, 27% of patients complained of tinnitus in contrast to 40-90% reported by others^{1,6,9}. Investigators revealed an inverse association between tinnitus and tumor extension; patients with smaller tumors having higher rates of tinnitus⁶. Many more patients (55%) in this series complained of headaches compared to 5-30% reported by others¹. Both these findings can solely be

attributed to a late presentation and a larger tumor size. Two of patients presented with sudden hearing loss. Vestibular schwannomas should be considered as a differential for this symptom^{11,12}.

With the expansion of tumor in the cerebellopontine angle, other cranial nerves and structures are frequently involved. The sensory part of the trigeminal nerve is usually the first cranial nerve (CN), other than CN VIII³. This manifests as diminished or absent corneal reflexes and anesthesia of the ipsilateral face. Continued growth shows involvement of caudal cranial nerves. CN VII shows resilience even under extreme pressure and stretching with the sensory division getting involved first³. Other series have reported about 20% for CN V and 6-33% for CN VII^{1,6,9}. This series shows an equal number of patients with some form of trigeminal and facial nerve involvement (45% each). Also, in contrast to other settings where signs of raised intracranial pressure (RICP) rarely bring the patient to the hospital, 55% of patients in this study had clinical evidence of RICP at the time of admission. These findings because of high rate (>50%) of large tumors and late referrals. These large tumors caused brain stem compression and obstructive hydrocephalus.

Head CT/MRI has become the "gold standard" for diagnosing such tumors. In today's cost-containment environment, it is impossible for every patient with nonspecific complaints to undergo these expensive tests. Hence it is important to use preliminary screening tests with a high degree of sensitivity for retrocochlear pathology³. Unfortunately, more than 50% of our patients presented as neurosurgical emergencies with raised intracranial pressure. This explains the fact that only 23% of our patients underwent basic audiometric tests. All of these had a "dead ear" and hence speech discrimination could not be assessed. BERA is regarded to be a highly sensitive screening test^{3,7,13-5}. Similarly the value of a plain X-ray film of the internal auditory canal should not be underestimated. Accuracy of good quality plain film is approximately 90%³. As little as one-millimeter difference between the two internal auditory canals may be significant³. It is, therefore, recommended that these cheaper screening modalities should be considered first in most patients. With an abnormality in any one of these, CT or MRI should be performed next. However, in highly suspected patients, preliminary tests need to be bypassed. CT/MRI are important to stage the tumor and assessing the prognosis⁴. Moreover, it guides decisions regarding surgical management. The angle of petrous bones helps in positioning the patient and the extent of cerebellar manipulation⁴. In addition, the occurrence of a high jugular bulb is not infrequent. Preoperative neuroimaging prevents inadvertent damage to the bulb while the posterior wall of the internal auditory canal is drilled⁴. Therefore, these findings should specifically be looked for and should be reported by the radiologists.

Treatment options considered in a patient with vestibular schwannoma are surgery, radiation and observation¹. Owing to lack of radiation facilities in our part of the world, this has not yet received much recognition. The standard treatment therefore remains surgical excision, using one of the several approaches: including posterior fossa, middle fossa or translabyrinthine. Most of our patients (91%) underwent the posterior fossa (suboccipital /retrosigmoid) approach, which is commonly used by most neurosurgeons⁴. Posterior and middle cranial fossa approaches can offer hearing preservation. Posterior fossa approach preserves hearing ranging from 6-58% and that of middle fossa from 31-59%¹⁶. A study from Yale School of Medicine has established that a tumor of 1.5 cms or less has a 50% chance of hearing preservation¹⁶. The translabyrinthine approach, which was offered in one patient, has the advantage of better identification and preservation of CN VII^{1,4,6,16}. However, with this approach, deafness is inevitable.

The management of vestibular schwannoma in local setting is mainly for saving life in majority of the patients. Facial palsy was recorded in 65% of the postoperative patients and hearing could only be preserved in 14%. Preservation of facial nerve and hearing and reduction in the various postoperative complications can only be made possible with early detection of the tumor. Good access to health care

system. efficient screening and early referral are pre-requisites for achievement of these aims.

Acknowledgements

We would like to acknowledge Professor Naim-urRehman for allowing us to access all cases of vestibular schwannoma and giving us his valuable and expert advice throughout this project.

References

1. Wiegand, D.A., Oiemann, R., Fickel, V. Surgical treatment of acoustic neuroma (vestibular schwannoma) in the United States Report from the Acoustic Neuroma Registry. *Laryngoscope*, 1996;106(1 Pt I): 58-66,
2. Roland, P.S., Glasscock, M E. Acoustic Neuroma. In: Paparella, M M., Shumrick, D.A., Gluckman, J.L., et al. eds. *Otolaryngology (Vol II)*. 3rd ed, Philadelphia, W.B. Saunders Company, 1991. pp. 1775-1787.
3. Tew, J.M., Sawaya, R., Pensak, M.L. Neurosurgery of the Head and Neck In: Paparella, M.M., Shumrick, D.A., Gluckman, J.L., et al eds. *Otolaryngology (Vol IV)*. 3rd ed. Philadelphia. W.B. Saunders Company, 1991. pp. 2983-3031.
4. Eisenberg, M.B., Catalano, P.J., Post, K.L) Management of Acoustic Schwannomas In: Tindall, G.T., Cooper, P.R., Barrow, D.L. eds. *The Practice of Neurosurgery (Vol 1)*. Baltimore, Williams and Wilkins, 1996, pp. 995- 1004
5. Dutton, I.E., Rainsden, R.T., Lye, R.II., et al. Acoustic neuroma (schwannoma) surgery 1978-1990. *J. Laryngol Otol* 1991;105:165-73.
6. Matties, C., Samii, M. Management of 1000 vestibular schwannomas (acoustic neuromas). clinical presentation. *Neurosurgery*, 1997;40: 1-10.
7. Burkey, J.M., Rizer, F.M., Schuring, A.G, Acoustic reflexes, auditory brainstem response, and MRI in the evaluation of acoustic neuromas. *Laryngoscope*. 1996;106:839-41.
8. Curley, J.W., Ramsden, R.T., Howell, A., et al. Oestrogen and progesterone receptors in acoustic neuroma. *J. Laryngol. Otol.* 1990; 04:865-7
9. Van Leeuwen, J.P., Cremers, C.W., Thewissen, N.P. et al. Acoustic neuroma: correlation among tumor size, symptoms, and patient age. *Laryngoscope*. 1995;105:701-7.
10. Allen, J., Eldridge, R., Koerber, T. Acoustic Neuromas in the Last Months of Pregnancy. *Am. J. Obstet, Gynecol.*, 1974;119:516-520
11. Weber, P.C., Lobar, R.I., Gantz, B.J. Appropriateness of magnetic resonance imaging in sudden sensorineural hearing loss. *Otolaryngol. Head Neck Surg.*, 1997;116:153-156.
12. Hughes, G.B., Freedman, M.A., Itaberkamp, T.J et al, Sudden sensorineural hearing loss. *Otolaryngol. Clin. North Am.* 1996;29:303-40.
13. Wilson, D.F., Hodgson, R.S., Gustafson, M F., et al The sensitivity of auditory brainstem response testing in small acoustic neuromas. *Laryngoscope*, 1992;102:961-4.
14. Zappia, J.J, O'Connor, C.A., Wiet, R. et al. Rethinking the use of auditory brainstem response in acoustic neuroma screening. *Laryngoscope*. 1997;107:1388-92.
15. Kartush, J.M., Brackmann, D.E. Acoustic neuroma update. *Otolaryngol. Clin North Am.*, 1996;29(3):377-92.
16. Hechi CS., Honnibia, V.F., Wiet, R.J. et al Hearing preservation after acoustic neuroma resection with tumor size as a clinical prognosticator. *Laryngoscope*, 1997;107:1122-6.