



THE AGA KHAN UNIVERSITY

eCommons@AKU

Section of Neurosurgery

Department of Surgery

3-2006

Trans-mastoid approach to otogenic brain abscess

Ashfaq A. Razzaq

Rashid Jooma

Shahid Ahmed

Follow this and additional works at: https://ecommons.aku.edu/pakistan_fhs_mc_surg_neurosurg



Part of the [Neurology Commons](#), [Neurosurgery Commons](#), and the [Surgery Commons](#)

Trans-Mastoid approach to Otogenic Brain Abscess

Ashfaq A. Razzaq, Rashid Jooma, Shahid Ahmed

Department of Neurosurgery, Jinnah Postgraduate Medical Center, Karachi.

Abstract

The treatment of otogenic brain abscess initially involves excision or aspiration of the abscess through a temporal or sub-occipital route depending on its location. This is followed by a mastoidectomy by the ENT surgeon to eradicate the primary source of infection. During the last three years, we have approached such lesions through a mastoidectomy followed by excision of the abscess through the same approach. This trans-mastoid approach is technically feasible in following the tract of suppuration, and clearing the cause and effect of pathology, at the same sitting.

This paper describes our initial experience with the trans-mastoid approach to otogenic brain abscesses. On the basis of our results, we believe that transmastoid approach is an effective and logical option for the treatment of otogenic brain abscess, and merits further investigation in the form of a prospective study.

Introduction

The prevalence of middle ear infections and its intra-cranial complications is a major public health problem in developing countries.¹ The prevalence of otitis media in South Asia is 15-20% and 5-10% of these patients present with intra-cranial complications.¹ The most commonly encountered intra-cranial complication is meningitis followed by brain abscess. The mortality of otogenic brain abscess is in the range of 30-40%.² The eradication of infection in the brain and the ear is a major challenge which was realized as early as 1893 by Sir William Macewen, who described his approach to otogenic brain abscess, through the mastoid route. However, with the development of otology and neurosurgery as separate specialties, neurosurgeons increasingly relied on otologists for the mastoid part of the operation.³ Consequently, the standard treatment of otogenic brain abscess evolved into two separate procedures, involving the primary focus in the mastoid and its secondary complications in the brain, each with its own anaesthetic and surgical morbidity and mortality.^{1,4}

Recently, the advantages of eradicating the primary focus of infection through a trans-mastoid approach along with excision of the brain abscess have been reported in the Otolaryngology literature from the West. i.e. the avoidance of

two separate surgical procedures for the same pathology.⁵ However, most neurosurgeons still rely on a two-stage approach to otogenic brain abscess.^{3,6} This study proposes to describe a series of six cases in which a mastoidectomy was performed at the same sitting as the excision of the otogenic abscess.

Methods

The medical records of six patients of otogenic brain abscess who had undergone trans-mastoid approach in our unit between January 1998 to December 2000 were reviewed retrospectively. The presenting complaints and physical examination were carefully reviewed with particular attention to otologic examination. The patient data was transcribed to specially designed proformas. The data was entered into SPSS software and presented in the form of a table. Those patients in whom the abscess was located at some distance from the mastoid were judged to be unsuitable for this approach and excluded from the study.

Clinical Presentation

The age range of our patients was from 5 to 45 years. Four of the patients were between 20-40 years of age, while the only child was five years old. All five of our patients had symptoms suggestive of raised intracranial pressure. These included headache and vomiting. The duration of complaints ranged from 15 days to two months. In addition 3 of the 5 patients had a history of ipsilateral ear discharge, the duration ranging from a few months to a year. Four of the patients had a history of high-grade fever during the last month. All of the patients with a posterior fossa abscess exhibited ipsilateral dysmetria and gait ataxia. None of the patients had an impairment of conscious level. The patient with temporal lobe abscess demonstrated a contralateral upper quadrantanopsia. The clinical presentation is summarized in Table.

In all five of our patients, CT scan with contrast was the primary imaging modality. MR scan was obtained in the patient with temporal lobe abscess. The typical ring enhancement corresponding to late encapsulation was seen in all patients on contrast scan. In addition there was sclerosis and obliteration of the mastoid air cells in all of our patients. No associated intra-cranial complications were seen. An illustrative example of pre-operative imaging is presented in Figure 1.

Table. Clinical presentation of patients undergoing trans-mastoid approach.

Patient No.	Age	Sex	Symptoms	Signs	CT with contrast	MR	Post-op course and follow-up
1.	5	F	Fever & vomiting-8 days Discharge from L ear- 1 yr.	Left mastoid region swelling and tenderness Altered consciousness- 14/15	Ring enhancing left cerebellar lesion adjacent to temporal bone	None	Smooth recovery after transmastoid approach. No recurrence after 18 mo.
2.	31	M	Headache and vomiting-12days. Discharge R ear- 1 yr.	R ear CSOM	Ring enhancing lesion in right cerebellar hemisphere	None	Recovered well, except for transient post-op delirium. No recurrence at 10 months
3.	25	M	Headache vomiting and drowsiness 10 days. Discharge left ear 2 yrs	L ear CSOM	Ring enhancing lesion in left cerebellar hemisphere	None	Recovered smoothly. No recurrence at 13 months
4.	32	M	Discharge R ear 8 months. Vertigo and vomiting -4 days	R ear CSOM	Right cerebellar ring enhancing lesion	None	Smooth recovery. No recurrence at 4 months.
5.	32	F	Discharge L ear 45 days Headache and vomiting 4 days	L ear CSOM	L temporal ring enhancing lesion	L temporal ring enhancing lesion	Good recovery No recurrence at 15 months.
6.	18	M	Headache vomiting and Rear pain 20 days	R ear acute otitis media	R cerebellar ring enhancing lesion	None	Good post op recovery. No recurrence at 12 months.

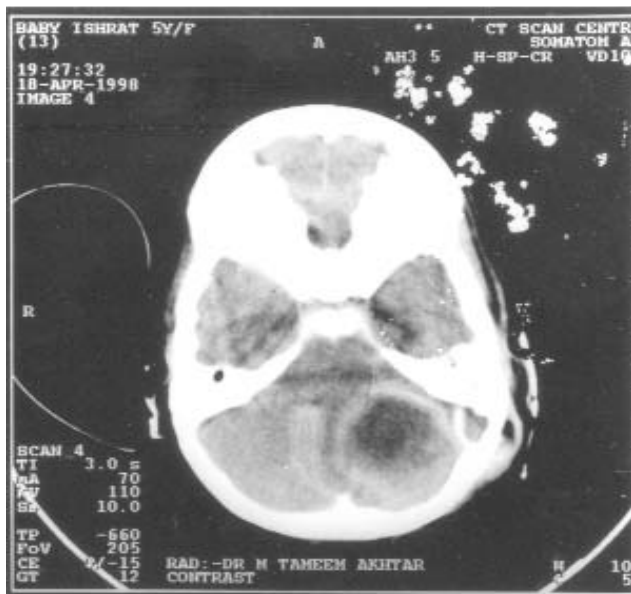


Figure 1. Pre-operative CT scan with contrast (patient 1) shows ring enhancing left cerebellar lesion adjacent to temporal bone with sclerosis of the mastoid air cells.

Surgical Intervention

The operative technique consisted of radical mastoidectomy to clear the primary focus of infection followed by resection of the brain abscess through the same approach. A curvilinear retro - auricular incision was used in all cases. Firstly, the "triangle of attack" was defined which is limited anteriorly by the spine of Henle and external auditory meatus, postero-inferiorly by the sigmoid sinus and superiorly by the temporal line and the tegmen plate of the middle fossa. The drilling was performed in this triangle and a standard radical mastoidectomy carried out. This entailed clearance of the mastoid air cells, the antrum and the middle ear cavity. Pus was encountered in the mastoid air cells in most cases. During this process the digastric ridge was developed and the facial nerve preserved. The drilling was then continued towards either the posterior fossa through Trautman's triangle, or through the tegmen plate into the middle fossa, depending on the location of the abscess. In most cases, a phlebitis dural scar was found at the point of intracranial penetration of infection, signifying infective thrombosis of

an emissary vein. The dura was opened at that point and the abscess encountered directly underneath. This is one of the main advantages of this approach, as damage to normal brain tissue is minimized. The abscess was decompressed by needle aspiration and the capsule excised in a standard fashion. The dura was packed tightly with fat graft, taken from the abdomen in order to prevent CSF leakage. The wound was closed in layers.

All patients showed a smooth post-operative recovery. There were no significant complications related to the procedure. One of the patients had transient post-op fever, which cleared within two days and was presumed to be due to atelectasis. The mean post-operative hospital stay was 7 days. A mixed growth of microorganisms was found on culture in most cases, with a predominance of streptococcus. Antibiotic therapy was continued as outpatient for a total of four weeks, based on the culture results.

Post-operative imaging demonstrated complete excision of abscess, with no residual focus of infection (Figure 2).

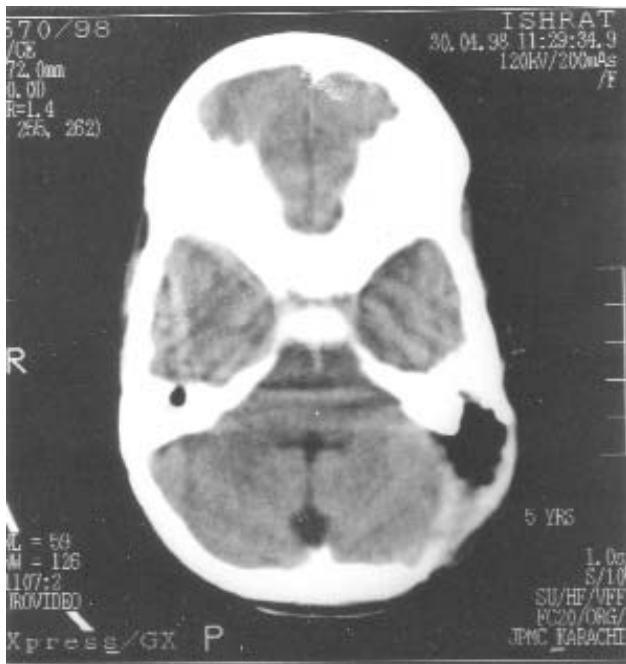

Figure 2. Post-operative CT scan of brain with contrast (patient 1) showing a left mastoidectomy with complete excision of the cerebellar abscess through the same approach.

The follow-up period ranged from 2-4 months. During this time the patients continued to show good recovery and no further intra-cranial or otologic complications were noted in any of the patients.

Discussion

Otogenic brain abscess is a relatively common problem in developing countries, where the prevalence of chron-

ic otitis media is reported to be in the range of 30-40% and 0.5%-1% of these develop brain abscess.¹ Similar study done in other parts of the country reveals Burr hole aspiration and excision of the capsule as the treatment modality.⁷ The standard approach for otogenic intracranial abscess is craniotomy and excision of abscess followed by a mastoidectomy performed as a second procedure.⁴ However recently the advantages of combining these two procedures into a single approach have been reported in the literature.⁵

The decision to perform either a radical or cortical mastoidectomy is based on the presence or absence of cholesteatoma in the middle ear.⁵ In cases of cholesteatomatous ears, a radical mastoidectomy is preferable in order to reduce the rate of post-operative recurrence. In this series, all of the patients had cholesteatoma necessitating radical mastoidectomy.

No other intracranial complications other than brain abscess were noted in this series. Other reports have described a high incidence (30-50%) of concurrent meningitis.³ Subdural empyema has also been described to occur in 10-20%, in conjunction with the intracranial abscess.⁸ Similarly, lateral sinus thrombosis has been described in up to 20% of patients, although this was not noted in our group.⁸

Post-operative morbidity, mortality, and recurrence were nil in our series. Others have described recurrence rates of 2-5% with this approach, which are much lower than the 20-25% recurrence described with a two stage procedure. The mortality with Trans-mastoid approach has been reported to be 2% in one series,³ and 8% in another.⁵

The duration and cost of hospital stay was markedly reduced. The mean hospital stay was 7 days. Some part of this period may be attributed to the rural origin of many of our patients and their inability to follow-up frequently, thereby necessitating a longer stay. Hence, the duration of hospital stay may be reduced even further in settings where these problem do not exist.

In conclusion, trans-mastoid approach to otogenic abscess offers several advantages over the conventional two-stage method of dealing with this problem. The primary focus of infection is eradicated along with the secondary complications in a single approach. This spares the patient the added morbidity caused by two separate incisions and anaesthetic procedures and also reduces the mortality, rate of recurrence and complications. In addition, the duration and cost of hospital stay are markedly reduced. The authors recommend further evaluation of this approach in a larger prospective study.

References

1. Nadkarni TD, Bhayani A, Goel A, Karapurkar AP. Bilateral otogenic cerebellar abscesses. *J Postgrad Med* 1993; 39:38-9.
 2. Kempf HG, Wiel J, Issing PR, Lenarz T. Otogenic brain abscess. *Laryngorhinootologie* 1998; 77:462-6.
 3. Kurien M, Job A, Mathew J, Chandy M. Otogenic intracranial abscess: concurrent craniotomy and mastoidectomy--changing trends in a developing country. *Arch Otolaryngol Head Neck Surg* 1998. 124:1353-6
 4. Milstein S. The history of mastoid surgery. *Am J Otol* 1980; 1:174-8.
 5. Singh B, Maharaj TJ. Radical mastoidectomy: its place in otitic intracranial complications. *J Laryngol Otol* 1993; 107:1113-8.
 6. Pino Rivero V, Keituaqwa Yanez T, Marcos Garcia M, Trinidad Ruiz G, Pardo Romero Gonzale Z, Palomino A, et al. Otogenic intracranial abscesses. Description of 6 cases. *An Otorrinolaringol Ibero Am.* 2004;31:23-31.
 7. Bhand AA. Brain Abscess Diagnosis and management. *J Coll Physicians Surg Pak.* 2004. 14: 407-10.
 8. Schwager K Carducci F. Endocranial complications of acute and chronic oti-
-