



THE AGA KHAN UNIVERSITY

eCommons@AKU

---

Department of Paediatrics and Child Health

Division of Woman and Child Health

---

January 2013

# Oesophageal duplication cyst presenting as haemoptysis

Noureen Afzal

*Aga Khan Secondary Hospital*

Syeda Ezz-e-Rukhshan Adil

*Dow University of Health Sciences*

Ammara Mushtaq

*Dow University of Health Sciences*

Arshalooz Rahman

*Aga Khan University*

Muneer Amanullah

*Aga Khan University, muneer.amanullah@aku.edu*

Follow this and additional works at: [https://ecommons.aku.edu/pakistan\\_fhs\\_mc\\_women\\_childhealth\\_paediatr](https://ecommons.aku.edu/pakistan_fhs_mc_women_childhealth_paediatr)



Part of the [Surgery Commons](#)

---

## Recommended Citation

Afzal, N., Adil, S., Mushtaq, A., Rahman, A., Amanullah, M. (2013). Oesophageal duplication cyst presenting as haemoptysis. *Journal of Pakistan Medical Association*, 63(5), 633-634.

**Available at:** [https://ecommons.aku.edu/pakistan\\_fhs\\_mc\\_women\\_childhealth\\_paediatr/239](https://ecommons.aku.edu/pakistan_fhs_mc_women_childhealth_paediatr/239)

## Oesophageal duplication cyst presenting as haemoptysis

Noureen Afzal,<sup>1</sup> Syeda Ezz-e-Rukhsan Adil,<sup>2</sup> Ammara Mushtaq,<sup>3</sup> Arshalooz Rahman,<sup>4</sup> Muneer Amanullah<sup>5</sup>

### Abstract

Duplications of the alimentary tract include a variety of cysts, diverticula, and tubular malformations, all believed to have embryological origin. The cysts are most commonly found in children, and the diagnosis is made in infancy in the majority of patients. We report a case of a two-and-a-half year old child, presenting with the history of repeated episodes of haematemesis. Upper GI endoscopy was unremarkable and the chest x-ray showed no pathology. Computed tomography (CT) angiogram revealed soft tissue density lesion in the right chest at the level of T6. Right thoracotomy suggested a cystic mass close to the oesophagus which was shown on histopathology to be lined with gastric mucosa consistent with oesophageal duplication cyst. To the best of our knowledge, this is the first case of its kind reported from Pakistan.

**Keywords:** Duplication cyst, Oesophagus, Case reports, Thoracotomy, Pakistan.

### Introduction

Duplications of the alimentary tract are rare malformations reported in 1 out of every 4500 autopsies.<sup>3</sup> They present as cysts or diverticula, found in variable locations and sizes, and present with variable symptoms. The exact origin of such congenital abnormalities still remains unknown, even though several explanations have been offered because of variability in site and size.<sup>1</sup> Although Fitz had used the term intestinal duplication in 1884, it was Ladd who popularised it in the 1930's and described the three characteristics of this anomaly: having an internal lining similar to a part of alimentary tract; presence of a smooth muscle layer; and close proximity to a part of the alimentary tract.<sup>2</sup> Duplications are classified as either cystic or tubular and are predominately located on the mesenteric border sharing a common blood supply with the adherent tract.<sup>3</sup>

Gastrointestinal duplication cysts frequently involve the small intestine, while gastric, duodenal, rectal and thoracoabdominal presentations are uncommon.<sup>4</sup> Thoracic and thoracoabdominal duplications constitute about 10-20%

<sup>1</sup>Department of Paediatrics, Aga Khan Secondary Hospital, Karimabad, <sup>2,3</sup>3rd Year Medical Student, Dow Medical College, Dow University of Health Sciences, <sup>4</sup>Department of Paediatrics, <sup>5</sup>Department of Surgery, Aga Khan University Hospital, Karachi.

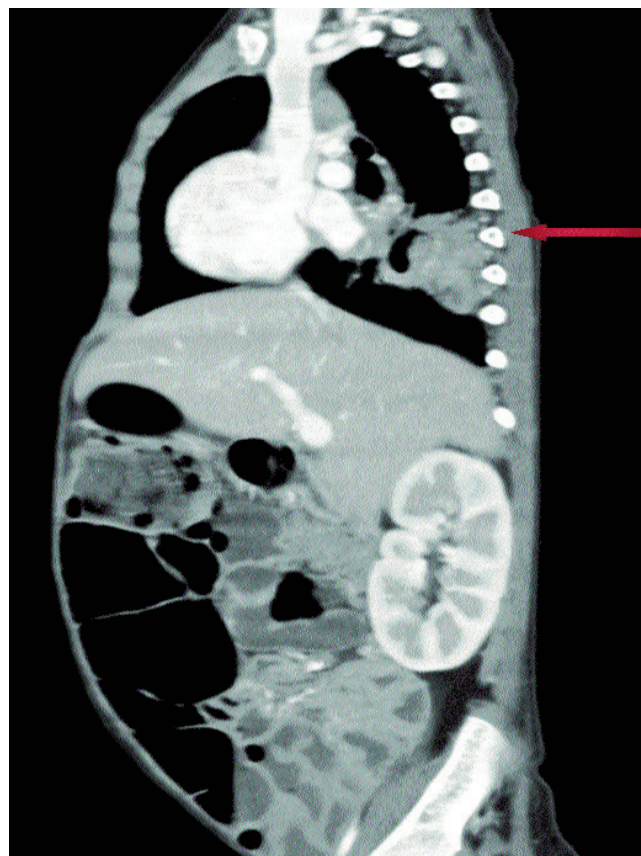**Correspondence:** Noureen Afzal. Email: n\_afzal1@yahoo.com

of all duplication cysts.<sup>5</sup> Foregut cysts can be classified into three variants: bronchogenic, intramural oesophageal and enteric. To date, no case of enteric variety of oesophageal duplication has been reported in Pakistan.

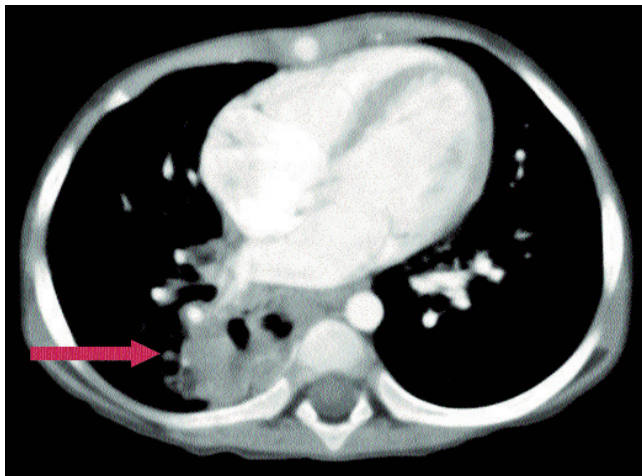
We report here a case of enteric duplication cyst presenting as oesophageal duplication in the posterior wall of right pleural cavity in a two-and-half year-old child.

### Case Summary

A two-and-a-half year-old child presented with complaints of repeated episodes of haematemesis since the age of 3 months. There was no associated history of fever or jaundice, nor any family history of chronic illnesses like tuberculosis or hepatitis. The parents consulted multiple doctors for the complaint, and he was extensively worked up for chronic liver disease and portal hypertension. Complete blood count was



**Figure-1:** CT angiogram suggesting paraspinous mass in the right chest.



**Figure-2:** Transverse CT showing duplication cyst.

normal with normal platelet count. All laboratory investigations were normal including liver function tests (LFTs) and coagulation profile: LFTs showed total bilirubin of 0.6 mg/dL with direct component of 0.1 mg/dL; SGPT was 11  $\mu$ /L; and alkaline phosphatase was 74 U/L. Ultrasound Doppler of the abdomen was performed but failed to show ascites or evidence of portal hypertension. Upper endoscopy ruled out oesophageal varices or any other cause of haematemesis. On examination, the child appeared weak and there was failure to thrive with height and weight less than the 5th percentile. He was moderately pale, and vital signs showed mild respiratory distress (48 breaths/min). There were no peripheral stigmata of chronic liver disease. CT angiogram failed to show the source of GI bleeding. However, there was a suggestion of paraspinal mass in the right chest with a well-defined nodule in the adjacent lung parenchyma (Figure 1 & 2). Right thoracotomy was performed after a failed biopsy. A cyst was found adherent to the parietal pleura which was not communicating with the oesophagus. There was also a large lymph node obstructing the right lower lobe bronchus. The cystic mass and the lymph node were completely dissected, separated and excised. Histopathology confirmed the diagnosis of the cystic mass to be compatible with oesophageal duplication cyst with gastric mucosa. The child was discharged after two days in a stable condition. Growth and weight improved rapidly during follow-up. No further episodes of haemoptysis or haematemesis have occurred at a follow-up of one year.

## Discussion

Oesophageal duplication is a rare presentation and has a reported incidence of 1 in every 8000 live births.<sup>5</sup> Gastroenteric duplication cysts are detected fairly earlier, mostly in the first year of life.<sup>6</sup> In our case, the cyst was detected in a two-and-a-

half year-old child. Cases of oesophageal duplication cysts in adults have also been reported in the literature.<sup>7,8</sup> A recently reported case of oesophageal duplication cyst was diagnosed at 6 months of age with the presentation of "inspiratory stridor and dyspnoea."<sup>9</sup> Another case in a 4 year-old girl, who presented with cough and low-grade fever, was reported in the right paratracheal region.<sup>10</sup> Most duplication cysts of the thorax present on the right side rather than on the left as in our case.

Asymptomatic presentations in oesophageal duplication cysts are not a rare event,<sup>6</sup> unlike the case reported here. The patient was found with mild respiratory distress with haemoptysis as the major presenting complaint. Haemoptysis most commonly occurs for cysts in the thorax adherent to the lung or pleura.

In most cases of oesophageal duplication, associated congenital abnormalities are commonly reported such as mental impairment, Meckel's diverticulum, hernias, oesophageal atresia, etc.<sup>8</sup> However, no such association was encountered in our patient.

As recommended in duplication cysts, surgical excision was performed in this child. The recovery was uneventful and no further episodes of haemoptysis or haematemesis have occurred in a year of follow-up as has been in case reported by Gupta et al.<sup>9</sup>

## Conclusion

Duplications of the alimentary canal are rare malformations which present as cysts or diverticula. Gastroenteric duplication cysts are detected in the early years of life, with surgical excision as the recommended treatment, as was performed successfully in our case.

## References

1. Bremer JL. Diverticula and duplications of the intestinal tract. *Arch Pathol* 1944; 38: 132-40.
2. Ladd WE, Gross RE. *Abdominal Surgery of Infancy and Childhood*. Philadelphia: William Saunders Co; 1947.
3. Puligandla PS, Nguyen LT, St-Vil D, Flagede H, Bensoussan AL, Nguyen VH, et al. Gastrointestinal duplications. *J Pediatr Surg* 2003; 38: 740-4.
4. Iyer CP, Mahour GH. Duplications of the alimentary tract in infants and children. *J Pediatr Surg* 1995; 30: 1267-70.
5. Isaacson PG. Duplication cysts. In: Noffsinger AE, Stemmermann GN, Lantz EP (eds). *Gastrointestinal Pathology. An Atlas and Text*. 3rd ed. Philadelphia: Lippincott 2008; pp 24-6.
6. Langston HT, Tuttle WM, Patton TB. Esophageal duplications. *AMA Arch Surg* 1950; 61: 949-56.
7. Nakahara K, Fujii Y, Miyoshi S, Yoneda A, Miyata M, Kawashima Y. Acute symptoms due to a huge duplication cyst ruptured into the esophagus. *Ann Thorac Surg* 1990; 50: 309-11.
8. Neo EL, Watson DI, Bessell JR: Acute ruptured esophageal duplication cyst. *Dis Esophagus* 2004; 17: 109-11.
9. Gupta B, Meher R, Raj A, Agarwal S. Duplication cyst of oesophagus: a case report. *J Paediatr Child Health* 2010; 46: 134-5.
10. Yim AP. Thoracoscopic resection of an esophageal cyst in a 4-year-old girl. *Chest* 1996; 110: 545-6.