



THE AGA KHAN UNIVERSITY

eCommons@AKU

---

Department of Surgery

Department of Surgery

---

September 2011

# Isolated cryptococcal osteomyelitis in an immunocompetent patient

Irfan Qadir

*Aga Khan University*, [irfan.qadir@aku.edu](mailto:irfan.qadir@aku.edu)

Farheen Ali

*Aga Khan University*

Umair Zafar Malik

*Aga Khan University*

masood umer

*Aga Khan University*, [masood.umer@aku.edu](mailto:masood.umer@aku.edu)

Follow this and additional works at: [http://ecommons.aku.edu/pakistan\\_fhs\\_mc\\_surg\\_surg](http://ecommons.aku.edu/pakistan_fhs_mc_surg_surg)



Part of the [Orthopedics Commons](#)

---

## Recommended Citation

Qadir, I., Ali, F., Malik, U. Z., umer, m. (2011). Isolated cryptococcal osteomyelitis in an immunocompetent patient. *J Infect Dev Ctries*, 14(5), 669-673.

**Available at:** [http://ecommons.aku.edu/pakistan\\_fhs\\_mc\\_surg\\_surg/230](http://ecommons.aku.edu/pakistan_fhs_mc_surg_surg/230)

## Case Report

# Isolated cryptococcal osteomyelitis in an immunocompetent patient

Irfan Qadir<sup>1</sup>, Farheen Ali<sup>1</sup>, Umair Z. Malik<sup>1</sup>, Masood Umer<sup>2</sup>

Department of Medicine<sup>1</sup> and Department of Surgery<sup>2</sup>, Aga Khan University Hospital, Karachi, Pakistan

### Abstract

Cryptococcosis is a rare infection in HIV-negative individuals. While the lungs and the central nervous system are most commonly infected, skeletal cryptococcosis is uncommon and isolated osteomyelitis due to *Cryptococcus neoformans* is quite rare. To our knowledge, only 47 cases of isolated cryptococcal osteomyelitis have been reported from 1974 to 2005. We report a case of isolated cryptococcal osteomyelitis in an immunocompetent patient, who received 12 weeks of fluconazole with complete recovery.

**Key words:** *Cryptococcus neoformans*; osteomyelitis

*J Infect Dev Ctries* 2011; 5(9):669-673.

(Received 01 July 2010 – Accepted 11 March 2011)

Copyright © 2011 Qadir *et al.* This is an open-access article distributed under the Creative Commons Attribution License, which permits unrestricted use, distribution, and reproduction in any medium, provided the original work is properly cited.

### Introduction

Cryptococcosis is a disseminated infection of man and animals caused by an encapsulated, yeast-like fungus, *Cryptococcus neoformans*. The common reservoir of this pathogen is soil contaminated with pigeon excreta. Although the disease can involve almost any structure or organ in the body, the lungs and central nervous system are most commonly involved [1]. Bone involvement in patients with disseminated disease is uncommon, with an incidence of 5% to 10%, and is presumed to be caused by seeding of the bone via a hematogenous route from a pulmonary focus or a lymph node and, less commonly, via direct inoculation of the organism through the skin. An isolated bone lesion in a patient without systemic disease is even more rare [2]. This report presents a case of a twenty-eight-year-old immunocompetent female with cryptococcal osteomyelitis of the left distal radius.

### Case report

A twenty-eight-year-old female presented to the out-patient orthopedic department of Aga Khan University Hospital (AHUH) with complaints of pain and swelling in the left distal arm with limited mobility of the wrist joint for four weeks. There was no history of trauma to the site. She had an occasional history of feeling warm but there was no documentation of recorded temperature. Her past history and family history were non-contributory.

On examination, the patient was afebrile with stable vitals. Her systemic examination was unremarkable. Local examination of the left forearm revealed a 4 x 3.5 cm soft tender swelling. There was no regional lymphadenopathy. The laboratory workup showed a total leukocyte count of  $10.3 \times 10^9/L$  with 77% neutrophils and 16.4% lymphocytes and a slightly raised erythrocyte sedimentation rate [ESR] of 26 mm/1hr. A roentgenographic examination of the left distal forearm revealed a lytic lesion, 25 x 16 mm, at the metaphyseal location with medial and posterior soft tissue swelling. No calcification was seen (Figure 1). A bone scan revealed increased uptake of tracer in the distal radius. No other skeletal lesions were identified.

The radial lesion was aspirated in the clinic and frank pus was obtained. Unfortunately, the pus was neither sent to pathology for analysis nor to microbiology for culture. A working diagnosis of Brodie's abscess was made and an extended curettage and sequestrectomy with a high speed burr was performed the next day. Operative findings showed a small amount of pus and necrotic bone. A specimen was taken for culture and histopathology. Histopathological examination revealed fibrocollagenous tissue mixed with a few bony fragments and areas of necrosis. The bone fragments showed moderate acute and chronic inflammatory cell infiltrates along with multinucleated giant cells. Numerous budding fungal microorganisms were

**Table 1.** Review of *Cryptococcus neoformans* osteomyelitis

Factors	Groups	Frequency
Gender	Male	27
	Female	19
No. of Sites	Single	39
	Multiple	8
Sites of Infection	Vertebra	8
	Rib	5
	Femur	5
	Tibia	3
	Skull	3
	Humerus	2
	Scapula	3
	Knee	3
	Ilium	1
	Clavicle	2
	Hip	2
	Others	2
	Treatment	Antifungals only
Surgery + Antifungals		17
Surgery only		1
Antifungals used	Amphotericin only	16
	Amphotericin + Flucytosine	15
	Flucytosine	2
	Fluconazole	5
	Fluconazole + Flucytosine	1
	Amphotericin + Fluconazole	2
	Stilbamitide	1
	Not Reported	5

Adapted from "Cryptococcus neoformans abscess and osteomyelitis in an immunocompetent patient" by J. A. Al-Tawfiq and J. Ghandour [3]

highlighted on special staining (Periodic Acid Schiff, Grocott's, Mucicarmine). There was no evidence of malignancy (Figure 2).

All the microbiological analyses were done at the clinical laboratory at the Aga Khan University Hospital (AKUH). Samples of curettaged material were processed per laboratory protocol and inoculated on sheep blood agar, chocolate agar, and MacConkey agar at 35°C. After 48 hours of incubation, cream-colored mucoid colonies were observed. Microscopy showed single budding yeast and an India ink preparation revealed the presence of a large halo of unstained space surrounding each cell, representing capsules. The final identification of the

*Cryptococcus* isolate as *C. neoformans* was obtained by a positive rapid urea hydrolysis test and the API 20C Yeast Identification System™ (bioMérieux, Marcy-l'Etoile, France). The microbiology laboratory at AKUH currently does not perform antifungal drug susceptibility testing; therefore, this isolate was not tested.

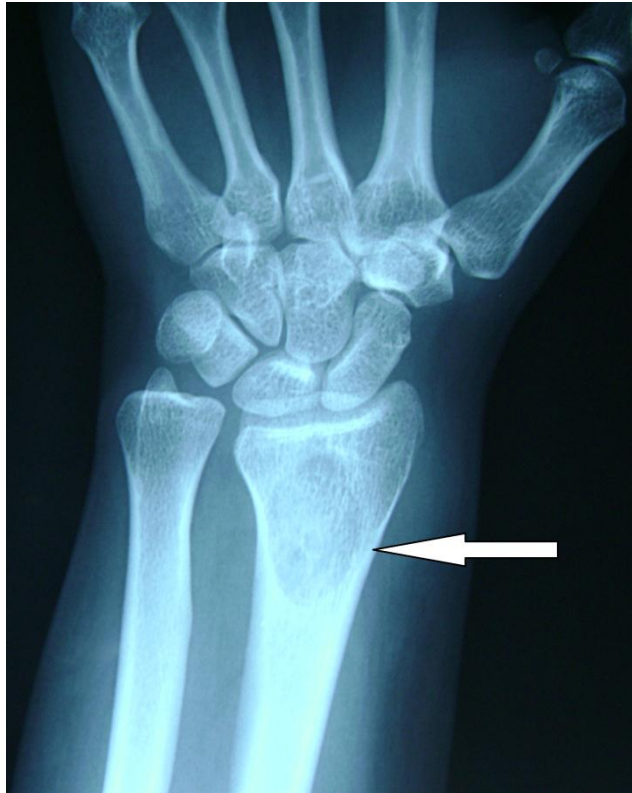Pending the culture results, the patient was continued on clindamycin and ciprofloxacin empirically. Once her preliminary histopathology results were available, she was referred to the Infectious Diseases clinic where the antibiotics were discontinued and antifungal therapy was instituted. Due to the patient's lack of sufficient finances, she was not hospitalized for intravenous amphotericin B and its accompanying toxicity monitoring. In addition, flucytosine could not be administered since it is not available in Pakistan. Due to these therapeutic restrictions, a decision was made to treat the patient solely with oral fluconazole, 400 mg per day. On follow-up visits, her pain and swelling gradually resolved and there was satisfactory function of her wrist joint. Therefore, therapy was discontinued after 12 weeks.

## Discussion

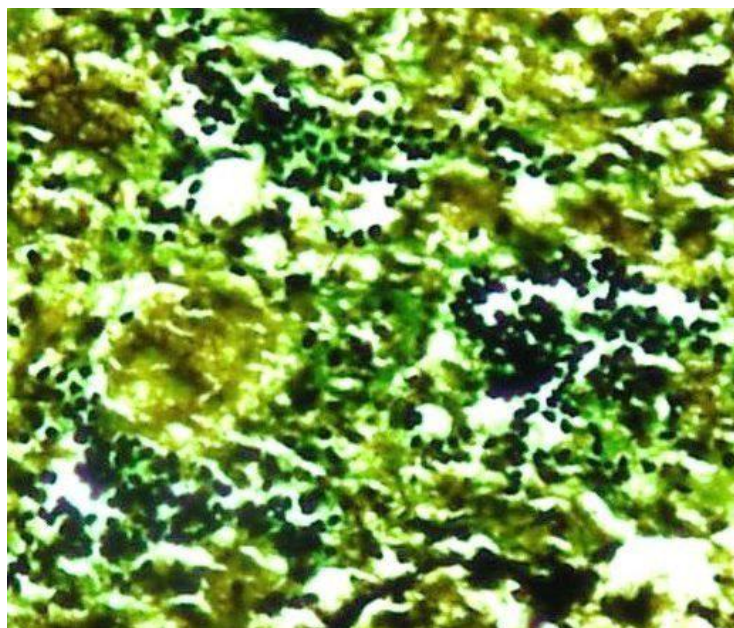
Infection with *C. neoformans* usually occurs in immunocompromised patients but may occur in immunocompetent hosts as well. To our knowledge, only 47 cases of isolated cryptococcal osteomyelitis have been reported in HIV-negative patients from 1974 to 2005. The age range was 1.3-84 years with a mean of 38.2. These patients often had a chronic debilitating disease, with sarcoidosis being the most common underlying pathology followed by tuberculosis, steroid therapy, and other diseases such as lymphoma, leukemia, Hodgkin's disease, and diabetes (Table 1) (3). Our case was exceptional in that there was no other accompanying illness indicative of immune dysfunction.

Cryptococcal osteomyelitis patients usually present initially with swelling and pain of the soft tissue surrounding the bone that may or may not be tender. There is usually no erythema but mild elevation in local temperature may be present. Sinus formation is rare [4]. The laboratory workup of most patients is significant for a raised ESR and white cell count. Radiologic examination reveals a lytic lesion with mild or absent periosteal reaction. The variable periosteal reaction can be misleading and lesions have been mistaken for osteosarcoma or other types

**Figure 1.** X ray left distal forearm



**Figure 2.** Grocott's methenamine silver stain of biopsy



of sarcoma [5]. In a case reported by Witte *et al.*, the patient was first thought to have a malignant neoplasm due to the presence of a lytic lesion with an extensive periosteal reaction. The diagnosis of cryptococcal osteomyelitis was later made on fine needle biopsy [6]. Cryptococcal infection must be differentiated from other infections such as systemic mycoses (histoplasmosis, blastomycosis, sporotrichosis, actinomycosis, and coccidioidomycosis), mycobacterial infections, and brucellosis, as these infections can also present with similar roentgenographic features. Our patient had no visible periosteal reaction on X-ray. Radioisotope scanning of the bone usually shows increased tracer uptake.

Definitive diagnosis of infection due to *C. neoformans* can only be established by culture of the fungus from infected material and identification of the microorganism in material obtained by biopsy [7]. Canavanine glycine bromothymol blue (CGB) agar is the media of choice to identify *Cryptococcus* isolates. *Cryptococcus gattii* can grow in the presence of L-canavanine and assimilate glycine as a sole carbon source turning CGB agar blue while *C. neoformans* does not grow on this medium. For the differentiation of *C. neoformans var. neoformans* and *C. neoformans var. grubii*, creatinine dextrose bromothymol blue thymine (CDBT) agar is the medium of choice. *C. neoformans var. neoformans* grows as bright red colonies, whereas no colour change is observed for *C. neoformans var. grubii* [8].

There are a number of stains that can be used to identify *Cryptococcus* in clinical samples, including Wright's stain, Gomori's methenamine silver (GMS) stain, Calcofluor white, H&E, Alcian blue, mucicarmine, and India ink. Microscopically, it appears as a spherical, narrow-based budding yeast cell in tissue. The capsule of *C. neoformans* is represented by empty spaces around the organism [9]. The diagnosis in this patient was based on biochemical, histological, and microbial analysis of the curettaged material.

There is no standardized treatment protocol for cryptococcal infection of specific body sites, with the exception of lung and CNS infection. The Infectious Diseases Society of America (IDSA) 2010 guidelines recommend that non-meningeal, non-pulmonary cryptococcosis with infection limited to a single site can be treated with fluconazole (400 mg [6 mg/kg] per day orally) for 6 to 12 months (B-III level recommendation) [10]. The selection of the anti-fungal agent and duration of therapy depends on

factors that include the severity of disease, host immune status, and therapeutic response. Murphy *et al.* reported complete resolution of single site cryptococcal osteomyelitis after 10 weeks of fluconazole at a dose of 200 mg/day [11]

The outcome of HIV-negative patients treated for cryptococcal osteomyelitis is favorable. Of the 42 patients with reported outcomes, four died, one from liver failure, one from pneumonia, while the cause of death was not reported in two cases [3]. Our patient was observed for over two years at a no-charge clinic. Her follow-up X-rays had shown improvement in the size of the lesion, but as a sequestrectomy had been done, a permanent defect was expected to remain in the radiological films. Unfortunately, due to the family's financial constraints, they were unable to purchase the medication needed to continue treatment. However, due to significant improvement in the patient's clinical condition, antifungal therapy was discontinued after 12 weeks. She was disease-free on her last follow-up visit.

## Conclusion

Isolated cryptococcal osteomyelitis in HIV-negative patients is a rare condition but should be considered in the relevant differential. The disease usually responds to antifungal therapy alone.

## References

1. Liu PY (1998) Cryptococcal osteomyelitis: case report and review. *Diagn Microbiol Infect Dis* 30: 33-35.
2. Behrman RE, Masci JR, Nicholas P (1990) Cryptococcal skeletal infections: case report and review. *Rev Infect Dis* 12: 181-190.
3. Al-Tawfiq JA and Ghandour J (2007) Cryptococcus neoformans abscess and osteomyelitis in an immunocompetent patient with tuberculous lymphadenitis. *Infection* 35: 377-382.
4. Raftopoulos I, Meller JL, Harris V, Reyes HM (1998) Cryptococcal rib osteomyelitis in a pediatric patient. *J Pediatr Surg* 33: 771-773.
5. Zach TL and Penn RG (1986) Localized cryptococcal osteomyelitis in an immunocompetent host. *Pediatr Infect Dis* 5: 601-603.
6. Witte DA, Chen I, Brady J, Ramzy I, Truong LD, Ostrowski ML (2000) Cryptococcal osteomyelitis. Report of a case with aspiration biopsy of a humeral lesion with radiologic features of malignancy. *Acta Cytol* 44: 815-818.
7. Subramanian S and Mathai D (2005) Clinical manifestations and management of cryptococcal infection. *J Postgrad Med* 51 Suppl 1: S21-26.
8. Ellis D, Davis S, Alexiou H, Handke R, Bartley R (2007) Descriptions of medical fungi, 2<sup>nd</sup> edition. Adelaide: Nexus Print Solutions 204 p.
9. Perfect JR (2009) *Cryptococcus neoformans*. In Mandell GL, Bennett, Dolin R, editors. Mandell, Douglas, and

Bennett's Principles and Practice of Infectious Diseases. Philadelphia: Churchill Livingstone Elsevier, 3287-3303.

10. Perfect JR, Dismukes WE, Dromer F, Goldman DL, Graybill JR, Hamill RJ, Harrison TS, Larsen RA, Lortholary O, Nguyen MH, Pappas PG, Powderly WG, Singh N, Sobel JD, Sorrell TC (2010) Clinical practice guidelines for the management of cryptococcal disease: 2010 update by the Infectious Diseases Society of America. *Clin Infect Dis* 50: 291-322.
11. Murphy SN and Parnell N (2005) Fluconazole treatment of cryptococcal rib osteomyelitis in an HIV-negative man. A case report and review of the literature. *J Infect* 51: e309-311.

### **Corresponding author**

Farheen Ali  
Department of Medicine  
Faculty Offices Building 2nd floor  
Aga Khan University  
Karachi 74800, Pakistan  
Telephone: 0092 314 208 4864  
Email: farheen.ali@aku.edu

**Conflict of interests:** No conflict of interests is declared.