



THE AGA KHAN UNIVERSITY

eCommons@AKU

Department of Surgery

Department of Surgery

July 2013

Cochlear implant in a patient with Mondini's deformity of the cochlea: pilot patient in Pakistan

Sadaf Qadeer Ahmed

Sir Syed University of Medical College, Pakistan

Montasir Junaid

Jinnah Medical College Hospital

Zainul Abedeen Sobani

Jinnah Medical College Hospital

N Naila

Aga Khan University, naila.nadeem@aku.edu

Mohammad Sohail Awan

Aga Khan University, sohail.awan@aku.edu

Follow this and additional works at: http://ecommons.aku.edu/pakistan_fhs_mc_surg_surg



Part of the [Otolaryngology Commons](#)

Recommended Citation

Ahmed, S., Junaid, M., Sobani, Z., Naila, N., Awan, M. (2013). Cochlear implant in a patient with Mondini's deformity of the cochlea: pilot patient in Pakistan. *JPMA: Journal of the Pakistan Medical Association*, 63(7), 913-915.

Available at: http://ecommons.aku.edu/pakistan_fhs_mc_surg_surg/211

Cochlear implant in a patient with Mondini's deformity of the cochlea: pilot patient in Pakistan

Sadaf Qadeer,¹ Montasir Junaid,² Zainul Abedeen Sobani,³ Naila Nadeem,⁴ Mohammad Sohail Awan⁵

Abstract

Autosomal-recessive genes account for about 80% of the patients of non-syndromic deafness, and a major portion of those lead to cochlear pathology. Given the strong cultural practice of consanguineous marriages and the lack of awareness regarding screening modalities, a high prevalence of hereditary pre-lingual deafness is seen in Pakistan. Considering the situation, cochlear implant surgery was introduced by Aga Khan University Hospital (AKUH), Karachi, Pakistan, in 2003. Recently we decided to expand the profile and services available and conducted the first ever cochlear implant on an anatomically-challenged cochlea. The case report relates to the experience of our pilot patient who was suffering from Mondini's deformity.

Keywords: Cochlear implants, Mondini's deformity.

Introduction

Pre-lingual deafness, defined as severe sustained hearing loss prior to the acquisition of language skills, is a significant public health issue. Studies estimate that 1-6 in every 1,000 children suffers from pre-lingual deafness.¹ Nearly 50% of patients with congenital hearing loss are attributable to genetic causes, which can further be distributed among syndromic (30%) and non-syndromic hearing loss (70%).¹ Autosomal-recessive genes account for about 80% of the patients of non-syndromic deafness,² and a major portion of those lead to cochlear pathology.

Given the strong cultural practice of consanguineous marriages and the lack of awareness regarding screening modalities, a high prevalence of hereditary pre-lingual deafness is seen in Pakistan.³ A population-based survey of 607 children conducted in 1998 showed a prevalence of 7.9% hearing impairment, and 1.6 per 1000 profound bilateral hearing loss in Pakistan. Of the cases of severe

hearing loss, 70% were attributable to consanguineous marriages.⁴

Considering the situation, in 2003, Aga Khan University Hospital (AKUH) pioneered cochlear implant surgery in Karachi, Pakistan. Given the lack of resources and awareness, the programme did not gain as much momentum in the initial period. Keeping our limited initial experience, we were able to cater to a limited set of patients with textbook physiological cochlear pathologies. However, with the passage of time, we developed a major centre for cochlear transplantation in the region, performing around 25 implants each year.

The services available at the centre recently got a boost when the first ever cochlear implant on an anatomically-challenged cochlea was conducted. In this report, we share the experience of our pilot patient who was suffering from Mondini's deformity.

Case Report

A 3-year-and-10-month-old girl was referred for evaluation for a possible cochlear implant by her primary care physician. She was initially evaluated for congenital hearing loss at the age of 10 months due to a delay in speech development and a positive family history of congenital hearing loss in both her elder siblings. A brain-stem-evoked-response audiometry at the age of 10 months showed profound hearing loss in both ears with no response to click audiometry at maximal stimulation (100dB). Subsequent electrocochleography revealed intact cochlear nerves with the presence of microphonics and action potentials. She was being managed with hearing aids till the presentation.

She was the product of a consanguineous marriage; there was no history of maternal infections or drug use during the pregnancy. The patient's mother was under regular prenatal care by a qualified gynaecologist and had received adequate vitamin A supplements. The patient was born during an uneventful spontaneous vaginal delivery and had remained stable after birth. She received immunisations according to local recommendations. All her developmental milestones were up to the mark except hearing/speech. Her elder brother aged 13 years

^{1,5}Department of Otorhinolaryngology, Head & Neck Surgery, ³School of Medicine, ⁴Department of Radiology, Aga Khan University, ²Department of Otorhinolaryngology, Head & Neck Surgery, Jinnah Medical and Dental College Hospital, Karachi.

Correspondence: Montasir Junaid. Email: doc_montsj@yahoo.com

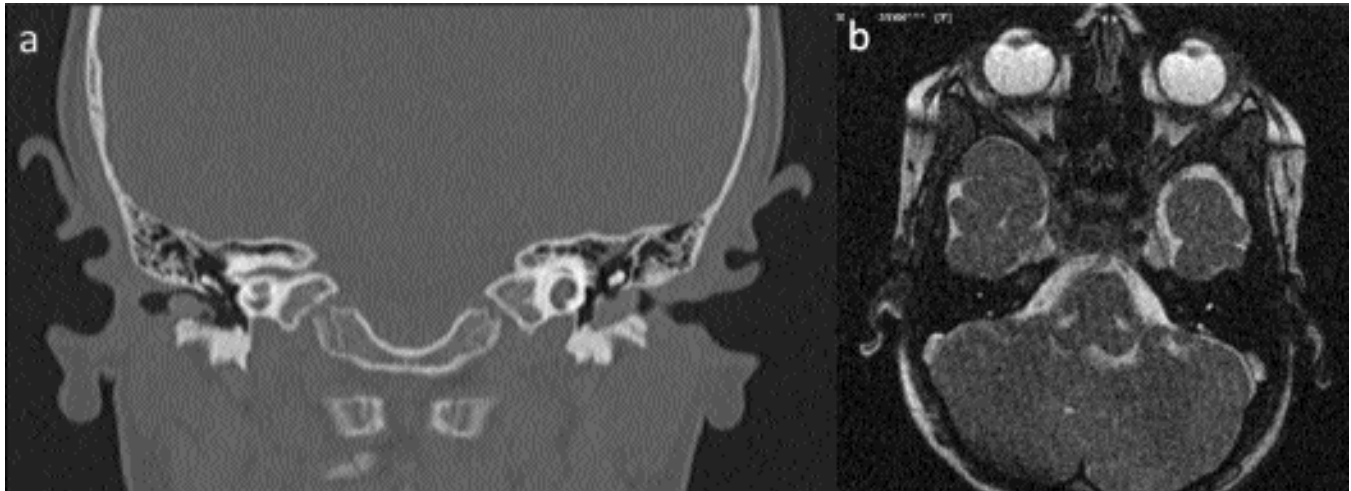


Figure: (a) CT scan revealed cystic cochleae with dilated vestibules bilaterally. Further, the modiolus could not be visualised, suggesting incomplete partitioning resulting in confluency between the middle and apical segments. (b) MRI showing intact cranial nerve VIII.

and sister aged 12 years suffered from profound hearing loss and were being managed with hearing aids.

On examination, she appeared in good overall health. She was responsive to visual and tactile stimuli; however the same was not true for auditory stimuli. She had achieved appropriate developmental milestones in areas other than speech. Otological examination revealed no apparent deformities of the external or middle ear structures. She was planned for a cochlear implant.

Computed tomography (CT) scan revealed cystic cochleae with dilated vestibules bilaterally. Further, the modiolus could not be visualised, suggesting incomplete partitioning resulting in confluency between the middle and apical segments (Figure-1 a) Magnetic resonance imaging (MRI) showed intact cochlear nerve (Figure-1 b).

We had previously not performed procedures on patients with anatomical deformities of the cochlea. However, we began coordination with experts from abroad. Following initial collaboration, the expert visited our centre and helped us carry out the pilot procedure.

A standard post-auricular incision was given and cortical mastoidectomy was completed using high-powered drill under microscope. A bed for the receiver unit of implant was created in the flatter part of the skull behind and above the pinna. A facial recess approach was used to create a posterior tympanotomy and visualise the cochlea. A standard cochleostomy was done just anterior and inferior to round window membrane to enter the scala tympani of the cochlea. A 12-channel short electrode was inserted in the cochlea successfully. Postoperatively, the patient remained well and was

discharged subsequently. She is currently enrolled in a speech rehabilitation programme and is considerably improving. At 6-months follow-up, she was able to follow verbal commands and is developing speech.

Discussion

Mondini's deformity, first described by Carlos Mondini in 1791, is an anatomical deformity of the cochlea consisting of a triad of a cochlea with one-and-a-half turns, an enlarged vestibule with normal semicircular canals and an enlarged vestibular aqueduct. Mondini's deformity accounts for 50% of cochlear malformations, resulting in variable degrees of otological dysfunction. Patients may experience profound hearing loss, and may not be responsive to hearing aids and other auditory devices.⁵ These patients may be considered for cochlear implantation. However, the short length and anatomical variation of the cochlea make the process of implantation a challenging task.

One of the first references to cochlear implantation in Mondini's deformity came in 1986.⁶ At that point, due to the unavailability of various diagnostic modalities, the procedure was mainly experimental and outcomes could not be predicted. While successful in the attempt, the surgeons themselves highlighted certain considerations in selecting candidates at that time; the most important being evaluation of the integrity of the neuronal apparatus. A histopathological study assessing the neuronal apparatus found a decreased number of neurons in the cochlea of patients with Mondini's deformity (7677; normal = 35,000 neurons).⁷ However, cochlear implants, imaging and pre-operative evaluation modalities have come a long way, and with the advent of

electrocochleography integrity of the neural apparatus can be reliably verified prior to the procedure. In our case, we verified the integrity of the cochlear nerves with electrocochleography.

Given the advances, results of cochlear implants in patients with anatomical deformities are similar to patients without deformities. A retrospective study from India reviewed 212 patients with cochlear implants, 46 of whom had radiologically identified anatomic variations. The study found no difference in outcomes between those with and without cochlear deformities. It, however, reported a high incidence of cerebrospinal fluid (CSF) gushers (22 of 46 patients). It also noticed cases with aberrant facial nerve paths associated with the malformation.⁸ Other studies also commented on the increased frequency of CSF gushers while implanting the electrodes in patients with Mondini's deformity.⁹

Another issue faced in Mondini's deformity is the short cochlear length compared to the length of the implanted electrodes. Literature refers to incomplete insertion of the electrode with electrodes remaining outside the cochleostomy. However, this phenomenon was seen in 2 out of 15 patients in a study.⁹ In our case, we were able to access compressed implants wherein the electrodes are placed closer to each other and the total distance between the first and last electrode is reduced. The compressed electrode is beneficial in ensuring complete insertion of the electrode in patients with shorter cochleae.

While comparing pragmatic outcomes in these patients, a study found progressive improvement of their speech perception abilities over time.⁸ It also found no differences in performance measured by the Common Phrases test between the 2 groups. It also found that patients with anatomical malformations performed

poorly compared to those with normal anatomy on the Phonetically Balanced Kindergarten test for phonemes. However, this difference seemed to get resolved by 2 years after implantation.⁸ Another study evaluating the outcomes at 2 years using speech perception tests on open-set speech also found no differences in those with and without inner ear malformations.¹⁰

Conclusion

The case presented related to cochlear implants in patients with anatomical deformities of the cochlea. This was a pilot case and long-term outcome is yet to be assessed.

References

1. Antonio SAM, Strasnick B. Syndromic sensorineural hearing loss. Medscape Reference. (Online) Updated on April 12, 2012. (Cited 2012 November 3). Available from URL: <http://emedicine.medscape.com/article/856116-overview>.
2. Petersen MB, Willems PJ. Non-syndromic, autosomal-recessive deafness. *Clin Genet* 2006; 69: 371-92.
3. Ali G. Genetic deafness in Pakistani population. *J Pak Med Assoc* 2010; 60: 418-9.
4. Elahi MM, Elahi F, Elahi A, Elahi SB. Paediatric hearing loss in rural Pakistan. *J Otolaryngol* 1998; 27: 348-53.
5. Niparko JK (ed). *Cochlear implants: principles & practices*. 2nd ed. New York: Lippincott Williams & Wilkins; 2009.
6. Miyamoto RT, Robbins AJ, Myres WA, Pope ML. Cochlear implantation in the Mondini inner ear malformation. *Am J Otol* 1986; 7: 258-61.
7. Schmidt JM. Cochlear neuronal populations in developmental defects of the inner ear. Implications for cochlear implantation. *Acta Otolaryngol* 1985; 99: 14-20.
8. Kim LS, Jeong SW, Huh MJ, Park YD. Cochlear implantation in children with inner ear malformations. *Ann Otol Rhinol Laryngol* 2006; 115: 205-14.
9. Li YX, Han DM, Zhao XT, Chen XQ, Kong Y, Zheng J, et al. Multi-channel cochlear implants in patients with Mondini malformation. *Zhonghua Er Bi Yan Hou Ke Za Zhi* 2004; 39: 89-92.
10. Van Wermeskerken GK, Dunnebie EA, Van Olphen AF, Van Zanten BA, Albers FW. Audiological performance after cochlear implantation: a 2-year follow-up in children with inner ear malformations. *Acta Otolaryngol* 2007; 127: 252-7.