



THE AGA KHAN UNIVERSITY

eCommons@AKU

Section of Gastroenterology

Department of Medicine

October 1993

Microscopic colitis: a diagnosis to consider

S Hamid

Aga Khan University, saeed.hamid@aku.edu

W Jafri

Aga Khan University, wasim.jafri@aku.edu

Z Abbas

Aga Khan University, zaigham.abbas@aku.edu

H Shah

Aga Khan University, hasnain.alishah@aku.edu

S Abid

Aga Khan University, shahab.abid@aku.edu

See next page for additional authors

Follow this and additional works at: https://ecommons.aku.edu/pakistan_fhs_mc_med_gastroenterol



Part of the [Gastroenterology Commons](#)

Recommended Citation

Hamid, S., Jafri, W., Abbas, Z., Shah, H., Abid, S., Sheikh, H., Hussainy, A., Khan, H. (1993). Microscopic colitis: a diagnosis to consider. *Journal of Pakistan Medical Association*, 43(10), 203-205.

Available at: https://ecommons.aku.edu/pakistan_fhs_mc_med_gastroenterol/208

Authors

S Hamid, W Jafri, Z Abbas, H Shah, S Abid, H Sheikh, A Hussainy, and H Khan

Microscopic Colitis: A Diagnosis to Consider

Pages with reference to book, From 203 To 205

Saeed Hamid, Wasim Jafri, Hasnain Shah (Department of Medicine, The Aga Khan University Hospital, Karachi.)
Zaigham Abbas, Shahab Abid, Haleem Khan (Department of Medicine, The Aga Khan University Hospital, Karachi.)
Hizbullah Sheikh, Akbar Hussainy (Departments of Pathology, The Aga Khan University Hospital, Karachi.)

Abstract

Microscopic colitis is a syndrome of chronic watery diarrhoea for which no cause can be identified other than the presence of diffuse, chronic inflammation in the lamina propria on colonic biopsy. Endoscopically and radiologically the colon appears normal. We studied case records of 215 patients presenting to our institution over a three year period with chronic diarrhoea. Nineteen patients were included in the study where two pathologists agreed on the presence of chronic inflammation on colonic biopsies. All patients had watery diarrhoea with urgency. Stool examination, laboratory indices, radiology of the large and small bowel and colonoscopy were normal in all patients. Patients did not respond to a variety of drugs. A significant improvement was noted in one patient given salazopyrin. In developing countries chronic diarrhoea is most often attributed to Infection and treated with antibiotics. Microscopic colitis should be considered in the diagnosis of such patients (JPMA 43: 203,1993).

Introduction

The term “microscopic colitis” is generally applied to a clinical syndrome of chronic watery diarrhoea for which no cause can be identified other than colonic inflammation¹. The colon appears normal endoscopically and radiologically but histology demonstrates the presence of diffuse, chronic, mild inflammation in the lamina propria which is usually pancolonic. Patients are middle aged or elderly, predominantly females and all have watery diarrhoea as the main symptom. Laboratory tests are usually normal. There have been relatively few published studies since “microscopic colitis” was first considered to be a distinct disease entity in 1980². However, there has been a recent resurgence of interest in this condition and two further studies have been reported^{3,4}. We present our experience of this clinical syndrome from a developing country.

Patients and Methods

We studied case records of 215 patients with chronic diarrhoea who presented to our hospital, a tertiary care referral centre, during a three year period (1987-1990). Our hospital uses the International Classification of Disease, 9th Revision, Clinical Modification (ICD-9-CM) coding system. According to this system the coding for patients with chronic diarrhoea/chronic colitis is 558.9. Twenty-five patients were identified where the only abnormality found on investigations was chronic inflammation on colonic biopsies. Biopsy specimens were re-read by two experienced pathologists independently in a blinded fashion. In 19 out of 25 cases, there was agreement on the presence of inflammation and these patients were included in the study. There were 10 males and 9 females, with an age range of 24-51 years (mean 42 years). All socio-economic classes were represented and all patients firmly denied the use of purgatives.

Symptomatology

The main symptoms are shown in Table.

Table. Clinical features of microscopic colitis.

Symptoms	Nos = 19
Diarrhoea	All
Urgency	All
Nocturnal diarrhoea	12 (63%)
Frequency of motions	3 to 10/day (Mean 6/day)
Consistency	
Watery	13 (68%)
Loose	6 (32%)
Mucus	7 (37%)
Blood	None
Abdominal pain	7 (37%)
Discomfort/distension	5 (26%)
Weight loss	2 (10%)

All 19 patients had diarrhoea with urgency as the predominant symptom while relatively few complained of abdominal pain or discomfort. The duration of diarrhoea was from six months to 15 years, with the majority of patients having had their symptoms from three to ten years (Figure 1).

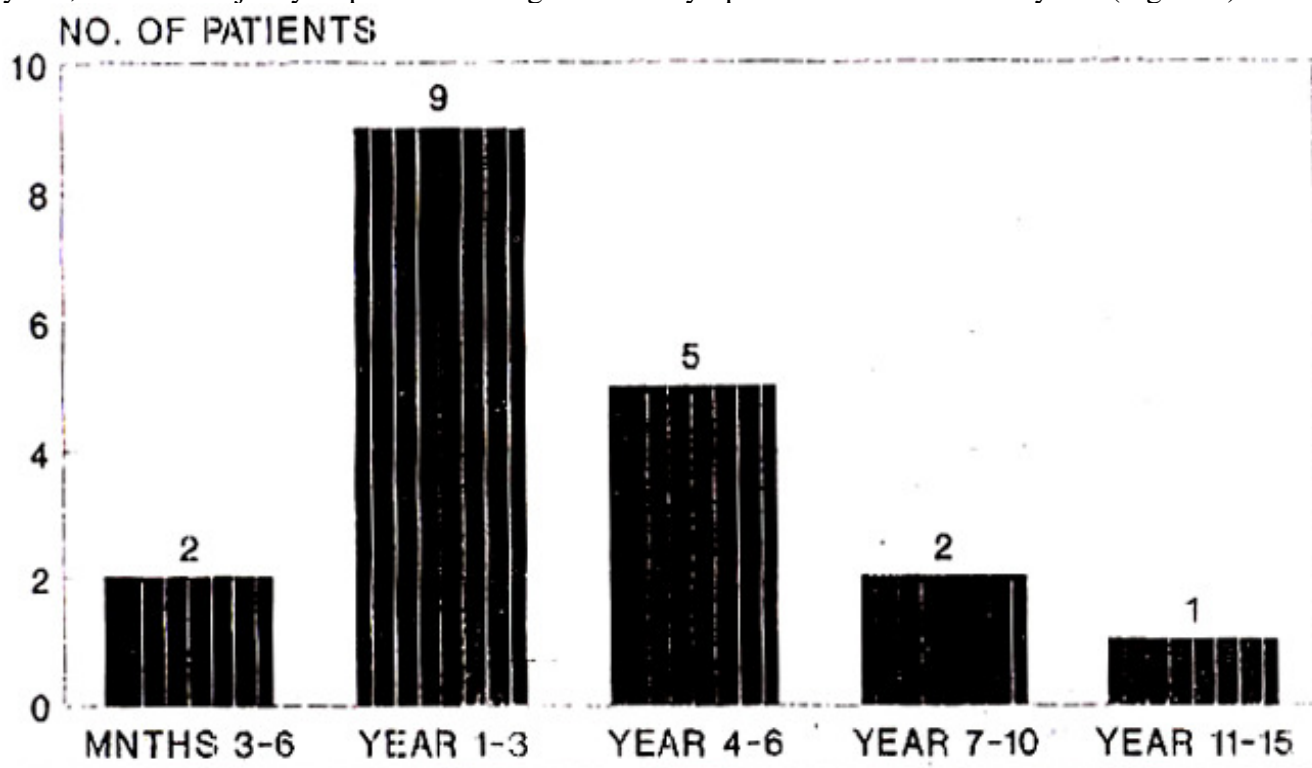


Figure 1. Duration of diarrhoea.

Physical examination and in particular examination of the abdomen was normal in all patients. There was no clinical evidence of malnourishment.

Investigations and Results

Stool examinations and cultures on multiple occasions were negative in all patients. Similarly hemoglobin, ESR, total and differential white cell counts, liver function tests, albumin and electrolytes were normal. Eleven patients had a hydrogen breath test to look for lactose intolerance, all of which were within the normal limits. Twelve (63%) patients had a barium enema which were normal except two, where mild sigmoid diverticular disease was shown. A small bowel enema or barium follow through examination was performed in 16(84%) patients and all were normal. All nineteen patients underwent a colonoscopic examination. In each case the colonic mucosa was reported as looking normal and multiple biopsies were taken from various sites in the colon. Twelve patients also had an upper gastrointestinal endoscopy, biopsies from second part of the duodenum and duodenal aspirate for giardia to rule out malabsorption. Co-incidental upper gastrointestinal findings were mild esophagitis in two patients and duodenitis in one. Duodenal biopsies were normal in all but one patient who had mild inflammation. Duodenal aspirates were negative for giardia in all cases.

Colonic Biopsies

Biopsy specimens were coded and two pathologists were asked to re-report them individually. They were not told about the previous reports on the biopsies and were asked to determine if, in their view, chronic inflammation was present or not. The main histological features were infiltration of the lamina propria with predominantly chronic inflammatory cells consisting of various admixtures of plasma cells, lymphocytes, macrophages and the occasional polymorphonuclear leukocytes (Figures 2 and 3).

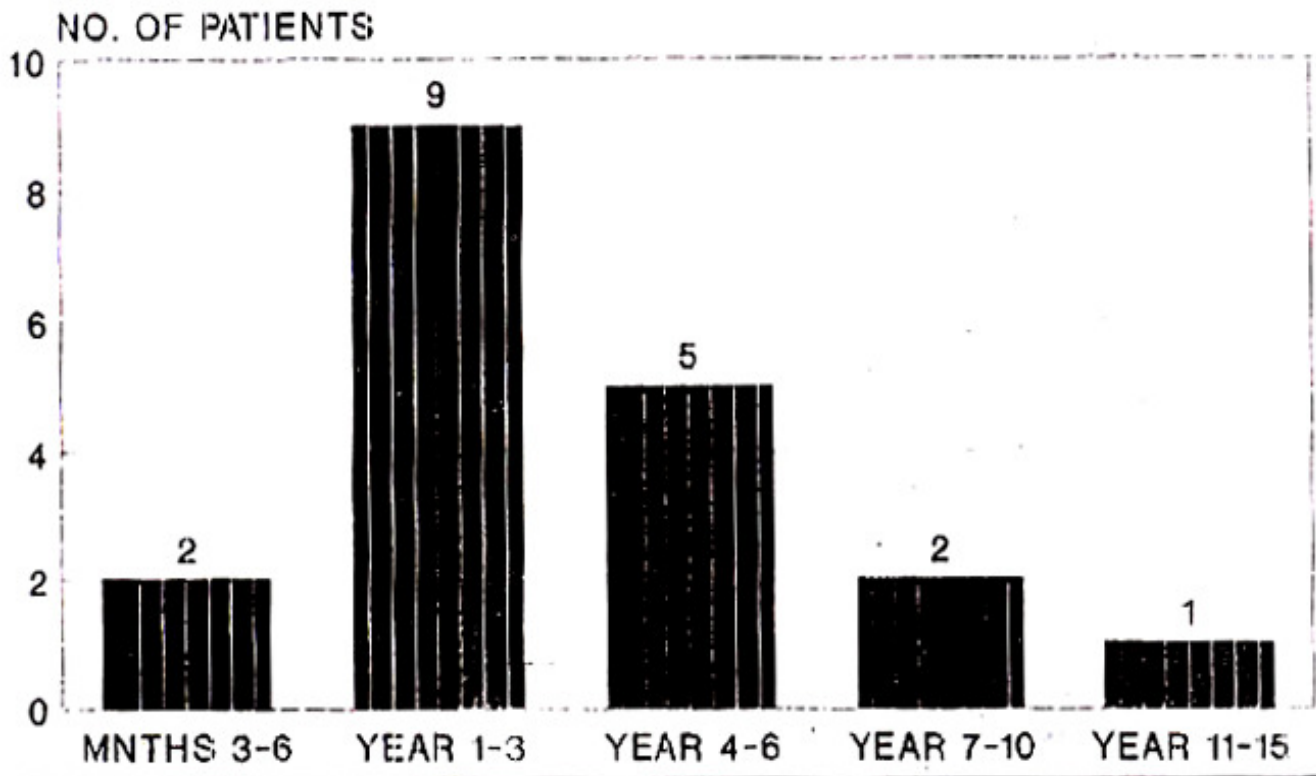


Figure 1. Duration of diarrhoea.

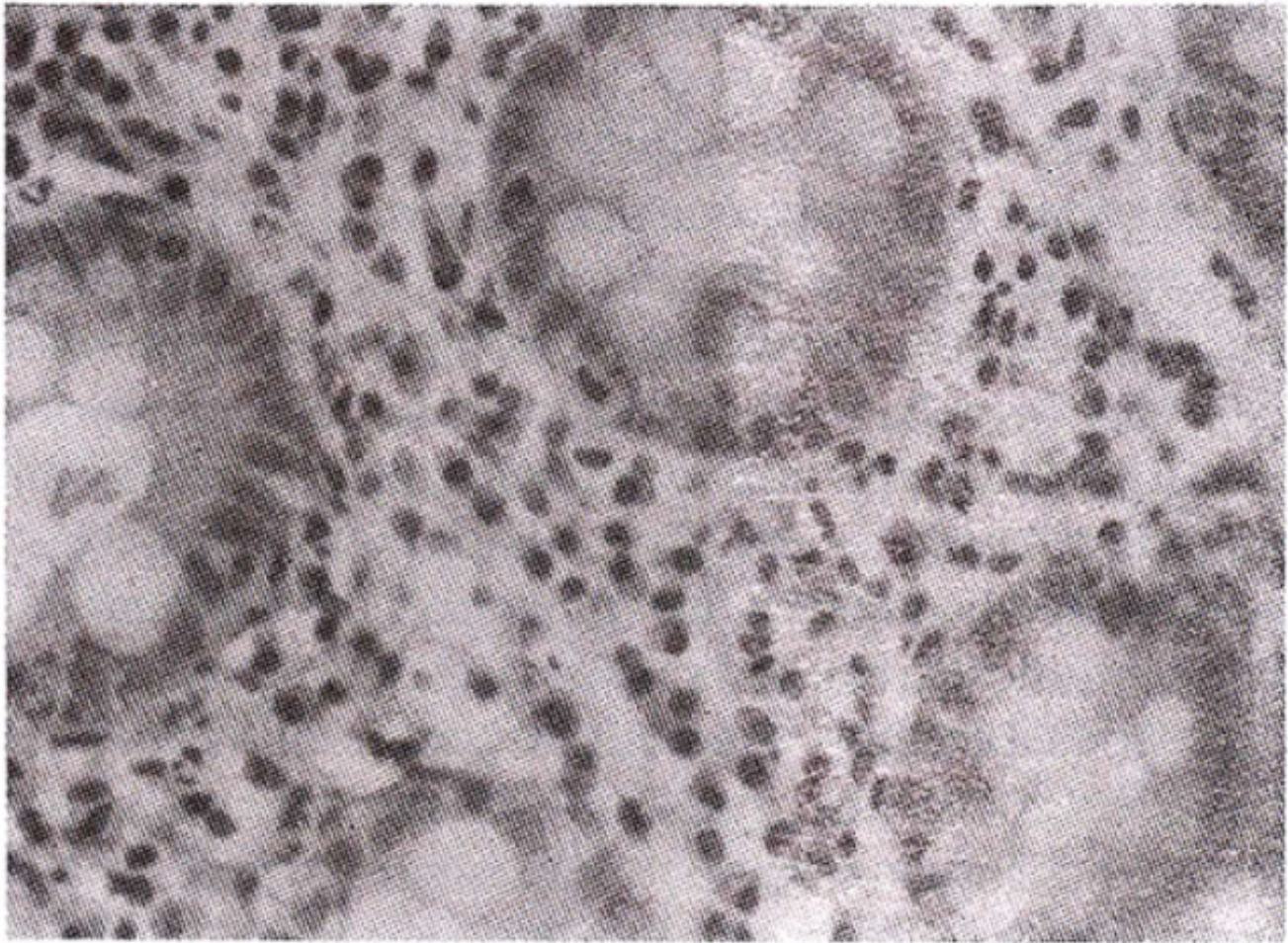


Figure 3. The crypts show mild hyperplastic changes with no crypt abscesses. The lamina propria shows plasma cells, lymphocytes and neutrophil polymorphs (H&E x 400).

There was no evidence of ulceration, crypt distortion, cryptitis, goblet cell depletion or granuloma formation. Features of chronic inflammation were present in biopsy specimens from multiple sites, thus suggesting a pancolonic involvement. Rectal biopsies from all patients showed inflammation but this did not tend to differ in severity from other colonic sites.

Treatment

A variety of drugs were used to treat these patients. In general, there was no response to treatment with mebeverine, peppermint oil, isphagula husk, chlordiazepoxide or multiple courses of metronidazole. Three patients were given salazopyrine and interestingly, one patient responded very well.

Discussion

Read and Fortran² first used the term “microscopic colitis” in patients they studied for chronic intractable diarrhoea and found minor histological changes in the colon as the sole abnormality on extensive investigation. They were initially uncertain whether these inflammatory changes played a causative role. However, in a later study², the same group demonstrated marked colonic malabsorption of water and electrolytes in patients with microscopic colitis, thus suggesting a cause and effect relationship. Since then further studies have concluded^{3,4,6} that microscopic colitis may be responsible for a proportion of their patients with chronic diarrhoea. The clinical profiles and results of investigations in our patients are similar to those of other studies^{3,4}, except that the sex ratio was almost

equal. The majority of our patients had been investigated elsewhere previously without a definitive diagnosis being made and were eventually referred to us. The intensity of investigations may have varied between our patients, as they were done in different gastroenterology clinics in our hospitals. Nonetheless there was no evidence of an infective agent, inflammatory bowel disease, nutrient malabsorption and as far as we could determine, laxative abuse. In addition, there was no evidence of melanosis coli on colonic biopsies. One of the major obstacles in the acceptance of microscopic colitis as a distinct disease entity is the fact that normal colonic mucosa may contain some inflammatory cells. Therefore, the pathologist's interpretation, of when this inflammatory response becomes abnormal, is all important. We tried to minimize this problem by only including cases where two senior pathologists independently diagnosed the presence of inflammation. Other studies have used similar methods^{6,7}. It is possible that microscopic colitis and collagenous colitis (another cause of chronic watery diarrhoea) represent variants of the same disease⁸, as most clinical and demographic features of both diseases are similar. The etiology and pathogenesis of both conditions is unknown. We reviewed biopsies from all patients in our study looking particularly for the broad sub-epithelial collagen band, the hallmark of collagenous colitis⁹, but did not find this in any of our cases. Microscopic colitis appears to be a separate clinical entity to "minimal change colitis"¹⁰ in which, despite normal appearances on sigmoidoscopy and barium enema, overt changes of Crohn's colitis proximal to the rectum are seen at colonoscopy. Patients with microscopic and collagenous colitis end up being treated with a variety of drugs as our study demonstrates. There was no clear response to a particular drug, although one of our patients treated with salazopyrine showed symptomatic improvement. Other studies have also reported a significant response to salazopyrine and steroids^{3,6}. However, the routine use of these drugs cannot be recommended due to the paucity of controlled therapeutic trials in this condition. We conclude that the diagnosis of microscopic colitis should be considered in patients with chronic diarrhoea and that multiple colonic biopsies should be taken even if the colonic mucosa appears endoscopically normal. Ours highlights this clinical entity from a developing country where patients with chronic diarrhoea are often assumed to have a chronic infection and treated with unnecessary courses of potentially toxic antibiotics.

References

1. Kingham. J.G.C. Microscopic colitis. *Gut*, 1991;32:234-35.
2. Read, N.W., Krejs, G.J., Read, M.G. et al. Chronic diarrhoea of unknown origin. *Gastroenterology*, 1980;78:264-71.
3. Giardiello, F.M., Lazenby, A.J., Bayless, T.M. et al. Lymphocytic (microscopic) colitis. Clinicopathological study of 18 patients and comparison to collagenous colitis. *Dig. Dis. Sci.*, 1989;34:1730-38.
4. Sytwestrowicz, T., Kelly, J.K. Hwarig. W.S. et al. Collagenous colitis and microscopic colitis: the watery diarrhoea - colitis syndrome. *Am.J. Gastroenterol.*, 1989;84:763-67.
5. Bo-Linn, G.W., Vendrell, DO., Lee, B. et al. An evaluation of the significance of microscopic colitis in patients with chronic diarrhoea. *J.Clin. Invest.*, 1985;75:1559-69.
6. Kingham, J.G.C., Levison, D.A., Ball, J.A., Dawson, A.M. Microscopic colitis - a cause of chronic watery diarrhoea. *Br.Med.J.*, 1982;285:1601-4.
7. Lazenby. AJ., Yardley. J.H., Giardiello, F.M. et al. Lymphocytic ("microscopic") colitis: comparative histopathologic study with particular reference to collagenous colitis. *Hum. Pathol.*, 1989;20:18-28.
8. Jesserun, J., Yardley, J.H. Microscopic and collagenous colitis: different names for the same condition? *Gastroenterology*, 1986;91:1583-84.
9. Gledhill, A. and Cole, F.M. Significance of basement membrane thickening in the human colon. *Gus*, 1984;25:1085-88

10. Elliot, P.R., Williams, C.B., Lennard-Jones, J.E. et al. Coloscopic diagnosis of minimal change colitis in patient with a normal sigmoidoscopy and normal air-contrast barium enema. *Lancet*, 1982;1:650.51.