



THE AGA KHAN UNIVERSITY

eCommons@AKU

---

Department of Paediatrics and Child Health

Division of Woman and Child Health

---

January 2016

# Atrial thrombus in a premature newborn following cardio-pulmonary resuscitation

Syed Rehan Ali

*Aga Khan University*, rehan.ali@aku.edu

Shakeel Ahmed

*Aga Khan University*, shakeel.ahmed@aku.edu

Nadeem Aslam

Heeramani Lohana

Follow this and additional works at: [https://ecommons.aku.edu/pakistan\\_fhs\\_mc\\_women\\_childhealth\\_paediatr](https://ecommons.aku.edu/pakistan_fhs_mc_women_childhealth_paediatr)



Part of the [Cardiovascular System Commons](#), [Pediatrics Commons](#), and the [Respiratory System Commons](#)

---

## Recommended Citation

Ali, S. R., Ahmed, S., Aslam, N., Lohana, H. (2016). Atrial thrombus in a premature newborn following cardio-pulmonary resuscitation. *JCPSP: Journal of the College of Physicians and Surgeons Pakistan*, 26, S48-S49.

**Available at:** [https://ecommons.aku.edu/pakistan\\_fhs\\_mc\\_women\\_childhealth\\_paediatr/199](https://ecommons.aku.edu/pakistan_fhs_mc_women_childhealth_paediatr/199)

See discussions, stats, and author profiles for this publication at: <https://www.researchgate.net/publication/304847519>

# Atrial Thrombus in a Premature Newborn Following Cardio-Pulmonary Resuscitation

Article · June 2016

---

CITATIONS

0

---

READS

43

4 authors, including:



[Syed Rehan Ali](#)

Aga Khan University Hospital, Karachi

41 PUBLICATIONS 89 CITATIONS

[SEE PROFILE](#)



[Shakeel Ahmed](#)

Aga Khan University, Pakistan

38 PUBLICATIONS 83 CITATIONS

[SEE PROFILE](#)

All content following this page was uploaded by [Syed Rehan Ali](#) on 11 July 2016.

The user has requested enhancement of the downloaded file. All in-text references [underlined in blue](#) are added to the original document and are linked to publications on ResearchGate, letting you access and read them immediately.

# Atrial Thrombus in a Premature Newborn Following Cardio-Pulmonary Resuscitation

Syed Rehan Ali, Shakeel Ahmed, Nadeem Aslam and Heeramani Lohana

## ABSTRACT

Critically ill newborns, whether term or preterm, are at great risk for developing symptomatic thromboembolic disease. Comorbidities like inflammation, DIC, fluctuations in cardiac output, congenital heart disease, as well as central venous or arterial catheters, are the predisposing risk factors. Clinically symptomatic or asymptomatic cases are usually picked up by echocardiography, usually done for other indications. Management usually comprises of observation, heparin therapy, thrombo-embolectomy, and catheter directed revascularization. We present a case of premature neonate who developed thrombus at inter-atrial septum as a possible consequence of cardiopulmonary resuscitation, detected by echocardiography. Conversely, there is always a possibility of paradoxical emboli in neonates with patent foramen ovale (PFO). Subsequent clinical course remained asymptomatic and baby was discharged home after 6 weeks with cardiac follow-up. Atrial septal findings of organized clot/thrombus in asymptomatic newborns need to be correlated with the details of neonatal care. Long-term follow-up is dependent on underlying pathology.

**Key Words:** Cardio-pulmonary resuscitation (CPR). Thrombus. Atrial septum. Premature newborn.

## INTRODUCTION

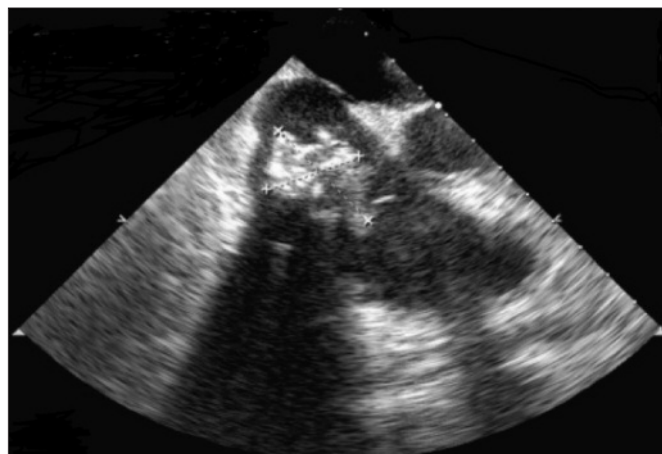
Cardio-pulmonary resuscitation (CPR) can cause atrial thrombus which may give rise to cardiac failure and appearance of a murmur. Spontaneous regressions have been reported.<sup>1</sup> Central venous lines (CVL) used in the supportive care of premature newborns are more frequently associated with venous thrombosis, embolism, persistent sepsis, endocarditis, arrhythmias and cardiac tamponade.<sup>2</sup> Despite lack of consensus on the choice of anti-thrombolytic agents, most authors agree about the danger inherent in intra-cardiac thrombosis; and hence, the desirability of early treatment.

The report describes a premature newborn with intra-atrial thrombus, possibly secondary to CPR.

## CASE REPORT

A 2-day newborn, 26 weeks premature, was admitted in neonatal intensive care unit for care of prematurity and respiratory distress syndrome (RDS). Baby was intubated in labour and delivery room for apnea and gasping. Just after been transferred to NICU, baby developed cardio-pulmonary arrest during central line insertion, needed chest compressions and intravenous epinephrine. Subsequently, baby was referred for the evaluation of a heart murmur on day 3 of life. Echocardiography showed a large echogenic thrombus in the right

atrium attached to the inter-atrial septum. Thrombus extended into right ventricle through tricuspid valve (Figure 1). No other structural abnormalities were detected. Sepsis screen was negative. Coagulation profile was within normal limits. Patient was not polycythemic (PCV 54%). The newborn remained asymptomatic and was subsequently discharged home after 6 weeks with cardiac follow-up at 2 and 4 months. The echocardiographic findings were resolved at 4 months.



**Figure 1:** Echogenic thrombus seen in right atrium attached to inter-atrial septum extending into right ventricle through tricuspid valve.

## DISCUSSION

The incidence of thrombus at atrial septum in preterm newborns is yet unknown. Incidence reported in international registries has varied from 2 to 5 per 1000 births.<sup>1</sup> There is approximately equal distribution occurrence between venous and atrial thrombus formation. Atrial fibrillation during CPR (also called AFib)

*Department of Paediatrics and Child Health, The Aga Khan University Hospital, Karachi.*

*Correspondence: Dr. Shakeel Ahmed, Consultant Paediatrician, Department of Paediatrics and Child Health, The Aga Khan University Hospital, Karachi.*

*E-mail: shakeel.ahmed@aku.edu*

*Received: June 27, 2015; Accepted: December 03, 2015.*

is a quivering or irregular heartbeat (arrhythmia) that can lead to thrombus formation.<sup>1</sup>

Several possible mechanisms by which cardio-pulmonary resuscitation can cause thrombosis include damage to vessel walls, disrupted blood flow, damage endothelial cells and acquired thrombophilia in critical illness/sepsis.<sup>2</sup>

The organized clots which generally seal any inter-atrial communication, usually do not require anticoagulation but need periodic follow-up.<sup>2</sup> The authors believe that the size and age of the thrombus are of crucial importance for functional disturbances and cardiac signs.

The thrombus discussed in this report, alongwith the inter-atrial septum, thought to be associated with cardio-pulmonary arrest, are more often seen with umbilical lines as umbilical catheters tend to stream toward the foramen ovale and their position can move during extended periods of use due to newborn handling and care. The secondary risks involved with inter-atrial clot include persistent bacteremia, endocarditis, and the potential for embolism.<sup>3</sup>

There is limited information available on thrombosis in newborns, hence specific treatment recommendations cannot be made. Decisions to treat or not-to-treat are both lively judgments. Management of each baby needs to be individualized, and should always include consultation with a paediatric hematologist. Should these silent thrombi be treated is a predicament still unreciprocated. Spontaneous regression of an intra-cardiac thrombus has been reported,<sup>4</sup> but most authors agree about the danger innate in intra-cardiac thrombosis; and hence, the prudence of early treatment.

The right atrial thrombi may enlarge, causing obstruction of the tricuspid valve orifice (potentially leading to heart failure) or inferior/superior vena caval syndrome; macro- or micro-embolization in systemic or pulmonary circulation may also occur.<sup>5</sup> A sudden deterioration in respiratory function can be caused by occlusion of the pulmonary artery by a life-threatening embolization.

Infected atrial thrombosis, on the other hand, may cause multiple septic embolization and lead to a prolonged septic state or recurrent sepsis.<sup>6</sup>

Understanding with typical thrombolytic agents in intra-cardiac thrombolysis of preterm newborns is very inadequate.<sup>1</sup> Practice of thrombolytic agents, such as heparin and streptokinase, may be complicated in newborns by intra-cranial and/or systemic bleeding and may produce fibrin fragmentation, precipitating pulmonary embolization.<sup>7</sup> Newer plasminogen activators, including recombinant tissue type plasminogen activator (rt-PA), are more clot selective; hence, may represent a good alternative for thrombolytic treatment in neonatal practice.<sup>8</sup>

## REFERENCES

1. Russo G, Trappan A, Benettoni A. Unusual left atrial appendage thrombus in a neonate with normal heart after sustained supraventricular tachycardia. *Int J Cardiol* 2008; **131**:e17-9.
2. Sheen A, De Oliveira ER, Kim RW, Parham D, Lakshmanan A. Atrial thrombus in a neonate: A diagnostic challenge. *AJP Rep* 2015; **5**:e18-21.
3. Fujiwara K, Yoshizawa K, Sakazaki H. Thrombus in the left atrial appendage: A case report of neonate. *Cardiol Young* 2015; **25**:560-2.
4. Abid D, Ben Ameer S, Ly M, Daoud E, Mrabet S, Hachicha M, et al. Unusual intra-atrial thrombus in a neonate with co-arcuation of the aorta. *Arch Pediatr* 2014; **21**:995-7.
5. B AG, Mathew RC. Left atrial thrombus in a neonate with normal heart after sustained supraventricular tachycardia. *J Clin Diagn Res* 2014; **8**:PD01-2.
6. Aswani R, Werthammer J, Shrestha P, Heydarian M. Left atrial appendage thrombus in a preterm neonate in sinus rhythm with septic shock. *Pediatr Cardiol* 2010; **31**:1116-7.
7. de Winkel N, Becker K, Vogt M. Echogenic mass in the right atrium after surgical ventricular septal defect closure: Thrombus or tumour? *Cardiol Young* 2010; **20**:86-8.
8. Al Dhahri KN, Sandor GG, Duncan WJ. Intra-atrial thrombus in a neonate with co-arcuation of the aorta. *Cardiol Young* 2006; **16**:392-4.

