



THE AGA KHAN UNIVERSITY

eCommons@AKU

Department of Radiology

Medical College, Pakistan

January 1995

Effectiveness of percutaneous nephrostomy in reversing obstructive renal failure

I Ahmed

I H. Rizvi

A Aslam

M N. Ahmed

Aga Khan University, nadeem.ahmed@aku.edu

Y A. Hussain

Follow this and additional works at: https://ecommons.aku.edu/pakistan_fhs_mc_radiol



Part of the [Radiology Commons](#)

Recommended Citation

Ahmed, I., Rizvi, I. H., Aslam, A., Ahmed, M. N., Hussain, Y. A. (1995). Effectiveness of percutaneous nephrostomy in reversing obstructive renal failure. *Journal of Pakistan Medical Association*, 45(1), 16-18.

Available at: https://ecommons.aku.edu/pakistan_fhs_mc_radiol/180

Effectiveness of Percutaneous Nephrostomy in Reversing Obstructive Renal Failure

Pages with reference to book, From 16 To 18

Iftikhar Ahmed, Imtiaz Hussain Rizvi, Mohammad Nadeem Ahmed, Yusuf A. Hussain (Departments of Radiology, The Aga Khan University Medical Centre, Karachi.)

Asif Aslam (Departments of Community Health Sciences, The Aga Khan University Medical Centre, Karachi.)

Abstract

A retrospective analysis of 34 patients of obstructive renal failure, initially managed by percutaneous nephrostomy was performed. Pre procedure blood biochemical profile was compared with upto one week follow-up of blood chemistry. There was a decline of 71.1% and 56.08% (P-values 0,0001 and 0.0028) in the mean values of serum creatinine and blood urea nitrogen respectively at 7 days after the procedure. Improvement in blood biochemical profile was solely dependent on performance of percutaneous nephrostomy (JPMA 45:16,1995).

Introduction

Percutaneous nephrostomy is a commonly performed image guided intervention to relieve urinary obstruction¹⁻⁴. In the modern radiological practice, most common indication for this procedure is obstructive uropathy that is frequently caused by calculus disease⁵. Percutaneous nephrostomy itself is the definitive therapeutic intervention in cases where transient supra-vesical urinary diversion is needed. Percutaneous access to the renal collecting system is also used for other endourological procedures^{6,7}. Elective surgical management may be deferred until the blood chemistry has returned towards normal in patients who cannot be offered definitive percutaneous management. Nephrostomically produced urinary diversion helps reverse the changes in the renal parenchyma related to back pressure. Improvement in biochemical profile after relief of obstruction is well known in experimental animals and humans⁸⁻¹⁰. Literature review, however, has revealed a lack of studies, quantitatively analyzing the change in blood chemistry in response to supra-vesical urinary diversion provided by percutaneous nephrostomy. In this paper, the effectiveness of percutaneous nephrostomy was assessed in reversing the biochemical manifestations of obstructive renal failure in clinical settings.

Patients and Methods

This is a descriptive study of patients who had percutaneous nephrostomy performed within a period of two years from January, 1990 at the Department of Radiology, The Aga Khan University Medical Centre. Two criteria of case selection were used for the study: a) All cases of obstructive renal failure initially treated by percutaneous urinary diversion, b) All cases in which the complete biochemical profile was available for retrospective evaluation. A total of 34 cases were thus selected. The nephrostomies were performed either as an emergency or elective procedure by the staff and the senior residents having different levels of expertise. The procedure was first explained to the patient. Local anaesthesia was used in all the cases except one 3 year old child who was given inhalational anaesthetics. Premedication with antibiotics and sedatives was used selectively in patients in whom the need was clinically obvious. In all cases, initial localization was performed by ultrasound^{11,12}. This in most cases was followed by antegrade pyelogram¹³ with the patient in prone oblique position¹⁴. For catheter insertion, angiographic guidewire exchange or catheter sheathed needle insertion

techniques^{15,16} were used under fluoroscopic cover. The catheters were pulled from 7Fr radio-opaque polyethylene tubing (Cook Inc.) in the Department of Radiology. For securing the catheters to the skin, silk stay sutures were used. Baseline biochemical investigations included serum electrolytes, creatinine and blood urea nitrogen levels. Blood urea nitrogen and serum creatinine were selected as renal function parameters¹⁷. These tests are routinely performed on patients suspected of having deranged renal functions. Serum creatinine and blood urea nitrogen levels were analyzed before the insertion of the nephrostomy tube and were followed-up at one, three and seven days intervals after the tube placement. The analysis was performed using "Excel" computer software and paired student t test of statistical significance was applied.

Results

Out of 34 patients studied, 29 were males and 5 females, between 3 and 78 years of age. Percutaneous nephrostomy was achieved in all the 34 patients without failure in first attempt. Thirteen patients needed bilateral tube placement. Twenty-six nephrostomy tubes were placed in patients having calculus disease; of these, 8 presented in emergency service for acute urinary obstruction while 18 suffered chronic renal obstruction. Urinary diversion was performed in 8 patients to relieve chronic obstruction caused by urinary tract malignancy. The procedures were relatively free of complications, two patients needing long term drainage, dislodged their nephrostomy tubes after discharge from the hospital. All patients had transient hematuria which did not require transfusion and lasted less than 48 hours. In all the patients, a gradual decline in serum creatinine and blood urea nitrogen values (Figure) was observed.

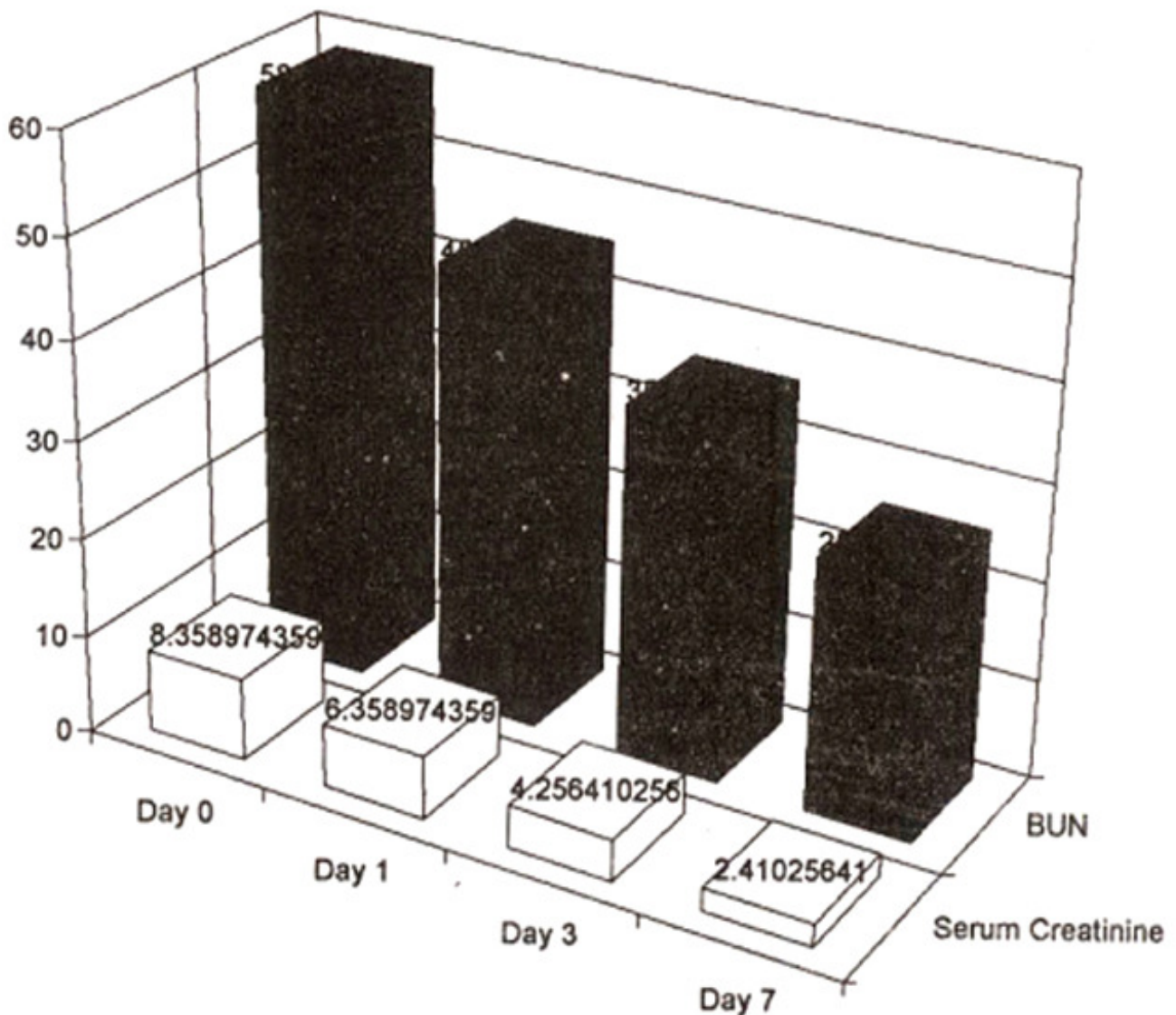


Figure. Change in mean values of serum creatinine and BUN.

At one week follow-up, 71.1% and 56.0% decline in the serum creatinine and blood observed (P values 0.0001 and 0.0028 respectively). All the patients showed marked clinical improvement evidenced by biochemical profile and symptomatic relief.

Discussion

Obstructive uropathy is a backpressure phenomena which leads to renal parenchymal damage. The extent of damage is dependent on duration, completeness and level of obstruction and the vascular status of the kidney¹⁸. The gradual decline in the mean values of serum creatinine and blood urea nitrogen as depicted in the figure demonstrates the effectiveness of percutaneous nephrostomy in obstructive renal failure patients. In general, patients with higher baseline serum creatinine and blood urea nitrogen values did not return to normal. All these patients had long standing disease resulting in renal parenchymal damage. There was, however, a statistically significant decrease in their serum creatinine and blood urea nitrogen values (P value 0.0001 and 0.0028 respectively), thus showing a direct relationship between the performance of percutaneous nephrostomy and the change in

biochemical profile. This study shows that supra-vesical urinary diversion provided by percutaneous nephrostomy is extremely effective in restoring the renal functions towards normal in patients having obstructive renal failure. Nephrostomy is a very effective intervention for patients requiring definitive urinary surgery, but with high risk of anaesthetic complications and those in need of urgent urinary diversion.

References

1. Barbric, Z.L. and Wood, B.P, Emergency percutaneous nephrostomy. Experience with 34 patients and review of literature. *AJR.*, 1977; 128:435-58.
2. Barbric, Z.L. Percutaneous nephrostomy for urinary tract obstruction. *AJR.*, 1984; 143:803-809.
3. Barbric, Z.L. Interventional urology. *Radiol. Clin. North Am.*, 1979;17:413-33.
4. Perinetti, E., Catalona, W.J., Manley, C.B. et al. Percutaneous nephrostomy: indications, complications and usefulness. *J. Urol.*, 1978; 120:156-58.
5. Stables, D.P., Ginsberg, N.J. and Johnson, M.L. Percutaneous nephrostomy: A series and review of literature. *AJR.*, 1978; 130:75-82.
6. Smith, AD., Paul, H.L. and Fraley, E.E. Application of percutaneous nephrostomy: New challenges and opportunities in endourology. *J. Urol.*, 1979;121 :382.
7. Lang, E.K. and Price, IT. Redefinition of indications of percutaneous nephrostomy. *Radiology*, 1983;147:419-26.
8. Better ,O.S., Arieff, Al., Massiy, S.G. et al. Studies on renal function after relief of complete unilateral ureteral obstruction of three months duration in man. *Am. J. Med.*, 1973;54:234-40.
9. Muldowney, F.P., Duffy, G.J., Kelly, D.G. et al. Sodium diuresis after relief of obstructive uropathy. *N. Engl. J. Med.*, 1966;274: 1294-98.
10. Brunschwing, A., Barber, H.R. and Roberts, S. Return of renal function after varying periods of ureteral obstruction. A clinical study. *JAMA.*, 1964;188:5-8.
11. Pederson, iF., Cowan, D.F., Krist, J. et al. Ultrasonically guided percutaneous nephrostomy. *Radiology*, 1976; 119:429-32.
12. Hary, G.Z., Howard, M., Marc, P. et al. Percutaneous nephrostomy comparison of sonographic and fluoroscopic guidance. *Radiology*, 1981; 147:925-27.
13. Kaye, K.W. Renal anatomy for endourologic stone removal. *J. Urol*, 1983; 130:647-48.
14. Jefery, H.N. and Richard, C.P. Antegrade pyelography. In: Christos, A. Adhanasoulis, Richard, C., Pfister, Reginald, E. Green, Glenn, H. Roberson (ads.) *Interventional Radiology*. Philadelphia WB Saunders, 1982;pp.437-54.
15. Harris, RD., McCullough, D.L. and Talner, L .B. Percutaneous nephrostomy. *J. Urol.*, 1976;115:628-31.
16. Raz, S. A simple method of pyonephrosis drainage. *Lancet*, 1971 ;2:529-30.
17. Martin, P.J. Laboratory Investigations. In: O'Reilly PH. (eds). *Obstructive uropathy*. Great Britain Berlin, Heidelberg, Springer- Verlag, 1986;pp.631-70.
18. Gillenwater, J.Y. The pathophysiology of urinary obstruction. In: Campbell MF and Harrison JR (eds.) *Urology Vol. 3*. eds. Philadelphia, WB Saunders Co, 1970, pp. 58-186.