



THE AGA KHAN UNIVERSITY

eCommons@AKU

Section of Cardiothoracic Surgery

Department of Surgery

7-16-2020

A rare case of constrictive pericarditis as initial manifestation of paediatric anaplastic large cell lymphoma requiring urgent pericardiectomy

Sara Iqbal

Aga Khan University, sara.iqbal@aku.edu

Abdul Ahad Sohail

Aga Khan University, abdul.ahad@aku.edu

Narmeen Asif

Aga Khan University, narmeen.asif@aku.edu

Muhammad Rahil Khan

Aga Khan University

Sabeehuddin Siddique

Aga Khan University, sabeeh.siddique@aku.edu

See next page for additional authors

Follow this and additional works at: https://ecommons.aku.edu/pakistan_fhs_mc_surg_cardiothoracic



Part of the [Cardiology Commons](#), [Cardiovascular Diseases Commons](#), [Oncology Commons](#), [Pathology Commons](#), and the [Surgery Commons](#)

Recommended Citation

Iqbal, S., Sohail, A. A., Asif, N., Khan, M. R., Siddique, S., Fatimi, S. (2020). A rare case of constrictive pericarditis as initial manifestation of paediatric anaplastic large cell lymphoma requiring urgent pericardiectomy. *International Journal of Surgery Case Reports*, 73, 281-284.

Available at: https://ecommons.aku.edu/pakistan_fhs_mc_surg_cardiothoracic/176

Authors

Sara Iqbal, Abdul Ahad Sohail, Narmeen Asif, Muhammad Rahil Khan, Sabeehuddin Siddique, and Saulat Fatimi



Contents lists available at ScienceDirect

International Journal of Surgery Case Reports

journal homepage: www.casereports.com

A rare case of constrictive pericarditis as initial manifestation of paediatric anaplastic large cell lymphoma requiring urgent pericardiectomy

Sara Iqbal^a, Abdul Ahad Sohail^{a,*}, Narmeen Asif^a, Muhammad Rahil Khan^b, Sabeehuddin Siddique^c, Saulat Hasnain Fatimi^a

^a Department of Surgery, Aga Khan University Hospital (AKUH), Karachi, Pakistan

^b Department of Paediatric Hematology and Oncology, The Indus Hospital, Karachi, Pakistan

^c Department of Pathology, AKUH, Karachi, Pakistan

ARTICLE INFO

Article history:

Received 19 May 2020

Received in revised form 8 July 2020

Accepted 8 July 2020

Available online 16 July 2020

Keywords:

Constrictive pericarditis

Pericardiectomy

Anaplastic large cell lymphoma

ABSTRACT

Constrictive pericarditis (CP) is a rare end stage inflammatory disorder affecting both parietal and visceral pericardium leading to a right heart failure. Malignancy is the least common cause of CP. Anaplastic large cell lymphoma (ALCL) accounts for 10–15% of all Non-Hodgkin lymphomas in children. Very few case reports have reported ALCL that is involving the heart and only two have been published involving pericardium but all were managed medically. We present an interesting case of an 11 year old child who presented with an effusive CP that required urgent Pericardiectomy for managing right heart failure. His histopathology was positive for ALK + ALCL.

© 2020 The Authors. Published by Elsevier Ltd on behalf of IJS Publishing Group Ltd. This is an open access article under the CC BY-NC-ND license (<http://creativecommons.org/licenses/by-nc-nd/4.0/>).

1. Introduction

Constrictive pericarditis (CP) is a rare end stage inflammatory disorder that is characterized by pericardial thickening and the development of dense fibrous adhesions between parietal and visceral pericardium causing myocardial constriction and impaired diastolic filling leading to right heart failure [1,2]. The common causes of CP are idiopathic, prior radiotherapy, renal failure, previous cardiac surgery and infections [1,3]. Malignancy is the least common cause of CP with an incidence of only 4% [4]. Since primary cardiac tumours are uncommon hence malignant CP is mostly metastatic, often arising from adjacent breast or lung carcinomas. Very rarely a lymphoma invades the pericardium through lymphatic spread and can cause CP [1].

Anaplastic large cell lymphoma (ALCL) accounts for 10–15% of all Non-Hodgkin lymphomas in children and majority presents with predominant lymphadenopathy only [5,6]. Although extra-nodal involvement to skin, bones and soft tissue is frequent, very few case reports show heart or pericardial infiltration by lymphoma.

We present a unique case of CP as an initial presentation of ALCL requiring pericardiectomy in a previously healthy child that has not been previously reported in literature to the best of our knowledge.

2. Case report

An 11 year old boy with no prior co-morbidities and no significant past medical, surgical or family history, presented to us with complaints of fever and weight loss for past 3 weeks and worsening dyspnea for about 1 week. He underwent extensive diagnostic workup in another hospital before being referred to our institute which included ultrasound guided pleural tap for bilateral pleural effusions with detailed report showing a lymphocytic exudative effusion but no atypical cells on cytology. On persistence of symptoms, a Computed Tomography (CT) scan of his chest was also done which revealed a thickened pericardium harbouring a moderate pericardial effusion and extensive mediastinal, cervical and axillary lymphadenopathy (Fig. 1).

On arrival to our hospital, he was tachycardiac and required supplemental oxygen. His initial assessment was remarkable for a raised jugular venous pressure (JVP), pedal pitting edema, a pericardial rub and bibasilar crepitation on chest auscultation with mild hepatomegaly. Metabolic panel revealed leucocytosis while arterial blood gas analysis showed respiratory acidosis. Echocardiogram was positive for a loculated pericardial effusion and an inter-ventricular septal bounce along with mildly reduced right ventricular (RV) systolic function. He was diagnosed with CP leading to right heart failure.

* Corresponding author at: Department of Surgery, AKUH, Stadium Road, Karachi, 74800, Pakistan.

E-mail addresses: sara.iqbal@aku.edu (S. Iqbal), abdulahad7@hotmail.com (A.A. Sohail), narmeen.asif@hotmail.co.uk (N. Asif), rahil.khan@tih.org.pk (M.R. Khan), sabeeh.siddique@aku.edu (S. Siddique), saulat.fatimi@aku.edu (S.H. Fatimi).

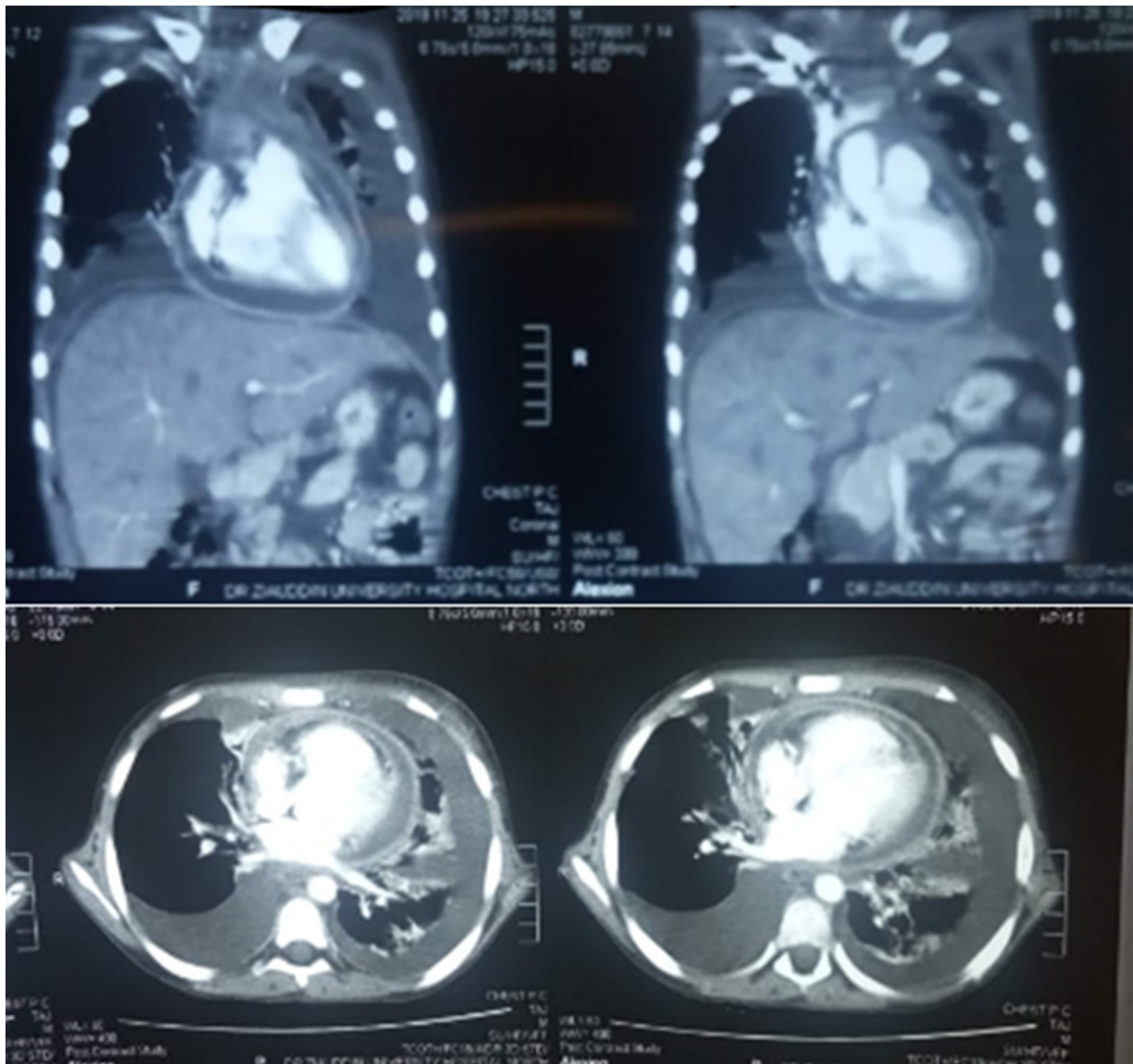


Fig. 1. Coronal and axial sections of CT scan of chest with intravenous contrast showing thickened pericardium with pericardial effusion and bilateral pleural effusion.

After initial stabilisation in intensive care unit (ICU) with heart failure therapy, the patient underwent a complete pericardiectomy off cardiopulmonary bypass under general anaesthesia performed by the primary cardiothoracic surgeon of our institute. Starting with a median sternotomy, we encountered an extremely thick and calcified pericardium firmly encasing the heart which was excised completely from right phrenic to left phrenic nerve in a caudal to cranial fashion. He made good recovery post-operatively and was transferred to his parent institute for further management. His histopathology showed ALCL with positive markers for Alk-protein, CD 43 and CD 30 (Ki-1) (Figs. 2 and 3). On staging for metastatic disease, CT scans showed enlarged hilar, mediastinal and retroperitoneal lymph nodes with renal deposits but no hepatosplenomegaly. Bone marrow trephine biopsy and cerebrospinal fluid cytology showed no bone or central nervous system involvement. He was treated as Stage III on ALCL 99 protocol with an arm containing intermediate dose (3 gm/m²) of Methotrexate without intra-thecal injections or Vinblastine. He had multiple admissions for chemo-toxicity including febrile neutropenia during his treatment. However reassessment CT scans showed complete remission of his disease.

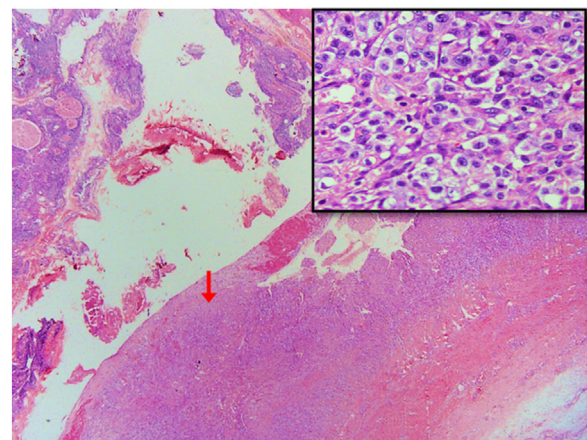


Fig. 2. Low magnification showing pericardial tissue infiltration by the neoplastic lesion (arrow) (H&E; 2X). Inset shows large sized neoplastic cells arranged in sheets with epithelioid morphology (H&E; 40X).

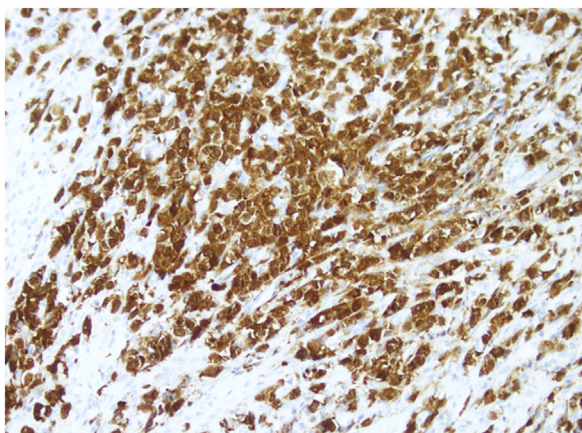


Fig. 3. Immunohistochemical stain ALK-protein shows positivity staining in the neoplastic cells (20X).

3. Discussion

Generally malignancy involving the pericardium often either present as pericardial effusion or CP but it is usually a late secondary feature [1]. Pericardial involvement is seen in only 16% of primary cardiac lymphomas, mostly as pericardial effusion and very rarely causing CP [7]. A study conducted by Bertog et al. on 163 patients undergoing pericardiectomy for CP revealed lymphoma as the aetiology in only 2 of the patients [3]. Buyukbarak et al. reported eight cases that underwent pericardiectomy for CP, out of which only one patient had lymphoma [2].

ALCL is a distinct peripheral T-cell lymphoma which presents as advanced (stage III or IV) disease with lymphadenopathy majorly while extra-nodal involvement sites commonly include skin, bones, soft tissue and lungs. With a strong expression of CD-30 and Anaplastic lymphoma kinase (ALK), ALK + ALCL has a more favourable clinical course than ALK- cases [5]. It has rarely been found to involve the heart even in large case series and only one case reported by Mthusamy et al. showed pericardial involvement with ALCL in an immune-compromised adult patient that was medically managed [7]. In paediatric population, only Juan G et al. reported ALCL involving pericardium in a 2 year old child requiring pericardiocentesis for a cardiac tamponade [5]. In our case, CP appeared as the initial manifestation of ALCL which is an extremely rare phenomenon.

CP presents with signs of right heart failure such as raised JVP, pedal edema, pleural effusions and ascites and is confirmed with transthoracic echocardiography (ECHO) which usually shows thickened pericardium, interventricular septal bounce, plethoric IVC and variation in mitral or tricuspid flow [2]. Pericardiectomy is the definitive treatment of choice in patients with CP and should be done early in case of worsening symptoms or failed medical treatment [8]. In our case, the patient had drastic improvements in his symptoms and his quality of life after surgery.

The specific treatment for cardiac lymphoma is multi-agent chemotherapy with or without adjuvant radiotherapy. Overall five year survival rate after chemotherapy is 70–93% in ALK-1+ ALCL patients [7]. In paediatrics, different co-operative groups like BFM95, COG and ALCL-99 have used different combination chemotherapy regimen with almost similar event free and overall survivals [6].

4. Conclusion

In conclusion, constrictive pericarditis can be the first presenting feature of a lymphoma in a young patient, hence this should

be thoroughly investigated to reach its aetiology and if adequately managed surgically can provide them with a safe time frame for adequate treatment of their primary malignancy with chemotherapy or radiotherapy.

Declaration of Competing Interest

None.

Funding

None.

Ethical approval

This case report is exempted from ethical review of our institute.

Consent

Yes, parental/ guardian consent was taken on behalf of the patient as patient is a minor.

Author contribution

1. Sara Iqbal: Was involved in critical review of the case report, further editing and finalizing of the case report.
2. Abdul Ahad Sohail: Wrote the initial draft of case report. Collected all relevant data from files and patient. Finalized the case report. Literature Search.
3. Narmeen Asif: Wrote the initial draft of case report. Collected all relevant data from files and patient. Finalized the case report. Literature Search.
4. Muhammad Rahil Khan: Was involved in critical review of the case report, further editing and finalizing of the case report.
5. Sabeehuddin Siddique: Was involved in arranging figures in case report and providing histopathology pictures. Also finalized the case report.
6. Saulat Hasnain Fatimi: Was involved in critical review of the case report, further editing and finalizing of the case report.

Registration of research studies

NA.

Guarantor

Sara Iqbal.
Abdul Ahad Sohail.

Provenance and peer review

Not commissioned, externally peer-reviewed.

References

- [1] M. Nabati, K. Yosofnezhad, M. Taghavi, A. Abbasi, A. Ghaemian, Non-Hodgkin's lymphoma presenting as constrictive pericarditis: a rare case report, *J. Tehran Univ. Heart Centre* 11 (April (2)) (2016) 92.
- [2] F. Buyukbayrak, E. Aksoy, M. Dedemoglu, K. Kirali, H.M. Alp, Pericardiectomy for treatment of neoplastic constrictive pericarditis, *Asian Cardiovasc. Thorac. Ann.* 22 (March (3)) (2014) 296–300.
- [3] P. Jariwala, S.S. Kale, CD20 negative B-cell lymphoma presenting as constrictive pericarditis: rare aetiology of acute heart failure, *Indian Heart J.* 68 (September (1)) (2016) S253–7.
- [4] N. Ho, J.L. Myles, D.R. Johnston, D.M. Eicher, D.H. Kwon, A.L. Klein, P. Collier, Pericardial involvement with chronic lymphocytic leukemia/small lymphocytic lymphoma: a rare case of constrictive pericarditis, *CASE* 2 (August (4)) (2018) 147–150.

- [5] G. Mira-Perceval Juan, P.J. Alcalá Minagorre, A.M. Huertas Sánchez, S. Segura Sánchez, S. López Iniesta, F.J. De León Marrero, E. Costa Navarro, M. Niveiro de Jaime, Cardiac tamponade associated with the presentation of anaplastic large cell lymphoma in a 2-year-old child, *Case Rep. Pediatr.* 2015 (2015).
- [6] N. Prokoph, H. Larose, M.S. Lim, G.A. Burke, S.D. Turner, Treatment options for paediatric anaplastic large cell lymphoma (ALCL): current standard and beyond, *Cancers* 10 (April (4)) (2018) 99.
- [7] P. Muthusamy, S. Ebrom, S.D. Cohle, N. Khan, Pericardial involvement as an initial presentation of anaplastic large cell lymphoma, *Can. Fam. Physician* 60 (July (7)) (2014) 638–641.
- [8] Y.H. Cho, H.V. Schaff, Surgery for pericardial disease, *Heart Fail. Rev.* 18 (May (3)) (2013) 375–387.

Open Access

This article is published Open Access at [sciencedirect.com](https://www.sciencedirect.com). It is distributed under the [IJSCR Supplemental terms and conditions](#), which permits unrestricted non commercial use, distribution, and reproduction in any medium, provided the original authors and source are credited.