



THE AGA KHAN UNIVERSITY

eCommons@AKU

Department of Anaesthesia

Medical College, Pakistan

December 2017

Anaesthetic management of nesidioblastosis in two infants

Muhammad Saad Yousuf

Aga Khan University, saad.yousuf@aku.edu

Mohsin Nazir

Aga Khan University, mohsin.nazir@aku.edu

Fauzia Khan

Aga Khan University, fauzia.khan@aku.edu

Follow this and additional works at: https://ecommons.aku.edu/pakistan_fhs_mc_anaesth



Part of the [Anesthesia and Analgesia Commons](#), and the [Anesthesiology Commons](#)

Recommended Citation

Yousuf, M. S., Nazir, M., Khan, F. (2017). Anaesthetic management of nesidioblastosis in two infants. *Journal of Ayub Medical College*, 29(4), 689-691.

Available at: https://ecommons.aku.edu/pakistan_fhs_mc_anaesth/172

CASE REPORT

ANAESTHETIC MANAGEMENT OF NESIDIOBLASTOSIS IN TWO INFANTS

Muhammad Saad Yousuf, Mohsin Nazir Butt, Fauzia Anis Khan

Department of Anaesthesiology, Aga Khan University Hospital Karachi-Pakistan

Nesidioblastosis is the most common cause of non-transient, recurrent and persistent hypoglycaemia in neonates and infants. It is a disorder of diffuse proliferation of beta cells of the pancreas leading to hyperinsulinemia and hypoglycaemia. The main aim is to prevent the severe episodes of hypoglycaemia which can cause damage to the brain and/or mental retardation. In this case report we present two cases of nesidioblastosis and their perioperative anaesthetic course for near-total pancreatectomy. First case was a 7 months old female who had repeated episodes of convulsions since birth. Second case was a 4-month-old female child who again presented with seizures. The challenges faced in the perioperative period were the management of perioperative blood glucose levels and haemodynamic stability.

Keywords: Nesidioblastosis; Hypoglycaemia; Hyperinsulinism; Infant; Anaesthesia

J Ayub Med Coll Abbottabad 2017;29(4):689–91

INTRODUCTION

Nesidioblastosis is a rare cause of hypoglycaemia in infancy due to unregulated over secretion of insulin.¹ Treatment varies from medical management to partial or subtotal pancreatectomy.² Early diagnosis and prompt treatment are essential to prevent developmental delay and neurological damage.

We present two cases of nesidioblastosis in infants with symptoms of severe hypoglycaemia associated with seizures, requiring surgical treatment.

CASE REPORT

Case 1: A seven months old female child weighing 10.7 kg was admitted with repeated episodes of convulsions since day two of life associated with blood glucose level of 25 mg/dl. Physical examination and insulin level were normal. Ultrasonography of abdomen, renal and liver function tests were within normal limits. The infant was managed with intravenous (IV) half strength dextrose saline, two hourly feeds, levetiracetam 100 mg BID and somatostatin 50 mcg subcutaneously (S/C) 6 hourly. She was scheduled electively for a near-total pancreatectomy.

Intravenous infusion of half strength dextrose and all drugs was continued. Blood sugar was checked every 30 minutes using ACCU-Check blood glucose meter and remained between 80 and 150 mg/dl. Intraoperative monitoring included pulse oximetry, electrocardiogram, non-invasive blood pressure, end-tidal carbon dioxide, temperature(oral), minimum alveolar concentration of inhalational agents, blood sugar and urine output. Bladder was catheterized and the urine output was measured.

Induction of anaesthesia was done with IV morphine 0.1 mg/kg, Propofol 2 mg/kg and atracurium 0.5 mg/kg. Trachea was intubated with size 4.0 mm

uncuffed endotracheal tubes. Anaesthesia was maintained with a mixture of oxygen: air (50:50), and isoflurane 1.0–1.3%. A central venous cannula was then inserted in the right femoral vein.

Half strength dextrose saline (50 ml/hr) was infused throughout. Blood sugar was estimated every 30 minutes, which was between 64 and 380 mg/dl (Figure-1). Surgery lasted two hours. Intraoperative haemodynamic parameters were stable and procedure was uneventful. Estimated blood loss was 10 ml. Atropine (0.02 mg/kg) and neostigmine (0.05 mg/kg) was administered, trachea was extubated and patient shifted to neonatal intensive care unit (NICU). Postoperative analgesia was provided by morphine infusion 0.2 mg/hr for next two days.

In the NICU, there were multiple episodes of hypoglycaemia (as low as 42 mg/dl) but no fits. Twelve percent dextrose at the rate of 8 mg/kg/min was started along with somatostatin 20 mcg subcutaneously every 6 hours and levetiracetam 100mg BID. After 48 hours, liquid diet was started 10 ml every 2 hourly and the blood sugar levels were stabilized around (50–260 mg/dl) on oral feeds and half strength dextrose saline. Patient was discharged on the 16th postoperative day. Nesidioblastosis was reported in the histopathological specimen.

Case 2: A four month old female infant weighing 5.7 kg was admitted with complaint of decreased oral intake, repeated episodes of convulsions and blood glucose level was 24 mg/dl. A genetic test for hyperinsulinemia revealed an autosomal recessive congenital hyperinsulinism. Management with intravenous dextrose 12% (20 ml/hr), somatostatin 40 mcg subcutaneously TID, diazoxide 25 ml per oral BID and levetiracetam 50 mg BID was started. A CT scan and ultrasound of the whole abdomen were normal. She was scheduled electively for a near-total pancreatectomy.

Intravenous infusion of 12% dextrose along with all the other drugs was continued. Blood sugar was checked two hourly by ACCU-Check blood glucose meter and was remained between 100 and 250 mg/dl. Anaesthesia was induced with sevoflurane and followed by IV morphine (0.1 mg/kg) and atracurium 0.5 mg/kg. Intraoperative monitoring was same as in previous patient. Trachea was intubated with size 3.0 mm uncuffed endotracheal tube. Anaesthesia was maintained with oxygen and air (50:50), isoflurane (1.0–1.4%) and atracurium boluses. A central venous line was inserted in the right femoral vein. Dextrose solution (10% of 20 ml/hr) and Ringer's lactate was administered at a rate of 10 ml/kg/hr. Blood sugar was estimated every 30 min, and ranged between 108 and 280 mg/dl. Haemodynamic parameters were stable and procedure was uneventful. Estimated blood loss was 10 ml. Atropine (0.02 mg/kg) and neostigmine (0.05 mg/kg) was given to reverse the residual neuromuscular blockade. Atropine (0.02 mg/kg) and neostigmine (0.05 mg/kg) was administered, trachea was extubated and patient shifted to NICU. Postoperative analgesia was provided by morphine infusion 0.1 mg/hr for next two days.

She was initially hyperglycaemic, but later developed two episodes of hypoglycaemia (43 mg/dl and 50 mg/dl), for which 20 ml of 15% dextrose solution was infused slowly. Somatostatin was restarted at 15 mcg/kg/day. Her blood sugar levels were stabilized between 90 and 150 mg/dl. After one day, the patient's condition remained stable. Mother's feed of 30 ml was then started every 2 hours with IV infusion of half strength dextrose saline at the rate of 5 ml/hr. The patient was discharged on the ninth post-operative day. Nesidioblastosis was reported in the histopathological resected specimen. Perioperative blood sugar management of both cases is shown in figure-1.

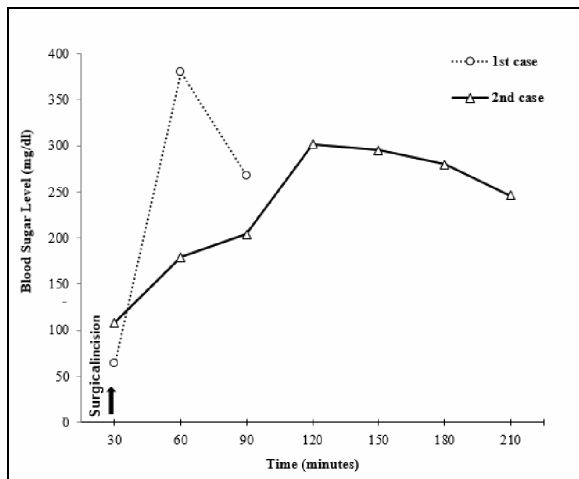


Figure-1: Intraoperative blood sugar level in both patients

DISCUSSION

Nesidioblastosis is due to mutation in the genes regulating the function of the KATP channel located on the beta (β) cell membrane.³ The annual incidence of the sporadic form in infants is 1 in 50,000 births.⁴ Glucose requirement of infants are two to four times that of adults due to relatively larger brain mass as compared to the total body mass and cerebral metabolism.

Diagnostic features of hyperinsulinemia are; serum glucose level <60 mg/dl, non-ketotic hypoglycaemia associated with elevated insulin levels (>10 mU/ml) and sustained glucose requirement in excess of 10 mg/kg/min.

EU glycaemia and prevention of brain injury from neuroglycopenia are the main goals of medical management. Timely nasogastric feeds, dextrose infusion (10–15%) and drugs like diazoxide, somatostatin or glucagon play an important role in medical management. Thiopentone has also been used in medical management.⁵ Phenytoin also inhibits release of insulin from beta-cells and hence may be helpful in the prevention of hypoglycaemia.⁶

Both our children were receiving somatostatin which inhibits endocrine function of the normal pancreas. Somatostatin can inhibit growth hormone which causes poor growth, diarrhoea, vomiting and hepatic impairment leading to electrolyte disturbances.

The goals for our anaesthetic management was to prevent intraoperative hypoglycaemia, avoid thiopentone for patients receiving diazoxide therapy and to maintain fluid shifts of major surgery.

In hyperinsulinemia, the requirement of glucose increases to 10 mg/kg/min. When boluses of high concentration dextrose containing fluids are used, the blood glucose level could exceed renal threshold for glucose causing glycosuria and osmotic diuresis. Hence, it is preferable to use the dextrose containing fluid as maintenance and Ringer lactate as replacement solution. We use half strength dextrose saline (50ml/hr) as a maintenance fluid in our first case while using 10% dextrose (20 ml/hr) as maintenance fluid and Ringer's lactate (10ml/kg/hr) as replacement solution in second case.

Combination of epidural and general anaesthesia in infants also reduces the glucose requirement during surgery.⁷ With the exception of desflurane, most of the volatile anaesthetics depresses the release of insulin and promote glucose intolerance.⁸

After the pancreatic mass excision, rebound hyperglycaemia can occur but it is transient and is resolves spontaneously in most cases. Persistent rebound hyperglycaemia was not seen in our cases.

In summary, the successful anaesthetic management depends on the maintenance of normoglycemia, maintaining fluid management and stabilization of the haemodynamic throughout surgery.

REFERENCES

1. Thomas PM, Cote GJ, Wohlk N, Haddad B, Mathew P, Rabl W, *et al.* Mutations in the sulfonylurea receptor gene in familial persistent hyperinsulinemic hypoglycemia of infancy. *Science* 1995;268(5209):426–9.
2. Kaczirek K, Niederle B. Nesidioblastosis: an old term and a new understanding. *World J Surg* 2004;28(12):1227–30.
3. Glaser B, Thornton P, Otonkoski T, Junien C. Genetics of neonatal hyperinsulinism. *Arch Dis Child Fetal Neonatal Ed* 2000;82(2):F79–86.
4. Aynsley-Green A, Hussain K, Hall J, Saudubray JM, Nihoul-Fekete C, De Lonlay-Debeney P, *et al.* Practical management of hyperinsulinism in infancy. *Arch Dis Child Fetal Neonatal Ed* 2000;82(2):F98–107.
5. Jackson SH. Genetic and metabolic diseases; Inborn errors of metabolism. In: Jackson SH, editor. *Katz's anesthesia and uncommon diseases*. Philadelphia: WB Saunders Company 1990. P.34–6.
6. Goswami J, Somkuwar P, Naik Y. Insulinoma and anaesthetic implications. *Indian J Anaesth* 2012;56(2):117–22.
7. Marles SL, Casiro OG. Persistent neonatal hypoglycemia: Diagnosis and management. *Paediatr Child Health* 1998;3(1):16–9.
8. Tanaka T, Nabatame H, Tanifuji Y. Insulin secretion and glucose utilization are impaired under general anesthesia with sevoflurane as well as isoflurane in a concentration-independent manner. *J Anesth* 2005;19(4):277–81.

Received: 16 February, 2017

Revised: 9 June, 2017

Accepted: 31 August, 2017

Address for Correspondence:

Muhammad Saad Yousuf, Department of Anaesthesiology, Aga Khan University Hospital Karachi-Pakistan

Cell: +92 300 354 0362

Email: saad.yousuf@aku.edu