



THE AGA KHAN UNIVERSITY

eCommons@AKU

Section of Urology

Department of Surgery

8-2018

Role of multi-parametric (mp) MRI in prostate cancer

Syed Muhammad Nazim

Aga Khan University, muhammad.nazim@aku.edu

Ather Enam

Aga Khan University, ather.enam@aku.edu

Basit Salam

Aga Khan University, basit.salam@aku.edu

Follow this and additional works at: https://ecommons.aku.edu/pakistan_fhs_mc_surg_urol



Part of the [Radiology Commons](#), and the [Urology Commons](#)

Recommended Citation

Nazim, S. M., Enam, A., Salam, B. (2018). Role of multi-parametric (mp) MRI in prostate cancer. *JPMA. The Journal of the Pakistan Medical Association*, 68(1), 98-104.

Available at: https://ecommons.aku.edu/pakistan_fhs_mc_surg_urol/161

Role of multi-parametric (mp) MRI in prostate cancer

Syed Muhammad Nazim, Muhammad Hammad Ather, Basit Salam

Abstract

Multi-parametric magnetic resonance imaging is increasingly being recommended as standard imaging modality for prostate cancer diagnosis and staging. It comprises structural T2 and T1 sequences supplemented by functional imaging techniques, i.e. diffusion-weighted, dynamic contrast enhanced and spectroscopic imaging. Pre-biopsy multi-parametric magnetic resonance imaging is recommended for both detection and staging as it avoids biopsy artefact, and when normal, has a negative predictive value of 95% for significant cancer. Magnetic resonance imaging-guided prostate biopsy targets only area(s) considered to be suspicious for prostate cancer, hence resulting in improved accuracy. Dynamic contrast enhancing helps in the detection of cancer and for the assessment of extra-capsular extension, distal urethral sphincter and seminal vesicles involvement. The role of multi-parametric magnetic resonance imaging in follow-up of patients on active surveillance is also increasingly recognised. Its role is now further expanded to facilitate targeted therapies. This review focuses on the evolving role of multi-parametric magnetic resonance imaging in diagnosis and management of prostate cancer.

Keywords: Magnetic resonance imaging, Prostate, Cancer, Multi-parametric.

Introduction

Prostate cancer is one of the most common cancers and leading causes of death in industrialised nations.^{1,2} The classical diagnostic tools for detecting prostate cancer are prostate specific antigen (PSA), digital rectal examination (DRE) and trans-rectal ultrasound (TRUS)-guided biopsy. Imaging has a pivotal part in prostate cancer treatment selection and planning.³ In the recent years, magnetic resonance imaging (MRI) has taken up a greater role in the diagnostic algorithm of prostate cancer.

MRI equipment and technical considerations

Compared with the conventional MRI using phased- array

coil, combining the endo-rectal coil provides state-of-the-art imaging for staging prostate cancer with excellent signal quality and improved spatial resolution.^{3,4} Higher magnetic fields at 3-Tesla provides a twofold increase in signal-to-noise ratio (SNR), shorter overall scan time and increase in spatial, temporal and spectroscopic resolution with better structural and functional detail compared to low field strength (e.g. 1.5 T) MRI.⁵

Multi-parametric (mp) MRI

Multi-parametric MRI (mp-MRI) includes combination of high-resolution T2-weighted images assessing the anatomy and at least two functional MRI techniques, i.e. diffusion weighted imaging (DWI) and magnetic

Table: Different components of multi-parametric (mp) MRI.

Modality	Principle	Clinical utility
T2 weighted images	Fast spin echo sequence with long repetition time and long echo time	Primary sequence of visualization of structures in and out of the gland. Best depiction of prostate zonal anatomy (Detection, localization and staging of prostate cancer). Cancer is low in signal. Sensitive but not specific for prostate cancer.
Diffusion weighted images	Brownian motion of water molecules in tissues	Detection of prostate cancer foci. Rapid cell turnover with reduced extracellular space. Low signal intensity on ADC (apparent diffusion coefficient) maps. Discriminatory power to distinguish b/w high vs. low Gleason grade disease. Adds specificity and lesion characterization.
Dynamic Contrast enhanced	Micro-vascular properties of tumour angiogenesis	Uses T1W sequences. Differentiates carcinomatous foci from BPH nodules. Expressed by enhancement pattern i.e. early enhancement and early washout. Adds sensitivity for cancer detection.
MR spectroscopy	Biochemical and metabolic status of tissues. Cell membrane turnover	Detect malignancy in peripheral zone. Increased choline/ citrate ratio. Adds specificity and lesion characterization.

MRI: Magnetic resonance imaging

T1W: T1-weighted

BPH: Benign prostatic hyperplasia.

.....
The Aga Khan University Hospital, Karachi Pakistan.

Correspondence: Syed Muhammad Nazim. Email: muhammad.nazim@aku.edu

resonance spectroscopic imaging (MRSI), adding specificity and lesion characterisation.⁶ Perfusion-based dynamic contrast-enhanced MRI (DCE-MRI) has high sensitivity in cancer detection⁶ (Table). De Rooij M. et al. in a meta-analysis found mp-MRI to have high specificity, negative predictive value (NPV) and sensitivity for detecting prostate cancer.⁷

Morphological / Anatomical information

The detection of prostate cancer depends upon the type of image sequence used. Higher resolution T2-weighted (T2W) MRI imaging offers best information about prostatic capsule and zonal anatomy, hence used for detection, localisation and staging of prostate cancer⁷ (Figure-1).

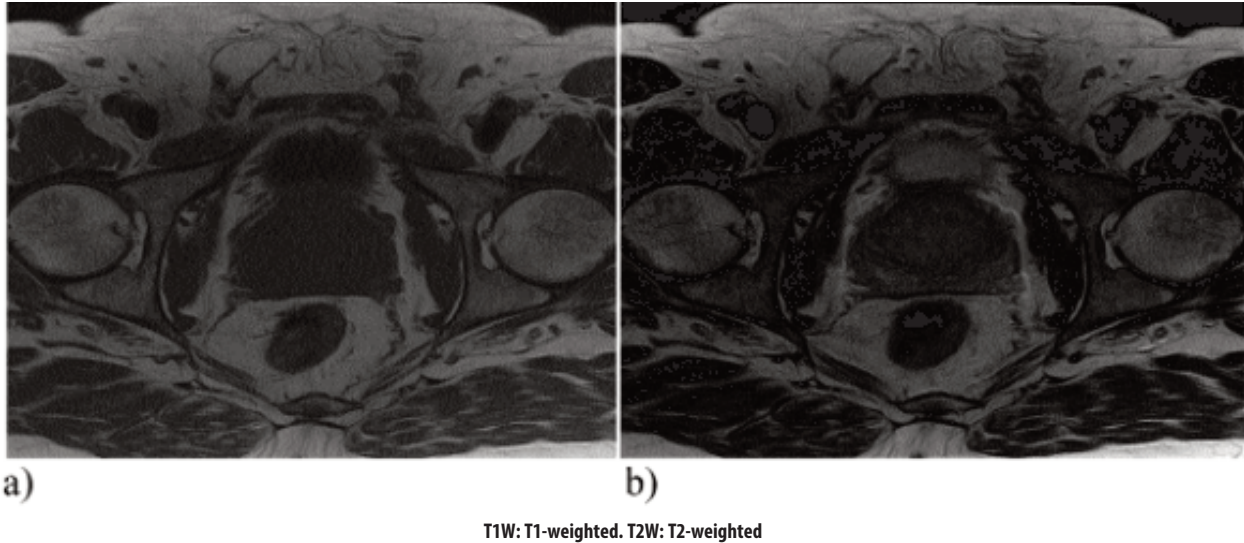


Figure-1: Normal Prostate; a) T1W image-prostate gland is iso-intense to the surrounding muscles. b) T2W image- Prostate gland is slightly hyper-intense to the surrounding muscles especially the peripheral zone.

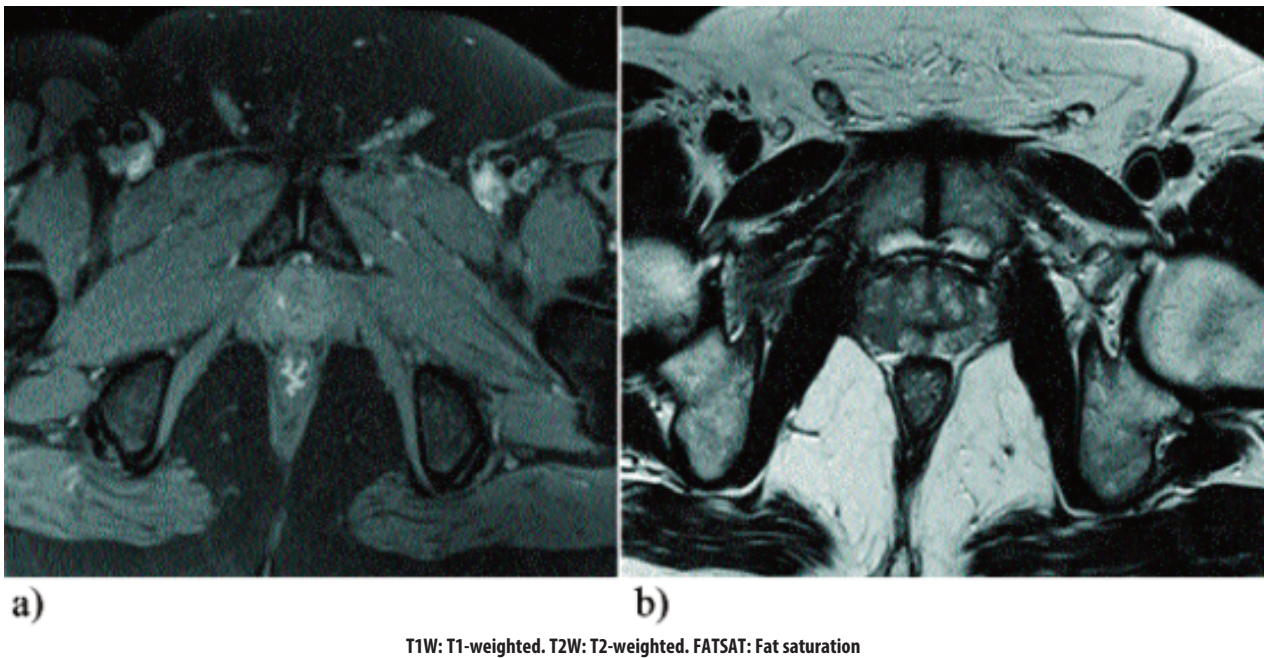
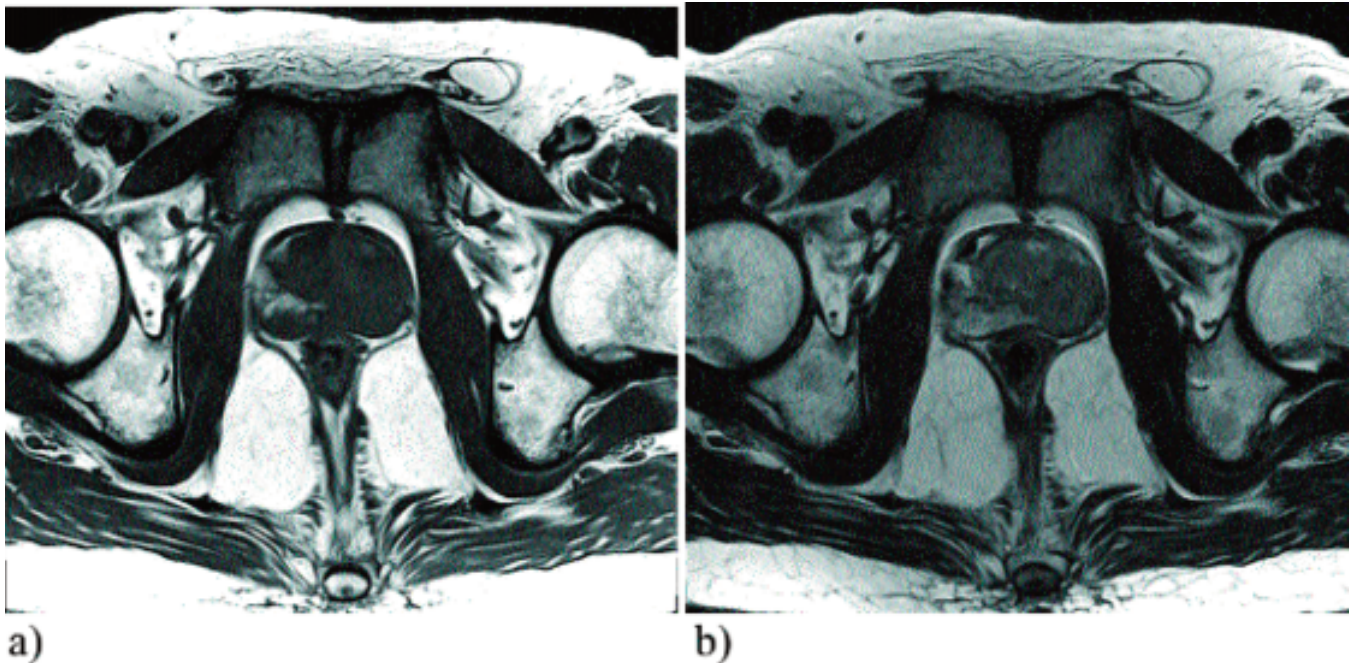
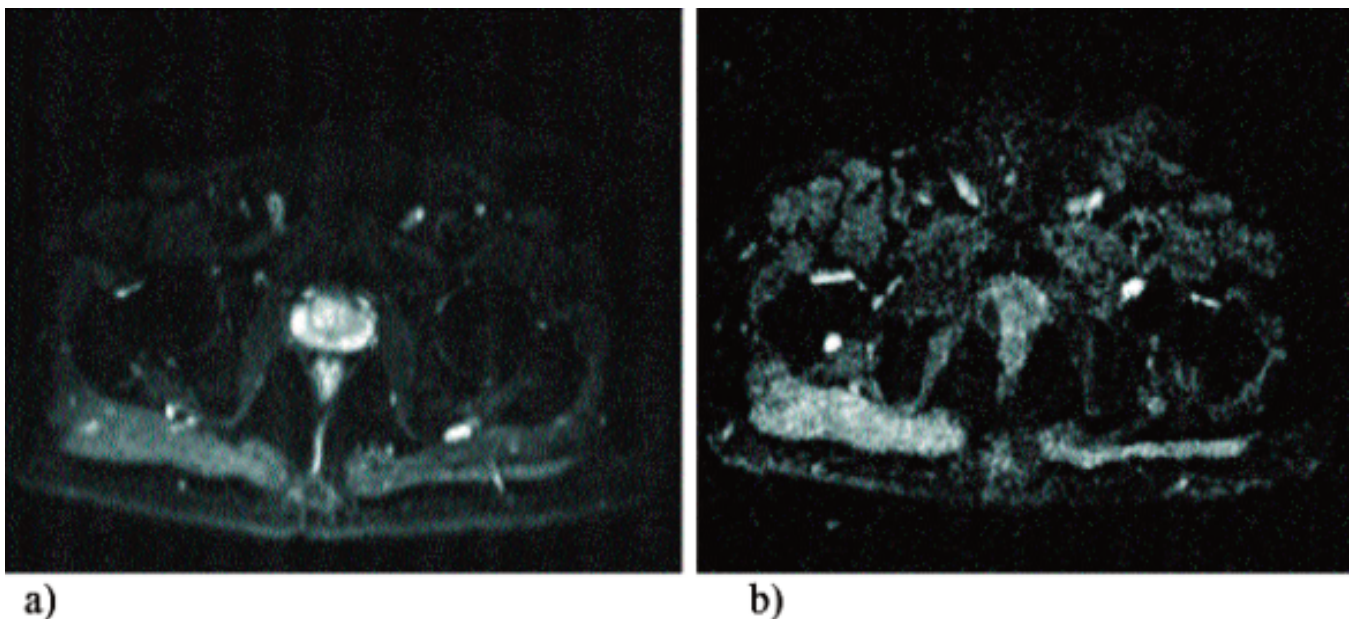


Figure-2: Tumour nodule. a) FATSAT -T1W image shows an iso-intense nodule at the right lateral zone of the prostate gland which is difficult to differentiate from the normal prostate gland due to similar signal intensity, but appears as an asymmetrical bulge. b) T2W image; re-demonstration of an iso-intense nodule in the right lateral aspect of the prostate gland. This is relatively hyper-intense to the surrounding muscles but is still hypo-intense to the peripheral zone.



T1W: T1-weighted. T2W: T2-weighted

Figure-3: a) T1W image of the prostate shows a nodule occupying the left half of the prostate gland. As this is iso-intense to the prostate gland, therefore, difficult to appreciate on T1W images. A tiny hyper-intense focus at the right lateral aspect of the prostate represents hemorrhage due to recent biopsy. b) T2W image show the nodule in left lateral aspect of the prostate gland which is slightly hyper-intense to the surrounding muscles but is still hypo-intense to the normal prostate gland.



MR: Magnetic resonance.

Figure-4: a) Diffusion weighted image (DWI) show a hyper intense focus corresponding to the nodule seen in the right lateral zone of prostate gland. (1.5 Tesla MR images). b) Apparent diffusion coefficient (ADC) map show a corresponding low intensity focus in the right lateral zone of prostate gland. The hyper-intense signal on DWI and corresponding hypo-intensity on ADC map represent diffusion restriction. (1.5 Tesla MR images).

The classical MR appearance of prostate cancer is a round or ill defined, low signal intensity focus (hypo-intense) in the background of bright peripheral zone tissue. This is due to loss of normal glandular (ductal) morphology in prostate cancer⁶ (Figure-2).

On T1-weighted images, the tumour is almost impossible to detect because of homogenous medium signal intensity with difficulty discerning the zonal anatomy.^{4,8} This sequence, however, is useful to detect the post biopsy haemorrhage, which appears as areas of high T1 signal intensity due to paramagnetic, iron-rich, blood by products⁹ within the otherwise homogeneous prostate. Blood has low signal intensity on T2-weighted images, and can either mimic cancer and/or lead to an inaccurate estimate of its volume⁴ (Figure-3).

Extra capsular extension (ECE) / Seminal Vesicle (SV) involvement

The criteria for extra-capsular extension include asymmetry, bulge of prostate contour, thickening of neuro-vascular bundle(s), capsular enhancement and breach, tumour signal in peri-prostatic fat and obliteration of recto-prostatic angle.^{4,10,11} On T2WI, these findings provide a specificity of more than 90%.

The SVs are seen as elongated fluid-filled structures with thin septae with low signal intensity on T1-weighted (T1W) images and high signal intensity on T2W images.¹² Combination of tumour at prostate base extending beyond the capsule and low signal intensity within SV in the background of high signal fluid on T2-weighted images are highly predictive of SV invasion.¹³

The reported sensitivity of MRI scan for the detection of extra capsular extension is 13-95% with specificity ranging from 49-97%.¹⁴⁻¹⁶

Diffusion-weighted imaging (DWI)

Diffusion-weighted MRI uses principle of Brownian motion of water molecules in tissues.^{17,18} It has advantage of short acquisition time, improved specificity and no requirement for any specialised hardware.¹⁹

The rate of diffusion of water in soft tissues is lower than in free solution and is described by the apparent diffusion coefficient (ADC), which correlates inversely with tissue cellularity.²⁰ Increased cellularity and loss of ductal morphology result in restriction of water diffusion in prostate cancer with corresponding low signal intensity in ADC Values.²⁰

ADC maps can be calculated on DWI thus enabling

qualitative and quantitative assessment of the aggressiveness of prostate cancer.⁶ The ADC values for malignant tissue are commonly lower than those of normal gland as well as benign prostatic hyperplasia (BPH) nodules²¹⁻²³ (Figure-4).

Limitations

DWI has low spatial resolution and hence lower accuracy in the assessment of extra-capsular extension.²⁴ Benign conditions such as prostatitis, compact fibro muscular stroma seen in BPH²⁵ and organ motion²⁶ can also lower the ADC and hence give false positive results. Well-differentiated tumours with predominantly glandular components can lead to false negative results.²⁷

Dynamic contrast-enhanced MRI (DCE)

This imaging sequence relies on tumour neo-angiogenesis.⁴ Administration of gadolinium-based contrast is done for enhancing tumour vascularity.³ Early nodular enhancement before the rest of prostate and early washout of signal intensity is characteristic of prostate cancer.³

The data generated by DCE MRI is assessed in 3 ways, i.e. qualitatively, semi-quantitatively and quantitatively. The former way is applied in routine clinical practice.^{4,28} Intensity-time curves are generated to evaluate time to peak, maximum uptake slope, peak enhancement and washout rates. The quantitative approach uses more sophisticated pharmacokinetic parameters to describe tissue vascularisation such as mean transit time, blood flow and permeability surface area.^{4,29} Jackson et al.³⁰ showed that the sensitivity and specificity of DCE-MRI (50% and 85%, respectively) is higher than that of T2W imaging (21% and 81%, respectively).

Limitations

The limiting factors in DCE-MRI are motion and biopsy artefacts. The rectal motion and patient movements may lead to noisy curves and distorted low quality images, therefore, bowel preparation with enema and anti-peristaltic agents are recommended to overcome these pitfalls.³¹

MR Spectroscopy Imaging (MRSI)

MRSI depicts the metabolic profile of the prostatic tissue.⁴ Neoplastic proliferation leads to increased phospholipid cell membrane turnover with resultant difference in concentration of chemical metabolites.³ This study enables to show lower levels of citrate (marker of benign tissue) and higher levels of choline (marker of malignant tissue) from volumes of interest

(voxels) that encompass prostate cancer.⁴

MRSI not only detects cancer but also provides information about the lesion aggressiveness (Gleason scoring).³² This approach can be used to evaluate the "metabolic atrophy" after treatment and for the detection of recurrence after radiation therapy.³³ A sensitivity and specificity as high as 95% and 91%, respectively, has been reported for MRSI in conjunction with endo-rectal MRI.³⁴

Limitations

The interpretation of MRSI is challenging. The spatial resolution is poor and therefore this study is unable to depict the peri-prostatic area and accurate staging information.³⁵ It needs additional software for interpreting the data adding to time and cost.³⁶

MRI-guided prostate biopsy

Contrary to standard set of TRUS-guided prostate biopsies, MRI-guided prostate biopsy targets only area(s) considered to be suspicious, hence resulting in improved accuracy in prostate cancer detection and localisation, especially for the lesions that are not routinely targeted on TRUS-guided biopsies such as anterior tumours.^{37,38} MRI scan also helps in localising the site of tumour recurrence after definitive treatment.³⁹

Role of MRI in planning surgery and follow-up (surveillance and recurrence)

A safe and effective operation can be guided by information from MRI imaging leading to oncological clearance while preserving the peri-prostatic tissues important for recovery of urinary and sexual function.³ MRI also helps to predict the intra-operative blood loss. A positive correlation was observed b/w prominence of apical peri-prostatic veins and associated blood loss.⁴⁰

Moreover, mpMRI can also predict functional outcome after surgery. The length of membranous urethra on coronal endo-rectal MR image is an important predictor for urinary incontinence.⁴¹ Patients with longer than average (14mm) membranous urethra experience more rapid return to complete continence.

MpMRI is helpful in patients with biochemical recurrence (rising PSA value) without any palpable tumour in prostatic fossa. The sensitivity and specificity of endo-rectal MRI to evaluate local recurrence (peri-anastomotic and retro-vesical region) after prostatectomy was reported to be 91% and 45%.⁴²

MRI-guided focal therapies

Cryoablation and high-intensity focused ultrasound (HIFU) are the two contemporary treatment modalities used as focal therapy. MR-guided targeted focal and regional therapies are increasingly used for localised primary (native) and recurrent prostate cancer as well as for monitoring the effectiveness of these treatments.⁴³ Recently, pre-clinical and phase 1 trials have also reported real-time MR-guided focal laser ablation (FLA).⁴⁴

Reporting and communication of mp-MRI data (prostate imaging reporting and data system (PI-RADS) classification)

European Society of Urogenital Radiology (ESUR) prostate MR guidelines of 2012 recommend structured reporting system for mp-MRI data, including the following set of information:⁶

- A) PI-RADS score (probability of cancer risk and its aggression)
- B) Location and probability of extra-prostatic disease
- C) Pertinent incidental findings.

Individual lesion(s) should be given a PI-RADS score on a five-point scale from 1-5, with a score of "1" denoting that clinically significant disease was highly unlikely to be present and a score of "5" denoting that clinically significant disease was highly likely to be present.⁴⁵ Grey A.D. et al.⁴⁶ found PI-RADS system to be a very good predictor for trans-perineal prostate biopsy outcome.

Conclusion

Mp-MRI is a rapidly evolving and useful tool for the diagnosis, localisation and staging of prostate cancer and to facilitate the targeted therapies. It has the potential for reduction of unnecessary biopsies and provides a rapid and accurate diagnosis for both native and recurrent tumours. It should become an integral part of prostate cancer risk assessment.

Disclaimer: None.

Conflict of Interest: None.

Source of Funding: None.

References

1. Siegel R, Ma J, Zou Z, Jemal A. Cancer statistics, 2014. *CA Cancer J Clin* 2014; 64: 9-29.
2. Ferlay J, Shin HR, Bray F, Forman D, Mathers C, Parkin DM. Estimates of worldwide burden of cancer in 2008: GLOBOCAN 2008. *Int J Cancer* 2010; 127: 2893-917.

3. Hricak H, Choyke PL, Eberhardt SC, Leibel SA, Scardino PT. Imaging prostate cancer: a multi-disciplinary perspective. *Radiology* 2007; 243: 28-53.
4. Costouros NG, Coakley FV, Westphalen AC, Qayyum A, Yeh BM, Joe BN, et al. Diagnosis of prostate cancer in patients with an elevated prostate-specific antigen level: role of endorectal MRI and MR spectroscopic imaging. *Am J Roentgenol* 2007; 188: 812-6.
5. Ullrich T, Quentin M, Oelers C, Dietzel F, Sawicki LM, Arsov C, et al. Magnetic resonance imaging of the prostate at 1.5 versus 3.0T: A prospective comparison study of image quality. *Eur J Radiol*. 2017 ; 90 :192-197.
6. Barentsz JO, Richenberg J, Clements R, Choyke P, Verma S, Villeirs G, et al; European Society of Urogenital Radiology. ESUR prostate MR guidelines 2012. *Eur Radiol* 2012; 22: 746-57.
7. de Rooij M, Hamoen EH, Fütterer JJ, Barentsz JO, Rovers MM. Accuracy of multiparametric MRI for prostate cancer detection: a meta-analysis. *Am J Roentgenol* 2014; 202: 343-51.
8. Bouchelouche K, Turkbey B, Choyke PL. Advances in imaging modalities in prostate cancer. *Curr Opin Oncol*. 2015 ; 27 : 224-31.
9. Sharif-Afshar AR, Feng T, Koopman S, Nguyen C, Li Q, Shkolyar E, et al. Impact of post prostate biopsy hemorrhage on multiparametric magnetic resonance imaging. *Can J Urol*. 2015 ; 22 :7698-702.
10. Somford DM, Hamoen EH, Fütterer JJ, van Basten JP, Hulsbergen-van de Kaa CA, Vreuls W, et al. The predictive value of endorectal 3 Tesla multiparametric magnetic resonance imaging for extraprostatic extension in patients with low, intermediate and high risk prostate cancer. *J Urol*. 2013 ;190 : 1728-34.
11. Outwater EK, Petersen RO, Siegelman ES, Gomella LG, Chernesky CE, Mitchell DG. Prostate carcinoma: assessment of diagnostic criteria for capsular penetration on endorectal coil MR images. *Radiology* 1994; 193: 333-9.
12. Hedgire SS, Oei TN, McDermott S, Cao K, Patel M Z, Harisinghani MG. Multiparametric magnetic resonance imaging of prostate cancer. *Indian J Radiol Imaging* 2012; 22: 160-9.
13. Soyulu FN, Peng Y, Jiang Y, Wang S, Schmid-Tannwald C, Sethi I, et al. Seminal vesicle invasion in prostate cancer: evaluation by using multiparametric endorectal MR imaging. *Radiology*. 2013 ; 267 :797-806.
14. Krishna S, Lim CS, McInnes MD, Flood TA, Shabana WM, Lim RS, et al. Evaluation of MRI for diagnosis of extraprostatic extension in prostate cancer. *J Magn Reson Imaging*. 2017 Apr 7. doi: 10.1002/jmri.25729.
15. de Cobelli O, Terracciano D, Tagliabue E, Raimondi S, Bottero D, Cioffi A, et al. Predicting Pathological Features at Radical Prostatectomy in Patients with Prostate Cancer Eligible for Active Surveillance by Multiparametric Magnetic Resonance Imaging. *PLoS One*. 2015;10:e0139696.
16. Hara T, Nakanishi H, Nakagawa T, Komiyama M, Kawahara T, Manabe T, et al. Ability of preoperative 3.0-Tesla magnetic resonance imaging to predict the absence of side-specific extracapsular extension of prostate cancer. *Int J Urol*. 2013 ; 20 :993-9.
17. Maurer MH, Härmä KH, Thoeny H. Diffusion-Weighted Genitourinary Imaging. *Radiol Clin North Am*. 2017 ; 55 :393-411.
18. Mazaheri Y, Vargas HA, Akin O, Goldman DA, Hricak H. Reducing the influence of b-value selection on diffusion-weighted imaging of the prostate: evaluation of a revised mono exponential model within a clinical setting. *J Magn Reson Imaging* 2012; 35: 660-8.
19. Miao H, Fukatsu H, Ishigaki T. Prostate cancer detection with 3-T MRI: comparison of diffusion-weighted and T2-weighted imaging. *Eur J Radiol* 2007; 61: 297-302.
20. Zelhof B, Lowry M, Rodrigues G, Kraus S, Turnbull L. Description of magnetic resonance imaging-derived enhancement variables in pathologically confirmed prostate cancer and normal peripheral zone regions. *BJU Int* 2009; 104: 621-7.
21. Sato C, Naganawa S, Nakamura T, Kumada H, Miura S, Takizawa O, et al. Differentiation of noncancerous tissue and cancer lesions by apparent diffusion coefficient values in transition and peripheral zones of the prostate. *J Magn Reson Imaging* 2005; 21: 258-62.
22. Simpkin CJ, Morgan VA, Giles SL, Riches SF, Parker C, deSouza NM. Relationship between T2 relaxation and apparent diffusion coefficient in malignant and non-malignant prostate regions and the effect of peripheral zone fractional volume. *Br J Radiol*. 2013; 86 :20120469.
23. Ren J, Huan Y, Li F, Wang H, Ge Y, Chang Y, et al. Combined T2-weighted and diffusion-weighted MRI for diagnosis of urinary bladder invasion in patients with prostate carcinoma. *J Magn Reson Imaging* 2009; 30: 351-6.
24. Kim W, Kim CK, Park JJ, Kim M, Kim JH. Evaluation of extracapsular extension in prostate cancer using qualitative and quantitative multiparametric MRI. *J Magn Reson Imaging*. 2017 ; 45 :1760-70.
25. Xu J, Humphrey PA, Kibel AS, Snyder AZ, Narra VR, Ackerman JJ, et al. Magnetic resonance diffusion characteristics of histologically defined prostate cancer in humans. *Magn Reson Med* 2009; 61: 842-50.
26. Lim HK, Kim JK, Kim KA, Cho KS. Prostate cancer: apparent diffusion coefficient map with T2-weighted images for detection--a multireader study. *Radiology* 2009; 250: 145-51.
27. Woo S, Cho JY, Kim SY, Kim SH. Extracapsular extension in prostate cancer: added value of diffusion-weighted MRI in patients with equivocal findings on T2-weighted imaging. *AJR Am J Roentgenol*. 2015 ; 204 :W168-75.
28. Engelbrecht MR, Huisman HJ, Laheij RJ, Jager GJ, van Leenders GJ, Hulsbergen-Van De Kaa CA, et al. Discrimination of prostate cancer from normal peripheral zone and central gland tissue by using dynamic contrast-enhanced MR imaging. *Radiology* 2003; 229: 248-54.
29. Li X, Cai Y, Moloney B, Chen Y, Huang W, Woods M, et al. Relative sensitivities of DCE-MRI pharmacokinetic parameters to arterial input function (AIF) scaling. *J Magn Reson*. 2016 ; 269 :104-12.
30. Jackson AS, Reinsberg SA, Sohaib SA, Charles-Edwards EM, Jhavar S, Christmas TJ, et al. Dynamic contrast-enhanced MRI for prostate cancer localization. *Br J Radiol* 2009; 82: 148-56.
31. McMahon CJ, Bloch BN, Lenkinski RE, Rofsky NM. Dynamic contrast-enhanced MR imaging in the evaluation of patients with prostate cancer. *Magn Reson Imaging Clin N Am* 2009; 17: 363-83.
32. Kobus T, van der Laak JA, Maas MC, Hambroek T, Bruggink CC, Hulsbergen-van de Kaa CA, et al. Contribution of Histopathologic Tissue Composition to Quantitative MR Spectroscopy and Diffusion-weighted Imaging of the Prostate. *Radiology*. 2016 ; 278: 801-11.
33. Panebianco V, Barchetti F, Musio D, Forte V, Pace A, De Felice F, et al. Metabolic atrophy and 3-T 1H-magnetic resonance spectroscopy correlation after radiation therapy for prostate cancer. *BJU Int*. 2014 ;114 :852-9.
34. Jagannathan D, Indiran V. Accuracy of Diffusion Weighted Images and MR Spectroscopy in Prostate Lesions - Our Experience with Endorectal Coil on 1.5 T MRI. *J Clin Diagn Res*. 2017 ; 11 :TC10-TC14.
35. Mazaheri Y, Shukla-Dave A, Hricak H, Fine SW, Zhang J, Inurrigarro G, et al. Prostate cancer: identification with

- combined diffusion-weighted MR imaging and 3D 1H MR spectroscopic imaging--correlation with pathologic findings. *Radiology* 2008; 246: 480-8.
36. Choi YJ, Kim JK, Kim N, Kim KW, Choi EK, Cho KS. Functional MR imaging of prostate cancer. *Radiographics* 2007; 27: 63-75.
 37. Yacoub JH, Verma S, Moulton JS, Eggener S, Aytakin O. Imaging-guided prostate biopsy: conventional and emerging techniques. *Radiographics* 2012; 32: 819-37.
 38. Fütterer JJ, Barentsz JO. MRI-guided and robotic-assisted prostate biopsy. *Curr Opin Urol.* 2012; 22: 316-9.
 39. Kitajima K, Murphy RC, Nathan MA, Froemming AT, Hagen CE, Takahashi N, et al. Detection of recurrent prostate cancer after radical prostatectomy: comparison of 11C-choline PET/CT with pelvic multiparametric MR imaging with endorectal coil. *J Nucl Med.* 2014 ; 55 :223-32.
 40. Coakley FV, Eberhardt S, Wei DC, Wasserman ES, Heinze SB, Scardino PT, et al. Blood loss during radical retropubic prostatectomy: relationship to morphologic features on preoperative endorectal magnetic resonance imaging. *Urology* 2002; 59: 884-8.
 41. Coakley FV, Eberhardt S, Kattan MW, Wei DC, Scardino PT, Hricak H. Urinary continence after radical retropubic prostatectomy: relationship with membranous urethral length on preoperative endorectal magnetic resonance imaging. *J Urol* 2002; 168: 1032-5.
 42. Linder BJ, Kawashima A, Woodrum DA, Tollefson MK, Karnes J, Davis BJ, et al. Early localization of recurrent prostate cancer after prostatectomy by endorectal coil magnetic resonance imaging. *Can J Urol* 2014; 21: 7283-9.
 43. Woodrum DA, Kawashima A, Gorny KR, Mynderse LA. Magnetic Resonance-Guided Thermal Therapy for Localized and Recurrent Prostate Cancer. *Magn Reson Imaging Clin N Am* 2015; 23: 607-19.
 44. Natarajan S, Raman S, Priester AM, Garritano J, Margolis DJ, Lieu P, et al. Focal Laser Ablation of Prostate Cancer: Phase I Clinical Trial. *J Urol* 2016; 196: 68-75.
 45. Bomers JG, Barentsz JO. Standardization of multiparametric prostate MR imaging using PI-RADS. *Biomed Res Int* 2014; Article ID 431680.
 46. Grey AD, Chana MS, Popert R, Wolfe K, Liyanage SH, Acher PL. Diagnostic accuracy of magnetic resonance imaging (MRI) prostate imaging reporting and data system (PI-RADS) scoring in a transperineal prostate biopsy setting. *BJU Int* 2015; 115: 728-35.
-