



THE AGA KHAN UNIVERSITY

eCommons@AKU

Section of Orthopaedic Surgery

Department of Surgery

2-1-2020

Comparison of intraarticular distal humerus fracture outcomes treated with or without olecranon osteotomy - A case series

Naveed Baloch

Aga Khan University, naveed.baloch@aku.edu

Tashfeen Ahmad

Aga Khan University, tashfeen.ahmad@aku.edu

Zehra Abdul Muhammad

Aga Khan University, zehra.abdul@aku.edu

Follow this and additional works at: https://ecommons.aku.edu/pakistan_fhs_mc_surg_orthop



Part of the [Orthopedics Commons](#), [Surgery Commons](#), and the [Trauma Commons](#)

Recommended Citation

Baloch, N., Ahmad, T., Muhammad, Z. A. (2020). Comparison of intraarticular distal humerus fracture outcomes treated with or without olecranon osteotomy - A case series. *JPMA. The Journal of the Pakistan Medical Association*, 70(2(Suppl 1)), S102-S105.

Available at: https://ecommons.aku.edu/pakistan_fhs_mc_surg_orthop/141

Comparison of intraarticular distal humerus fracture outcomes treated with or without olecranon osteotomy — A case series

Naveed Baloch,¹ Tashfeen Ahmad,² Zehra Abdul Muhammad³

Abstract

A case series was extracted from the trauma registry at Aga Khan University Hospital from the period June 2015 to June 2019. Included were 16 adult patients who presented with intra-articular distal humerus fracture type C2. The functional, clinical and radiological outcomes of fractures treated with or without olecranon osteotomy up to 12 months follow-up were compared. Outcomes were assessed at 6 weeks, 3, 6 and 12 months re-visits. Among the 16 studied patients, 9 (56%) were males and 7 (44%) were females. In the group without osteotomy, there was a good functional and clinical outcome with a mean Quick Disability of the Arm, Shoulder and Hand score of 32±30 at 3 months post-procedure. Bone healing was noticed at 6 months after surgery. In the osteotomy group, 50%-70% bone union was seen at 3 months post-surgery while fair functional and clinical outcome was achieved at 6 months after surgery.

Keywords: Intraarticular fractures, Distal humerus, Trauma, Outcomes, Range of motion.

Introduction

Elbow fractures account for 7% of all adult fractures of which 30% are distal humerus fractures.^{1,2} Restoring complete functional and clinical recovery is very difficult in distal humerus intra-articular fractures. According to previously published research, there is 25% fixation failure rate in intra-articular distal humerus fractures particularly in the elderly population.³ There are generally two operative techniques to treat distal humerus intra-articular fractures. One approach is with olecranon osteotomy.⁴ Second is without olecranon osteotomy.⁵

Previously published research showed complex C2 and C3 type of distal humerus fractures (AO classification) treated with osteotomy has high rate of union.^{6,7} It has been observed that intra-articular distal humerus fractures operated with triceps splitting approach without osteotomy have better clinical and functional

outcomes.⁸ Thus, according to available literature, it is recommended to perform olecranon osteotomy in complex intra-articular distal humerus fractures while for non-complex fractures, better outcomes can be achieved without osteotomy.⁹

Current study aims to assess and compare the clinical, functional and radiological outcomes of intra-articular distal humerus type C2 fractures treated either with or without olecranon osteotomy till 12 months post-surgery.

Case Series

After all Institutional and ethical approvals, trauma registry commenced from June 2015 at Aga Khan University in which data of all eligible consented patients, irrespective of age and gender, presenting with upper and lower limb fracture/dislocation secondary to trauma was captured. Patients with pathological fractures with no trauma injury or patients undergoing amputation were excluded. A descriptive case series was obtained from our trauma registry. Between June 2015 to June 2019, and a total of 37 patients with distal humerus fractures were screened. Sixteen adult (≥ 18 years) patients with intra-articular distal humerus type C2 fractures were included for analysis for the present analysis (Table-1).

Patients were divided into two groups with 9 patients in group treated without olecranon osteotomy and 7 patients in group treated with olecranon osteotomy. After written informed consent, data was obtained from patient's medical record and both the groups were compared for their functional, clinical and radiological outcomes. Outcome were assessed at 2 weeks±5 days, 6±2 weeks, 3 months±2 weeks, 6±1months and 12±2 months follow-ups post-procedure. Functional outcomes were recorded using Quick Disability of the Arm, Shoulder and Hand Outcome (QuickDASH) Measure. Scores of 0-24 were graded as good, 25-49 as fair, 50-74 as poor and 75-100 as severe disability.¹⁰ Clinical outcomes including elbow range of motion (ROM) evaluated in degrees using goniometer, ability to lift weight and perform heavy household tasks were recorded. Radiological fracture union were assessed by orthopaedic surgeon at 3, 6 and 12 months follow-ups. Duration of cast application was

^{1,3}Departments of Surgery, ²Departments of Surgery and Biological & Biomedical Sciences, Aga Khan University, Karachi, Pakistan.

Correspondence: Tashfeen Ahmad. Email:tashfeen.ahmad@aku.edu

Table-1: Patients characteristics and with outcomes at follow-ups in both groups - Cases 1-16.

Without osteotomy	Age	Gender	Injury	Admission (DD-MM-YY)	6 weeks (DD-MM-YY)	6 weeks OC	3 months (DD-MM-YY)	3 months OC	6 months (DD-MM-YY)	6 months OC	12 months (DD-MM-YY)	12 months OC
Case 1	70	Female	Fall	18-05-16	28-06-16	Severe disability	6/8/2016	Bone 50% united	15-11-16	N/A	-	-
Case 2	52	Male	RTA	19-07-16	-	-	5/10/2016	Bone 50% united	-	-	-	-
Case 3	36	Male	RTA	5/9/2016	17-10-16	Poor	5/12/2016	Good	27-02-17	Good, bone 50% united	1/11/2017	Good, bone 100% united
Case 4	36	Male	Fall	5/12/2016	24-01-17	Fair	23-02-17	Good, bone 50% united	1/6/2017	Good	-	-
Case 5	36	Male	RTA	20-03-17	19-04-17	Poor	5/7/2017	Good	20-09-17	Good, bone 70% united	6/1/2018	Bone 100% united
Case 6	38	Male	RTA	1/4/2017	2/5/2017	Poor	-	-	19-10-17	Good, bone 100% united	-	-
Case 7	50	Male	RTA	24-04-18	20-06-18	Poor	-	-	-	-	-	-
Case 8	75	Female	Fall	22-01-19	12/3/2019	Severe disability	23-04-19	Severe disability, no bone healing	25.06.19	Fair, no bone healing	-	-
Case 9	45	Female	RTA	28-02-19	-	-	-	-	-	-	-	-
With osteotomy	Age	Gender	Injury	Admission (DD-MM-YY)	6 weeks (DD-MM-YY)	6 weeks OC	3 months (DD-MM-YY)	3 months OC	6 months (DD-MM-YY)	6 months OC	12 months (DD-MM-YY)	12 months OC
Case 1	50	Female	Fall	25-09-16	18-11-16	Poor	27-01-17	Poor, bone 70% united	-	-	-	-
Case 2	80	Female	Fall	27-11-16	31-12-16	N/A	-	-	-	-	-	-
Case 3	33	Male	RTA	13-03-17	17-04-17	Poor	-	-	-	-	-	-
Case 4	58	Male	RTA	19-12-17	25-01-18	Poor	1/3/2018	Poor, bone 50% united	24-05-18	Fair, bone 90% united	-	-
Case 5	24	Female	Fall	24-12-18	21-02-19	Poor	4/4/2019	Fair, bone 70% united	-	-	-	-
Case 6	40	Male	RTA	14-01-19	11/2/2019	Poor	11/3/2019	Bone 50% united	-	-	-	-
Case 7	77	Female	Fall	12/3/2019	-	-	18-05-19	Bone 50% united	-	-	-	-

RTA = road traffic accident, N/A = patient arrived but outcome not available, OC = outcome.

also recorded as one of the restricting factor that influenced the outcome.

Data was analyzed on Statistical Package for the Social Sciences (SPSS) version 19.0. Continuous variables were expressed as mean \pm standard deviation (SD) and categorical variables as percentages (%). Fisher's exact test was applied for comparisons of categories good-fair and poor-severe disability. The p-value of less than 0.05 was considered as statistically significant with a confidence interval of 95%.

Results

Among all selected patients, 9(56%) were males and 7 (44%) were females. Mechanism of injury was road traffic

accident (N=9, 56%) or fall (N=7, 44%). All patients were treated with Open Reduction and Internal Fixation (ORIF). In olecranon osteotomy group, median age was 50 years and interquartile range 44 years while in without olecranon osteotomy group, median age was 45 years and interquartile range 25 years.

Functional, clinical and radiological outcomes were assessed post-surgery at follow-ups (Figure-1, Tables-2). At 6 weeks follow-up, clinical and functional outcomes were assessed in 5 patients treated with olecranon osteotomy all of which achieved poor outcome (N=5, 100%) with a mean ROM of 53 ± 21 . In without osteotomy group, clinical and functional outcomes were assessed in 7 patients. One (14%) out of 7 patients achieved fair outcome. The rest of

Table-2: QuickDASH scores, elbow ROM and radiological bone healing at follow-ups - osteotomy versus without osteotomy.

QuickDASH outcomes scores							
	Without osteotomy group				Osteotomy group		
	6 weeks	3 months	6 months	12 months	6 weeks	3 months	6 months
Mean±SD	64±18	32±30	17±16	6	64±7	52±22	29
Minimum	32	11	0	6	54	27	-
Maximum	82	77	43	6	73	70	-

Group	Percentage of radiological bone healing		
	3 months	6 months	12 months
Osteotomy	50% united (N=3) 70% united (N=2)	90% united (N=1)	-
Without osteotomy	50% united (N=3) Not united (N=1)	50% united (N=1) 70-100% united (N=2) Not united (N=1)	100% united (N=2)

Groups	Elbow joint range of motion			
	6 weeks	3 months	6 months	12 months
Without osteotomy Mean±SD	54°±26°	75°±48°	103°±22°	130°
Osteotomy Mean±SD	53°±21°	65°±13°	95°	-

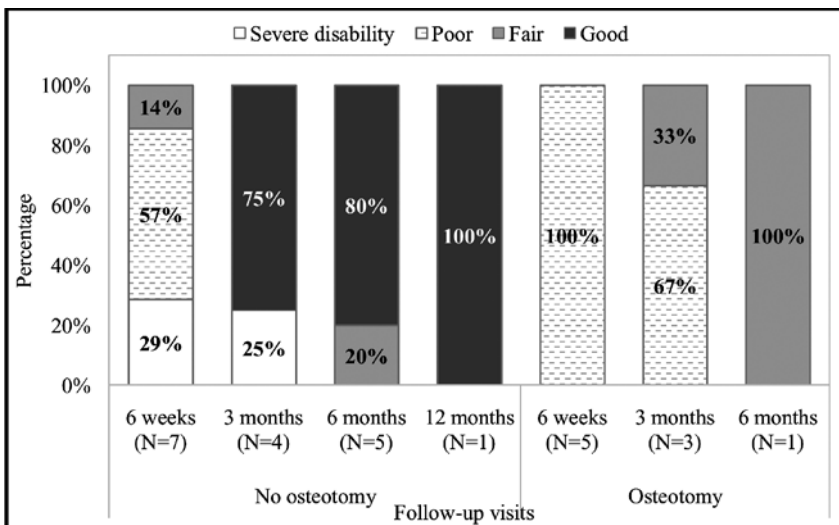


Figure: Percentage of QuickDASH outcomes - osteotomy versus without osteotomy.

6 had either poor outcome (N=4, 57%) or severe disability (N=2, 28%). Mean score of ROM was 54°±26°.

At 3 months, clinical and functional outcomes of 3 patients were assessed in the osteotomy group, 1 (33%) patient was with fair and 2(67%) with poor outcome. Mean value of ROM was 65°±13°. X-ray reports were available for 5 patients in whom radiological outcomes showed 50% (2 cortex) bone union in 3 (60%) patients and 70% (3 cortex) union in 2 (40%) patients. Clinical and functional outcomes of 4 patients were assessed in without osteotomy group.

Three (75%) patients achieved good results and 1 (25%) had severe disability. Mean value of ROM was 75°±48°. At this follow-up, patients in without osteotomy group were able to perform routine daily activities with lifting weight around 2-3 Kg easily except for 1 (25%) patient having a cast. Radiological outcomes showed no bony union in 1 (25%) and 50% union in 3 (75%) patients.

At 6 months follow-up, outcome of one patient was assessed in the osteotomy group who had a fair outcome (100%). Mean value for SD ROM was 95° with 90% (almost 4 cortex) bone union. In without osteotomy group, 5 patients were assessed for clinical and functional outcome of whom 4(80%) achieved good and 1(20%) achieved fair outcome. There was near full

ROM with mean of 103°±22°. X-ray reports were available for 4 patients in whom radiological outcomes showed 2 (50%) patients with 70-100% (3 to 4 cortex) union, 1 (25%) patient had 50% (2 cortex) union and 1 (25%) had delayed union. In without osteotomy group, all followed patients were able to perform heavy household tasks and were able to lift around 5 Kg weight except for 1 who could lift around 1 Kg weight by that time. In osteotomy group, patient was unable to perform heavy household tasks and lift weight up to 1-2 Kg with difficulty.

At 12 months, clinical and functional outcome was assessed in 1 patient in without osteotomy group who achieved good (100%) outcome with 130° ROM. X-ray reports were available for 2 patients in whom radiological outcomes showed 100% (4 cortex) bone union. In osteotomy group, 4 patients were lost to follow-up and for 3 patients follow-up is still due. There was non-significant difference in functional, clinical and radiological outcomes in both the groups at follow-ups.

Duration of cast application was minimum 2 weeks and maximum 13 weeks in without osteotomy group while minimum 3 weeks and maximum 8 weeks in osteotomy group. Mean duration of cast application was 6±3 weeks in without osteotomy group and 6±2 weeks in osteotomy group.

After surgery, no deaths were recorded up to 12 months follow-up and no in-hospital complication observed. At 2 weeks follow-up, 2 (12.5%) patients had superficial wound infection that resolved completely by 6 weeks follow-up.

Discussion

Our current study compared outcomes of distal humerus intra-articular fractures treated either with olecranon osteotomy or without olecranon osteotomy in C2 type of fractures. There was no need for any corrective surgery or hardware removal in both groups. Early functional and clinical recovery was identified in without olecranon osteotomy group with better outcome including ability to perform daily tasks and lift weight at 3 months follow-up as compared to olecranon osteotomy group. On the other hand, olecranon osteotomy treated group showed delayed functional and clinical recovery at more than 6 months. Interestingly, range of motion was almost same in both groups.

Early bone healing was predominantly in olecranon osteotomy group at 3 months post-procedure. At 6 months, healing was almost similar in both groups except for one patient in without olecranon osteotomy group. At 12 months, complete bone union was achieved in without osteotomy group.

Mean duration of cast application was nearly same in both groups. There was no death or in-hospital complication in both groups of patients suggesting meticulous care was provided while performing ORIF.

Conclusion

Based on current evidence, ORIF without olecranon

osteotomy proved to be an effective technique in resuming rapid recovery with good functional and clinical outcomes. Simultaneously, in olecranon osteotomy group, bone healing started early. Although bone healing was better in with olecranon osteotomy group, it seems that the procedure interfered in normal functional and clinical capacity to perform routine work easily. As the number of subjects was small in the current series with low statistical power, there is need for further research on larger sample size to draw more definite conclusion.

Disclaimer: None.

Conflict of Interest: There is no conflict of interest to declare.

Source of Funding: The study was supported by the Aga Khan University Hospital, Department of Surgery from May 2015 to February 2019. From March 2019, Project No. AOTME-R-2016-010 was supported by AO Foundation, Switzerland.

References

1. Anglen J. Distal humerus fractures. *J Am Acad Orthop Surg* 2005;13:291-7.
2. Shaikh RB, Reddy VP, Naidu AK. Study of clinical outcome in intra articular distal humerus fractures treated with dual plating. *Int J Res Med Sci* 2017;5:2438-41.
3. Frankle MA, Herscovici D Jr, DiPasquale TG, Vasey MB, Sanders RW. A comparison of open reduction and internal fixation and primary total elbow arthroplasty in the treatment of intraarticular distal humerus fractures in women older than age 65. *J Orthop Trauma* 2003;17:473-80.
4. Jupiter JB, Neff U, Holzach P, Allgower M. Intercondylar fractures of the humerus. An operative approach. *J Bone Joint Surg Am* 1985;67:226-39.
5. Fernández-Valencia J, Muñoz-Mahamud E, Ballesteros J, Prat S. Treatment of AO type C fractures of the distal part of the humerus through the bryan-morrey triceps-sparing approach. *ISRN Orthop* 2013;2013:e525326. doi: 10.1155/2013/525326.
6. Sarukte V, Shingade K, Bhanushali R. A study of thirty cases of comparison of T-Y fractures humerus fixation with and without olecranon osteotomy. *Int J Contemp Med Res* 2017;4:390-2.
7. Asfuroğlu ZM, İnan U, Ömeroğlu H. Open reduction and internal fixation in AO type C distal humeral fractures using olecranon osteotomy: Functional and clinical results. *Ulus Travma Acil Cerrahi Derg* 2018;24:162-7. doi: 10.5505/tjtes.2017.32916.
8. Samanta D, Dasgupta S, Ghosh A, Naiya S, Sarkar A. Short term evaluation of intra articular fracture fixation of distal humerus in adults without olecranon osteotomy (triceps splitting approach). *Ann Int Med Den Res* 2017;3:18-23.
9. Crean TE, Nallamothe SV. Distal Humerus Fractures. [Online] 2019 [Cited 2019 January 19]. Available from URL: <https://www.ncbi.nlm.nih.gov/books/NBK531474/>
10. Beaton DE, Wright JG, Katz JN. Development of the QuickDASH: comparison of three item-reduction approaches. *J Bone Joint Surg Am* 2005;87:1038-46.