



THE AGA KHAN UNIVERSITY

eCommons@AKU

Section of Orthopaedic Surgery

Department of Surgery

7-2013

Giant cell tumour of the sacrum: Function-preserving surgery with extended curettage and ilio-lumbar fusion

Riaz Hussain Lakhdawala

Tashfeen Ahmad

Ather Enam

Follow this and additional works at: https://ecommons.aku.edu/pakistan_fhs_mc_surg_orthop



Part of the [Neurology Commons](#), [Neurosurgery Commons](#), [Oncology Commons](#), [Orthopedics Commons](#), and the [Surgery Commons](#)

CASE REPORT

GIANT CELL TUMOUR OF THE SACRUM: FUNCTION-PRESERVING SURGERY WITH EXTENDED CURETTAGE AND ILIO-LUMBAR FUSION

Riaz H. Lakdawala, Tashfeen Ahmad, Syed A. Enam,*

Departments of Surgery and Biological and Biomedical Sciences, Aga Khan University, Karachi, Pakistan

Giant cell tumours of the sacrum pose a unique therapeutic challenge due to the inaccessibility of the tumour, significant intra-operative blood loss from extensive vascularity, high rate of local recurrence with conservative surgery, and loss of neurological function and mechanical instability with en-bloc excision. We present a case where successful outcome was achieved by tailoring treatment in consideration of the above issues. A 28 year old male diagnosed on biopsy to have giant cell tumour of the sacrum presented to us with low-back pain, left-sided S1 radiculopathy, ankle weakness and urinary incontinence. MRI showed a tumour involving the S1 and S2 vertebral segments, breaching the posterior cortex and compressing the neural elements. An angiographic tumour embolization was performed followed by surgery through a posterior approach whereby an extended curettage was done, carefully freeing the sacral nerve roots and abrading the bone using high-speed burr. An ilio-sacro-lumbar fusion was done employing ilio-lumbar instrumentation and bone grafting. Post-operatively, within a week the patient was ambulated with a lumbar corset. At 9 months follow-up, the patient was completely pain free, had no ankle weakness, and had normal continence. This treatment approach resulted in preservation of neurologic function and maintenance of spinal stability, thus the patient returned to full function.

Keyword: Giant cell tumour of bone; sacrum; selective arterial embolization; extended curettage; ilio-lumbar fusion; segmental instrumentation.

J Ayub Med Coll Abbottabad 2013;25(3):94-7

INTRODUCTION

Sacrum is the fourth most common site affected by giant cell tumour of bone and carries a 23% mortality rate.¹ There is no consensus regarding optimal management. Conventionally, giant cell tumours are treated surgically by curettage and bone grafting, but such intralesional excision results in 47% recurrence rate. Adjuvants such as electrocautery, phenol and bone cement are therefore used to reduce the risk of recurrence, but in the spine they pose a risk of injury to the neural elements. Moreover, difficulty in surgical treatment of giant cell tumours involving the sacrum also stem from the inaccessibility of the tumour, significant intra-operative blood loss due to extensive vascularity and post-operative mechanical lumbo-sacro-pelvic instability. Thus, sacral giant cells tumours pose a unique therapeutic challenge and necessitate a modified management approach to preserve neurological and mechanical function. We present a case of giant cell tumour of the sacrum where successful outcome was achieved by tailoring treatment in consideration of these concepts.

CASE

The patient was a 28 year old male who was initially evaluated outside our hospital for symptoms of left-sided S1 radiculopathy. An MRI was done (Figure-1) which showed a tumour involving the S1 and S2

vertebral segments, breaching the posterior cortex and compressing the neural elements (Campanacci stage III).² He underwent a left-S1 laminectomy and open biopsy in an outside hospital; the biopsy was reported as giant cell tumour. The patient continued to have pain and also developed urinary and bowel incontinence and ankle weakness, with which he presented to us. Examination revealed restricted straight leg raising test (R) 40°, (L) 30°, reduced sensation along S1, absent ankle jerks, absent perianal sensation and lax anal sphincter. CT scan showed tumour extending into the neural canal posteriorly from S1 and S2 sacral segments, and the previous left S1 laminectomy (Figure-2). MRI scan demonstrated local progression of the tumour as compared to the initial scan (Figure-3), approaching the sacro-iliac and lumbo-sacral joints.

A preoperative angiography was performed, showing a tumour blush with feeding arteries coming from branches of the internal iliac arteries on both sides. Angiographic embolization of these tumour vessels was performed, with complete disappearance of the tumour blush (Figure-4). Subsequently, surgery was done through a posterior approach whereby an extended curettage was done. Blunt and sharp dissection was done to free the sacral nerve roots from the tumour, while the bone was abraded using high-speed burr. In order to prevent pistoning of the lumbar spine into the weakened sacrum, an ilio-lumbar instrumentation using

a construct of pedicle screws in the L4 and L5 vertebrae as well as both iliac crests, attached to contoured rods interconnected with a cross-link (Figure-5). Fibular and iliac bone grafting was done. Post-operatively, within a week the patient was ambulated with a lumbar corset. At 9 months follow-up, the patient was completely pain free, had no weakness of ankle plantar flexion (Figure-6), and had normal bladder and bowel continence.

DISCUSSION

Although locally advanced giant cell tumours of the sacrum pose a difficult surgical challenge, our case illustrates a practical approach which has proven successful in eliminating the disease while preserving mechanical and neurological functions. In spinal tumours, non-operative treatment in the form of radiotherapy can be used as solitary treatment for inaccessible lesions, but there is up to 49% recurrence rate and a risk of late malignant transformation. There have been some recent developments in this modality, such as “megavoltage radiotherapy”. This entails administration of 30–70 gray over 5–7 weeks as the solitary treatment, and has been reported to give 85% non-progression of tumour at 10 years.³ Angio-embolization has also been used as a solitary procedure, but is fraught with a 30% recurrence rate at 10 years and 43% at 20 years.^{4,5} However, when used pre-operatively, it significantly reduces intra-operative bleeding and reduces surgical difficulty. Thus,

surgical excision remains the mainstay of treatment of sacral giant cell tumours.^{6,7} Intra lesional curettage has been the gold standard for non-spinal lesions, but in the spine it is known to result in a high rate of local recurrence. The risk of local recurrence can only be eliminated by *en bloc* excision of the involved bone. However, *en bloc* excision is not the optimal treatment method in regions such as the sacrum because important neural elements lie within the bone. Moreover, if the neural canal is encroached upon by the tumour, during curettage it is not possible to use adjuvants because they would injure the nerves. Injury to S1 nerve roots results in loss of ankle plantar-flexion power required for normal gait, and injury to S2 nerve roots results in loss of bladder and bowel sphincter control. Thus, the use of intra-operative magnification and micro-dissection technique around the neural elements, and use of high speed burr and electrocautery in the margins help to reduce the residual tumour cells. *En bloc* excision as well as extensive intralesional curettage result in mechanical instability for which lumbo-sacro-pelvic reconstruction is recommended.⁸ In consideration of the above factors, we treated our patient with preoperative angio-embolization followed by surgery which entailed curettage and careful dissection to free the neural elements and use of high-speed burr on the margins of resection, and reconstruction with lumbo-sacro-pelvic instrumented fusion.

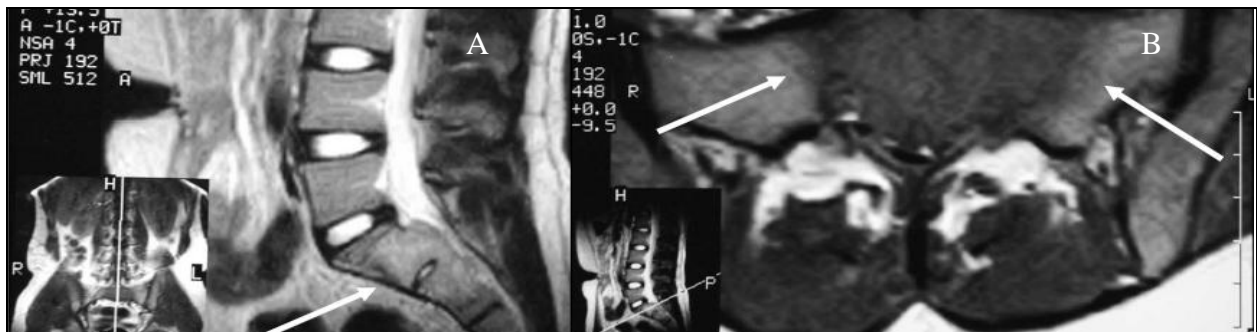


Figure-1: (A, B). Sagittal T-2 (A) and axial T-1 (B) weighted images from initial MRI scan showing expansile tumour (arrows) involving sacral segments S1 and S2 and bulging into the neural canal

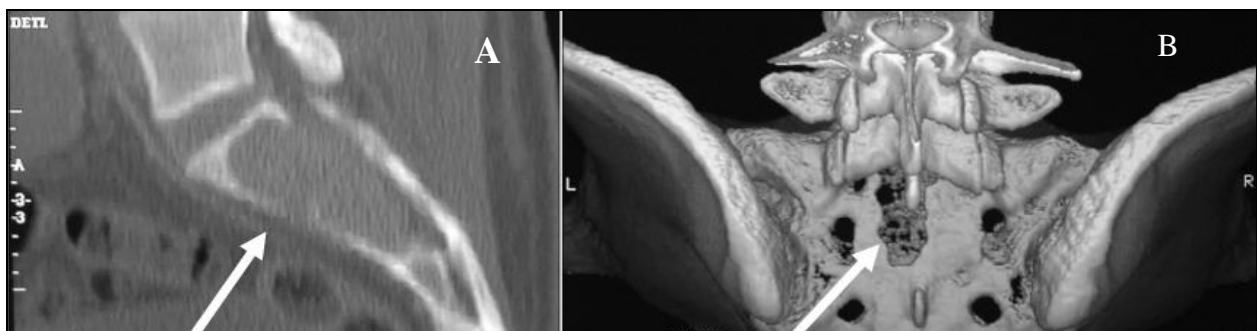

Figure-2: (A,B). CT scan images showing (A) Campanacci III lesion extending into the neural canal posteriorly from sacral segments S1 and S2 (arrow). 3-D reconstruction of sacrum viewed from behind (B) demonstrating previous left S1 laminectomy (arrow)

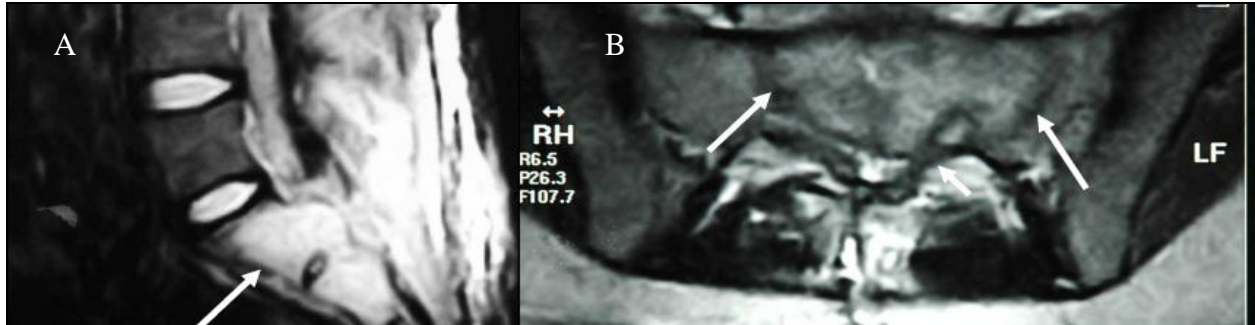


Figure-3: (A, B) Images from MRI scan performed post-S1 laminectomy, sagittal (A) and axial (B) views, demonstrating tumour extension into the neural canal (arrows) adjacent S1 and S2 segment

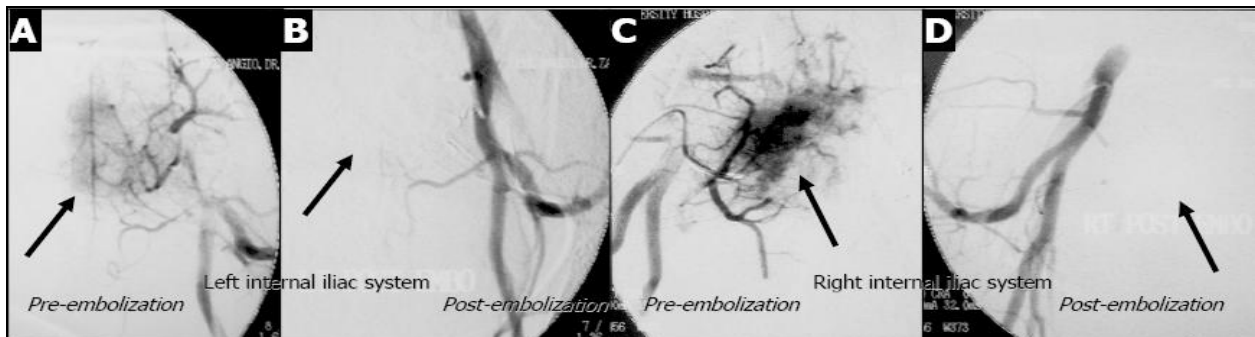


Figure-4: (A-D) Angiographic tumour embolization of lateral sacral arteries. (A, C) Pre-embolization images showing tumour blush (arrows) arising from branches from the left (A) and right (C) lateral sacral arteries. (B, D) Post-embolization images demonstrating disappearance of tumour blush (arrows)

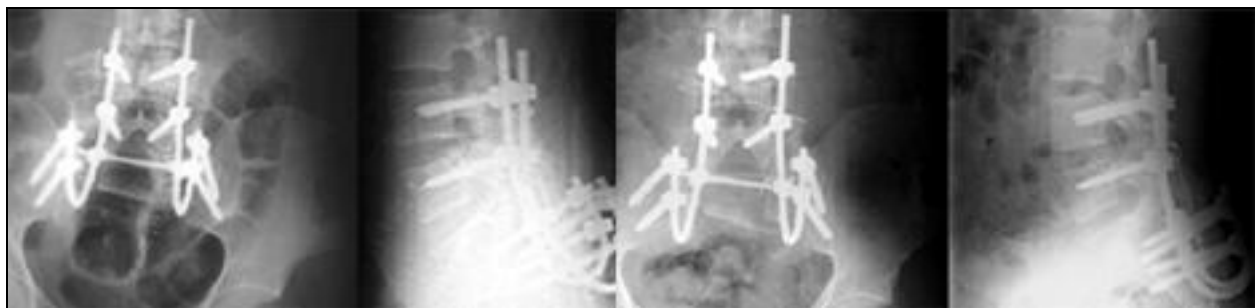

Figure-5: (A,B): (A) Per-operative AP and lateral X-rays showing iliolumbar instrumentation and bone grafting. (B) Follow-up X-rays performed nine months after surgery showing satisfactory fusion

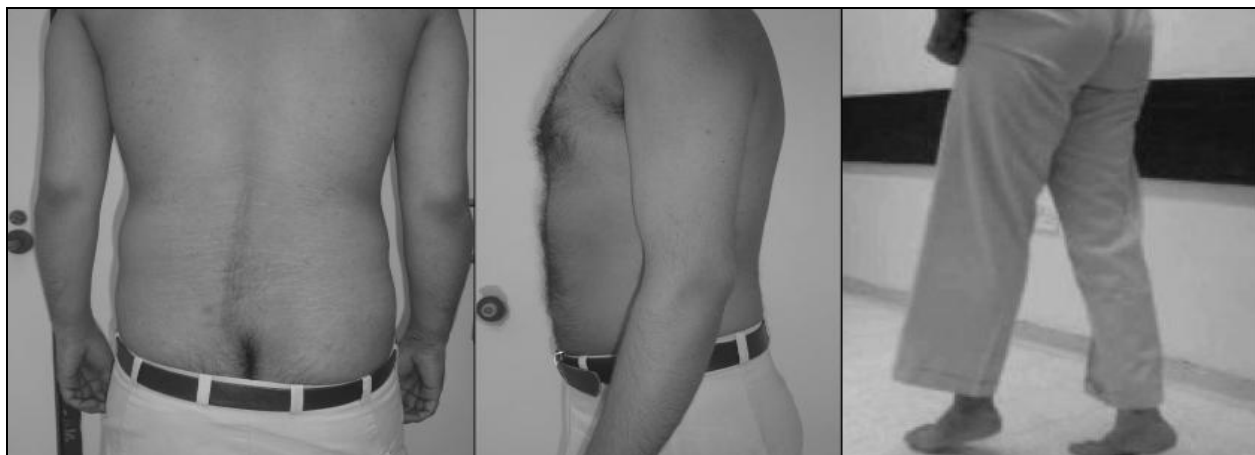

Figure-6: Clinical pictures showing preservation of lumbo-sacral contour and intact S1 function (toe-walk)

CONCLUSION

The treatment method employed in our patient resulted in preservation of neurologic function and maintenance of lumbo-sacro-pelvic stability, thus the patient became symptom-free and returned to full function. A multi-modal therapeutic approach is warranted in the management of giant cell tumours of the sacrum.

REFERENCES

1. Leggon RE, Zlotecki R, Reith J, Scarborough MT. Giant cell tumour of the pelvis and sacrum: 17 cases and analysis of the literature. *Clin Orthop Relat Res* 2004; 423:196–207.
2. Campanacci M, Baldini N, Boriani S, Sudanese A. Giant-cell tumour of bone. *J Bone Joint Surg* 1987;69:106–14.
3. Chakravarti A, Spiro IJ, Hug EB, Mankin HJ, Efid JT, Suit HD. Megavoltage radiation therapy for axial and inoperable giant-cell tumour of bone. *J Bone Joint Surg Am* 1999;81:1566–73.
4. Lackman RD, Khoury LD, Esmail A, Donthineni-Rao R. The treatment of sacral giant-cell tumours by serial arterial embolisation. *J Bone Joint Surg Br* 2002;84:873–7.
5. Lin PP, Guzel VB, Moura MF, Wallace S, Benjamin RS, Weber KL, *et al.* Long-term follow-up of patients with giant cell tumour of the sacrum treated with selective arterial embolization. *Cancer* 2002;95:1317–25.
6. Randall RL. Giant cell tumour of the sacrum. *Neurosurg Focus* 2003;15:E13.
7. Zhen W, Yaotian H, Songjian L, Ge L, Qingliang W. Giant-cell tumour of bone. The long-term results of treatment by curettage and bone graft. *J Bone Joint Surg Br* 2004;86:212–6.
8. Mindea SA, Salehi SA, Ganju A, Rosner MK, O'Shaughnessy BA, Jorge A, *et al.* Lumbosacropelvic junction reconstruction resulting in early ambulation for patients with lumbosacral neoplasms or osteomyelitis. *Neurosurg Focus* 2003;15(2):E6.

Address for Correspondence:

Dr. Riaz Hussain Lakdawala, Department of Surgery, Aga Khan University, PO. Box 3500, Stadium Road Karachi 74800, Pakistan. **Tel:** +92 21 4864350

Email: riaz.lakdawala@aku.edu