



THE AGA KHAN UNIVERSITY

eCommons@AKU

---

Section of Neurosurgery

Department of Surgery

---

December 2000

# Foreign body granuloma after craniotomy for tumor: a diagnostic dilemma

A.A. Razzaq

M.K. Chishti

Follow this and additional works at: [https://ecommons.aku.edu/pakistan\\_fhs\\_mc\\_surg\\_neurosurg](https://ecommons.aku.edu/pakistan_fhs_mc_surg_neurosurg)



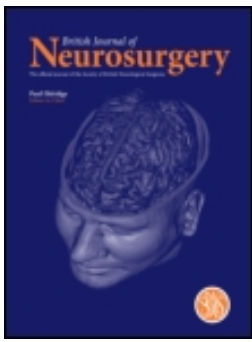
Part of the [Surgery Commons](#)

---

## Recommended Citation

Razzaq, A. A., Chishti, M. K. (2000). Foreign body granuloma after craniotomy for tumor: a diagnostic dilemma. *British Journal of Neurosurgery*, 14(6), 591-592.

**Available at:** [https://ecommons.aku.edu/pakistan\\_fhs\\_mc\\_surg\\_neurosurg/130](https://ecommons.aku.edu/pakistan_fhs_mc_surg_neurosurg/130)



## Foreign body granuloma after craniotomy for tumor: a diagnostic dilemma

A. A. Razzaq, M. K. N. Chishti

To cite this article: A. A. Razzaq, M. K. N. Chishti (2000) Foreign body granuloma after craniotomy for tumor: a diagnostic dilemma, *British Journal of Neurosurgery*, 14:6, 591-592, DOI: [10.1080/02688690020005617](https://doi.org/10.1080/02688690020005617)

To link to this article: <https://doi.org/10.1080/02688690020005617>



Published online: 06 Jul 2009.



Submit your article to this journal [↗](#)



Article views: 12



Citing articles: 3 [View citing articles](#) [↗](#)

NEUROLOGICAL IMAGE

## Foreign body granuloma after craniotomy for tumor: a diagnostic dilemma

A. A. RAZZAQ & M. K. N. CHISHTI

Department of Surgery, Division of Neurological Surgery, Aga Khan University Hospital, Karachi, Pakistan

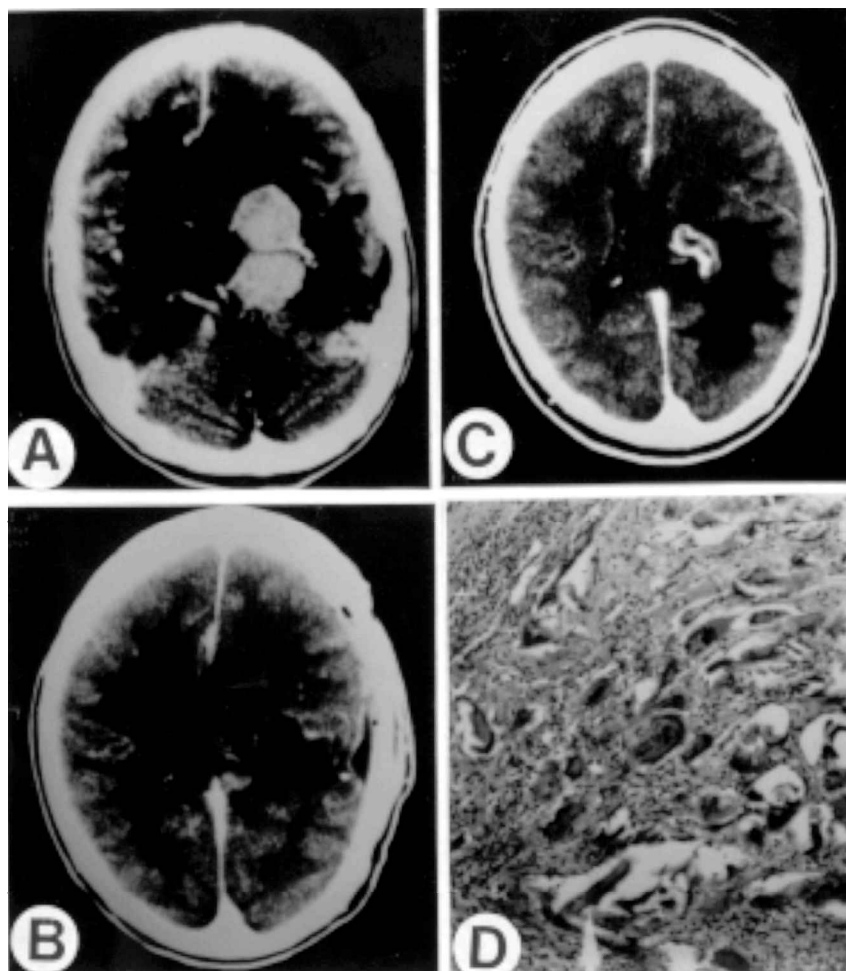


FIG. 1. (A upper left) Contrast-enhanced preoperative CT scan showing intensely enhancing lesion centred on the left lateral ventricle. (B lower left) Contrast-enhanced postoperative CT scan showing no evidence of residual tumour. (C upper right) Contrast-enhanced CT scan 40 days after initial operation showing ring enhancing lesion near the site of previous tumour resection (D, lower right) Histology of the lesion showing foreign body reaction with giant cells (H & E).

An unusual case of foreign body reaction after resection of tumour is described. A 45-year-old woman presented with a complaint of generalized headache of 2 years duration. Neurological examination showed bilateral papilloedema and a right hemiparesis.

Contrast CT showed an enhancing, deep seated left hemispheric mass, centred on the left lateral ventricle (Fig. 1A). The patient underwent a left parietal craniotomy. The tumour was found completely embedded in the brain substance. It was about 8 mm

from the brain surface, was firm in consistency and was removed completely. No dural or ventricular attachment was visible at operation. The pathology was benign transitional meningioma. Postoperatively, CT showed no evidence of residual tumour (Fig. 1B). Nearly three months after operation the patient presented with high grade fever and generalized tonic-clonic seizures. CT showed an enhancing 2×3 cm lesion deep in the left hemisphere (Fig. 1C). The diagnostic possibilities of recurrent tumour and abscess were considered, and it was decided to re-operate. In the depths of the previous corticotomy, an irregular, grayish brown mass was encountered, pressing on the medial side of the temporal horn. It resembled tumour on gross appearance and was resected with some difficulty, owing to adhesions with the surrounding tissue. The histology revealed chronic granulomatous inflammation with giant cells containing birefringent material which were cotton fibres (Fig. 1D). Postoperatively, the patient's condition improved gradually and seizures were controlled.

The differential diagnosis of an enhancing mass after craniotomy for tumour includes recurrent or

residual tumour, abscess and radiation necrosis.<sup>1</sup> This report emphasizes the importance of adding foreign body granuloma to this list and to avoid using cotton balls in deep cavities.<sup>2-5</sup> Early recognition of this entity may prevent major morbidity resulting from this condition.

## References

- 1 Shimosaka S, Waga S. Foreign body granuloma simulating recurrence of falx meningioma. *J Neurosurg* 1983;59:1085-7.
- 2 Haisa T, Matsumiya K, *et al.* Foreign body granuloma as a complication of wrapping and coating an intracranial aneurysm. *J Neurosurg* 1990;72:292-4.
- 3 Chambi I, Tasker RR, Gentili F, *et al.* Gauze-induced granuloma (gauzoma): an uncommon complication of gauze reinforcement of berry aneurysms. *J Neurosurg* 1990; 72: 163-70.
- 4 Epstein AJ, Russell EJ, Berlin L, *et al.* Suture granuloma: an unusual cause of an enhancing ring lesion in the post-operative brain. *J Comput Assist Tomogr* 1982;6:815-17.
- 5 Korosue K, Tamaki N, Matsumoto S, *et al.* Intracranial granuloma as an unusual complication of subdural-peritoneal shunt. Case report. *J Neurosurg* 1981;55:136-8.