



THE AGA KHAN UNIVERSITY

eCommons@AKU

---

Section of Dental-Oral Maxillofacial Surgery

Department of Surgery

---

10-2019

## **Evaluation of the change in the tongue posture and in the hyoid bone position after twin block appliance therapy in skeletal class II subjects**

Erum Afzal

Mubassar Fida

Follow this and additional works at: [https://ecommons.aku.edu/pakistan\\_fhs\\_mc\\_surg\\_dent\\_oral\\_maxillofac](https://ecommons.aku.edu/pakistan_fhs_mc_surg_dent_oral_maxillofac)

---

# Evaluation of the change in the tongue posture and in the hyoid bone position after Twin Block appliance therapy in skeletal class II subjects

## Ocena zmiany położenia języka oraz kości gnykowej po leczeniu aparatem Twin Block wady szkieletowej II klasy

Erum Afzal<sup>A–D</sup>, Mubassar Fida<sup>A,E,F</sup>

The Aga Khan University Hospital, Karachi, Pakistan

A – research concept and design; B – collection and/or assembly of data; C – data analysis and interpretation; D – writing the article; E – critical revision of the article; F – final approval of the article

Dental and Medical Problems, ISSN 1644-387X (print), ISSN 2300-9020 (online)

*Dent Med Probl.* 2019;56(4):379–384

### Address for correspondence

Mubassar Fida  
mubassar.fida@aku.edu

### Funding sources

None declared

### Conflict of interest

None declared

Received on April 29, 2019

Reviewed on July 10, 2019

Accepted on August 27, 2019

Published online on December 30, 2019

### Abstract

**Background.** The tongue is posteriorly postured in a retrognathic mandible, and Twin Block appliance (TBA) therapy places the tongue and the hyoid bone in a favorable position to eliminate the risk of causing respiratory obstruction.

**Objectives.** The aim of this study was to evaluate the change in the tongue posture and in the hyoid bone position after TBA therapy.

**Material and methods.** This cross-sectional study was conducted using the pre-functional (PF1), post-functional (PF2) and post-treatment (PT) cephalograms of 30 growing subjects. The tongue posture at 6 distances and the hyoid bone position with 4 parameters were digitally measured using the Rogan-Delft View Pro-X<sup>®</sup> software. A digital vernier caliper was used to determine the inter-canine and inter-molar widths on the dental casts. The Wilcoxon signed-rank test was used to compare the PF1 and PF2 values, and the PF1 and PT values.

**Results.** The comparison of the PF1 and PF2 values showed significant differences in the tongue posture at distances 1–5. In the case of the hyoid bone, only the linear distance from the sella (S) to the most anterior point on the hyoid bone (H) – the SH distance – revealed a significant difference ( $p < 0.01$ ). The change in the tongue posture and in the hyoid bone position achieved at the PF2 stage remained stable at the PT stage. Significant differences occurred in the PF1 and PF2 maxillary and mandibular inter-canine and inter-molar widths ( $p = 0.01$  and  $p = 0.04$ , and  $p < 0.01$  and  $p = 0.02$ ), respectively.

**Conclusions.** Twin Block appliance therapy resulted in the advancement of the mandible with a lowered posturing of the tongue. The hyoid bone was displaced inferiorly after TBA therapy, whereas the angular position of the hyoid bone remained unchanged.

**Key words:** malocclusion, functional appliance, hyoid bone, class II

**Słowa kluczowe:** nieprawidłowy zgryz, aparat funkcyjny, kość gnykowa, klasa II

### Cite as

Afzal E, Fida M. Evaluation of the change in the tongue posture and in the hyoid bone position after Twin Block appliance therapy in skeletal class II subjects. *Dent Med Probl.* 2019;56(4):379–384. doi:10.17219/dmp/111976

### DOI

10.17219/dmp/111976

### Copyright

© 2019 by Wrocław Medical University

This is an article distributed under the terms of the

Creative Commons Attribution 3.0 Unported License (CC BY 3.0)

(<https://creativecommons.org/licenses/by/3.0/>)

## Introduction

Skeletal dysplasia between the jaws may affect the facial esthetics, oral function, speech, and social attitude of the patient.<sup>1,2</sup> Craniofacial morphogenesis is a complex interaction between the intrinsic and extrinsic stimuli.<sup>3</sup> In the study conducted by Gul-e-Erum and Fida,<sup>4</sup> 70.5% of orthodontic patients had class II malocclusion with a common diagnostic finding of mandibular retrognathism.<sup>5</sup> It is imperative to diagnose disharmony in the stomatognathic system, reestablish the oral function and improve the overall facial appearance.

The tongue is the most active muscular structure of the oropharyngeal system and is directly influenced by any modification in the dentoskeletal environment.<sup>6</sup> After skeletal discrepancy is corrected, the tongue adapts within the altered position of the dental arches and can enhance post-functional stability if the surrounding forces are in balance.<sup>7,8</sup> The hyoid bone has no bony articulation, and is connected through muscles and ligaments to the pharynx, tongue and mandible. The anteroposterior change in the position of the mandible tends to affect the hyoid bone position, altering its functions of airway maintenance and deglutition.<sup>9</sup> A retrognathic mandible with respect to the cranial base results in a decreased distance between the cervical vertebrae and the mandibular corpus.<sup>5,10</sup> This leads to a posteriorly postured tongue and soft palate, and a reduction in the distance between the hyoid bone and the mandibular plane, which may cause hypopharyngeal obstruction.<sup>11</sup> Mandibular and maxillary retrognathism and the retroposition of the tongue are implicated in causing obstructive sleep apnea (OSA).<sup>12</sup>

Functional appliances are the treatment of choice during the pubertal growth spurt for stimulating the sagittal growth of the mandible.<sup>13</sup> They work on the basis of the viscoelastic principle by stretching muscles to position the mandible forward. The purpose of functional appliance therapy is to achieve maximal skeletal correction and to transform malocclusion into optimally stable occlusion in the neutral zone.<sup>1</sup> A multitude of evidence-based studies have described the Twin Block appliance (TBA) to be efficient in the correction of mandibular deficiency.<sup>14–16</sup> The appliance therapy improves facial esthetics, and results in the functional relocation of the tongue and of the hyoid bone.<sup>17</sup>

Ozdemir et al. reported an increase in the tongue area and in the intermaxillary space after fixed functional appliance therapy, but found no statistically significant change in the hyoid bone position.<sup>18</sup> However, a significant forward movement of the hyoid bone was reported in the study conducted by Bavbek et al.<sup>2</sup>

The tongue is a muscular organ that may be retropositioned in a deficient mandible. With the use of a functional appliance such as TBA, the tongue and hyoid bone posture can be improved, resulting in increased dimensions of the retropalatal and retroglossal airways.<sup>10</sup>

To our knowledge, few studies have reported a change in the tongue posture after functional appliance therapy, and whether the achieved results remain stable after fixed orthodontic treatment. Therefore, the prime objective of the study was to evaluate the change in the tongue posture and in the hyoid bone position after TBA therapy in subjects with a retrognathic mandible.

## Materials and methods

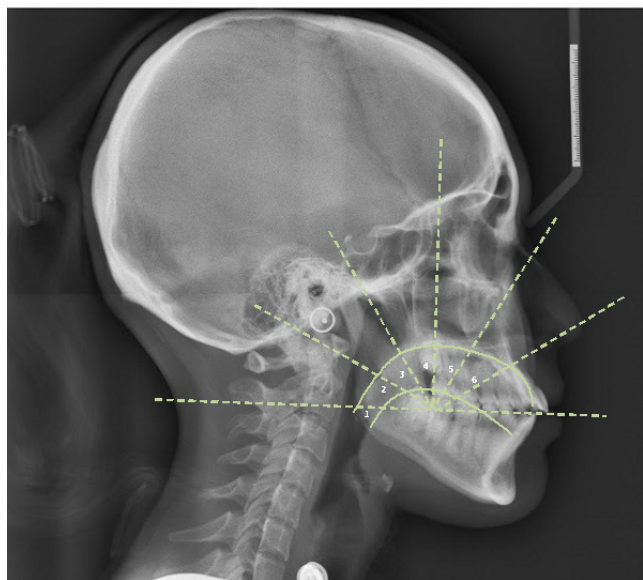
We conducted a cross-sectional study using the pre-functional (PF1), post-functional (PF2) and post-treatment (PT) cephalograms of orthodontic patients visiting our dental clinics. The data was gathered through screening the diagnostic records of patients reporting for orthodontic treatment since 2013 until 2017 after obtaining the approval from the ethical review committee (ERC No. 5430-18). The OpenEpi software ([www.openepi.com](http://www.openepi.com)) was used for the calculation of the sample size, taking into account the findings of Yassaei et al., who reported a statistically significant difference in the hyoid bone position after functional appliance therapy (31.98 ± 3.15 mm and 34.87 ± 4.25 mm in the pre- and post-treatment groups, respectively).<sup>19</sup> Keeping the power of study at the level of 80% and  $p \leq 0.05$ , we needed a total of 27 subjects. We inflated this sample by 10% to include a minimum of 30 subjects in our study. Male and female subjects were equally included to eliminate gender bias.

Subjects of Pakistani origin with skeletal class II malocclusion due to mandibular retrognathism, presented at cervical stage 3 and 4, and having standardized lateral cephalograms with clearly visible tongue and hyoid bone were included in the study. The subjects had the A point-nasion-B point angle (ANB) >4°, an overjet of 6–14 mm and were advised to undergo TBA therapy. Subjects who had the craniofacial syndrome or a systemic disease that might affect growth, or a history of trauma or surgery involving the facial structures as well as those wearing the appliance for less than 20 h were excluded. Patient cooperation and compliance were strictly monitored and documented during every visit.

The interocclusal wax bite registration for the fabrication of TBA was performed by the same clinician for all subjects and the appliances were made in the same laboratory by a trained technician. The therapy lasted for 8–9 months and was followed by fixed orthodontic treatment using a pre-adjusted appliance slot (0.022 × 0.028") in all subjects. The total duration of treatment was on average 30 months.

Lateral cephalograms were taken by trained technicians, with head fixation parallel to the horizontal plane at a film-to-tube distance of 165 cm for the standardization of radiographs. Following the protocol, the subjects were asked to bite in centric occlusion with their lips relaxed during the exposure. An Orthoralix® 9200 apparatus (Gendex-KaVo

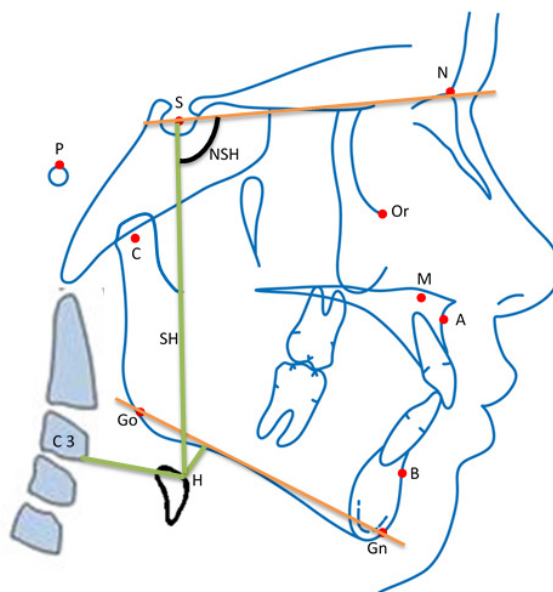
Italia, Milan, Italy) was used. Graber described a method which uses a template to evaluate the tongue posture in relation to the palate.<sup>11</sup> When the template is superimposed on a lateral cephalogram, the horizontal line should extend through the incisal edge of lower central incisor, the cervical third of the last erupted molar in the oral cavity, and its projection on the reference line between lower incisor and the distal point of molar. The contours of the dorsum of the tongue and of the bony palate were measured at 6 different angles. Six distances for each subject were recorded using the Rogan-Delft View Pro-X<sup>®</sup> software (Rogan-Delft BV, Veenendaal, the Netherlands) for precision and accuracy (Fig. 1). Distances 1 and 2 were considered as the posterior portion, distances 3 and 4 as the middle portion, and distances 5 and 6 as the anterior portion of the tongue.



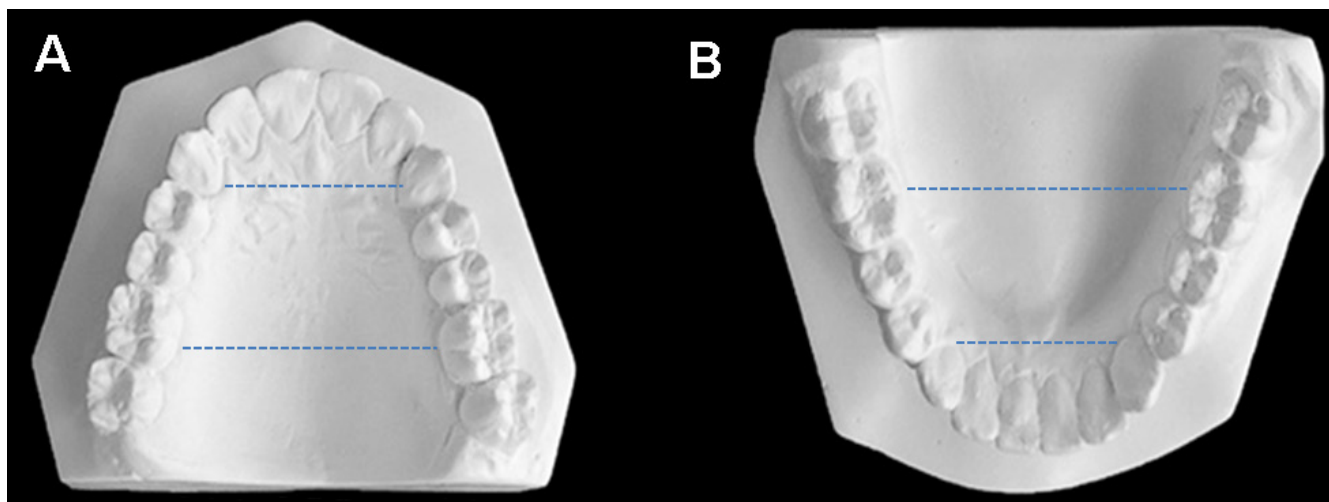
**Fig. 1.** Evaluation of the tongue posture on a lateral cephalogram  
The template was superimposed on a lateral cephalogram, and 6 distances between the dorsum of the tongue (lower green line) and the palatal contour (upper green line) were measured.

The mandibular length was measured from the gonion (Go) to the gnathion (Gn) and from the condyion (Co) to the gnathion (Gn) using the same software.<sup>20</sup> Linear and angular measurements for the hyoid bone position were also taken with the same software using the method described by Baybek et al. (Fig. 2).<sup>2</sup>

Dental casts were taken at the PF1, PF2 and PT stages. The inter-canine and inter-molar widths on the PF1 and PT dental casts were determined using a digital vernier caliper (0–150 mm ME00183; Dentaureum GmbH & Co. KG, Pforzheim, Germany) with an accuracy of 0.02 mm and a reliability of 0.01 mm, according to the manufacturer's specification (Fig. 3).



**Fig. 2.** Assessment of the hyoid bone position on a lateral cephalogram  
SH – vertical distance from the sella (S) to the most anterior point on the hyoid bone (H); C3-H – horizontal distance from H to the most anterior point of C3; NSH – angle between SH and the sella-nasion (SN) plane; H-GoGn – perpendicular distance from H to the mandibular plane (GoGn); Go – gonion; Gn – gnathion.



**Fig. 3.** Orthodontic cast analysis  
A – inter-canine and inter-molar widths of the maxillary cast; B – inter-canine and inter-molar widths of the mandibular cast.

The IBM SPSS Statistics for Windows, v. 21.0 software (IBM Corp., Armonk, USA) was used for the data analysis. Descriptive statistics were applied for the calculation of the mean age of the subjects. The Shapiro–Wilk test was applied to determine the normality of the data, which showed a non-normal distribution. The Wilcoxon signed-rank test was used to compare the PF1 and PF2 values, and the PF1 and PT values. The results were regarded statistically significant at  $p \leq 0.05$ .

The measurements on lateral cephalograms were taken by a single researcher; however, to test the intra-operator reliability, we randomly selected 30 lateral cephalograms and orthodontic casts, which were digitally re-measured using identical methodology after 3 weeks by the principal investigator. The intra-class correlation coefficient (ICC) showed a high degree of agreement, ranging from 0.85 to 0.9 between the 2 readings.

## Results

An equal number of male and female subjects was included. The mean age of the subjects was  $12.5 \pm 0.5$  years for males and  $12.3 \pm 0.7$  years for females. The comparison of the PF1 and PF2 values showed significant differences in the tongue posture at distances 1–5 and in the linear distance from the sella (S) to the most anterior point on the hyoid bone (H) – the SH distance ( $p < 0.01$ ) (Table 1). Similar results were found with regard to the PF1 and PT values, including the C3-H distance, which was also observed to be significantly different ( $p < 0.01$ ) (Table 2). A significant improvement in the overjet ( $p < 0.01$ ), ANB ( $p < 0.01$ ) and the mandibular length ( $p < 0.01$ ) was found when comparing the PT and PF1 values.

The medians and interquartile ranges (IRs) of the inter-molar and inter-canine widths of both arches at the PF1 and PT stages are presented in Table 2. Significant

differences in the maxillary inter-canine ( $p = 0.01$ ) and inter-molar ( $p < 0.01$ ) widths, and in the mandibular inter-canine ( $p = 0.04$ ) and inter-molar ( $p = 0.02$ ) widths were found in the PF1 and PT values.

## Discussion

Evidence from human and animal studies supports the claim that mandibular growth can be stimulated.<sup>21–23</sup> The goal of TBA therapy is to correct the craniofacial architecture by stimulating the growth of the jaws in a favorable direction.<sup>24</sup> The mandible is displaced anteriorly by TBA, influencing the position of the hyoid bone, and consequently the tongue posture.<sup>10</sup> Thus, the focus of this study was to evaluate the tongue posture and the hyoid bone position after TBA therapy.

The soft tissue profile improves after TBA therapy, reflecting substantial changes at the hard tissue level.<sup>25</sup> Johnston claimed that functional appliances hardly induce mandibular growth.<sup>26</sup> In contrast, the present study indicated a marked increase in the mandibular length after treatment with TBA. The skeletal change was also depicted by a decrease in the values of ANB from  $6^\circ$  to  $5^\circ$  and of the overjet from 9.5 mm to 3.0 mm, which is in close agreement to other studies.<sup>27,28</sup>

The hyoid bone acts as an anchor unit, and serves as an attachment area for several muscles of the tongue, mandible and throat.<sup>29</sup> The orthopedic outcome of TBA therapy is the displacement of the mandible and of the hyoid bone in a forward direction, leading to a beneficial effect on the posterior pharyngeal airway by the anterior traction of the tongue.<sup>28</sup> Our results showed significant changes in posture in the posterior and middle portion of the tongue after TBA therapy. However, distance 6 was maintained and it revealed a non-significant difference. In order to assess the stability of the appliance effects, the subjects were evaluated after

**Table 1.** Comparison of the pre-functional (PF1) and post-functional (PF2) values for the tongue posture and for the hyoid position

Cephalometric variables	PF1		PF2		p-value
	median	IR	median	IR	
Tongue posture					
Distance 1 [mm]	23.00	21.00–27.25	25.50	22.75–29.25	0.054*
Distance 2 [mm]	19.00	17.00–22.00	21.50	18.00–25.00	0.001**
Distance 3 [mm]	19.00	15.00–22.00	20.50	17.75–23.00	<0.001**
Distance 4 [mm]	20.00	17.00–23.25	23.00	20.75–26.00	<0.001**
Distance 5 [mm]	24.50	22.00–28.00	27.50	24.75–30.25	<0.001**
Distance 6 [mm]	35.50	33.00–38.25	36.00	33.75–37.25	0.289
Hyoid position					
SH [mm]	99.50	89.75–106.25	99.50	95.00–108.25	0.003**
C3-H [mm]	31.00	28.75–34.50	32.00	29.00–36.00	0.281
NSH [°]	92.00	89.00–97.50	91.00	88.00–98.00	0.385
H-GoGn [mm]	15.00	10.00–18.50	15.50	10.00–19.00	0.837

IR – interquartile range; \*  $p \leq 0.05$ ; \*\*  $p \leq 0.01$  (the Wilcoxon signed-rank test).



**Table 2.** Comparison of the pre-functional (PF1) and post-treatment (PT) cephalometric parameters

Cephalometric variables	PF1		PT		p-value
	median	IR	median	IR	
<b>Tongue posture</b>					
Distance 1 [mm]	23.00	21.00–27.25	30.00	26.75–32.00	<0.001**
Distance 2 [mm]	19.00	17.00–22.00	24.00	21.75–27.00	<0.001**
Distance 3 [mm]	19.00	15.00–22.00	22.00	20.00–25.00	<0.001**
Distance 4 [mm]	20.00	17.00–23.25	25.50	23.00–27.25	<0.001**
Distance 5 [mm]	24.50	22.00–28.00	29.00	26.00–30.00	<0.001**
Distance 6 [mm]	35.50	33.00–38.25	35.50	34.00–38.25	0.806
<b>Hyoid position</b>					
SH [mm]	99.50	89.75–106.25	108.00	98.00–117.25	<0.001**
C3-H [mm]	31.00	28.75–34.50	34.00	30.75–41.00	<0.001**
NSH [°]	92.00	89.00–97.50	92.50	89.75–94.25	<0.419
H-GoGn [mm]	15.00	10.00–18.50	15.00	11.00–22.00	<0.442
<b>Skeletal parameters</b>					
ANB [°]	6.00	5.00–8.00	5.00	3.00–6.00	<0.001**
Go-Gn [°]	70.00	68.00–74.50	77.00	72.00–82.50	<0.001**
Co-Gn [°]	102.00	98.00–110.75	110.00	104.75–119.50	<0.001**
<b>Dental parameters</b>					
Overjet [mm]	9.50	7.75–11.00	3.00	3.00–4.00	<0.001**
Maxillary inter-canine width [mm]	24.85	22.75–26.75	25.60	24.40–26.50	0.014**
Maxillary inter-molar width [mm]	34.55	33.37–35.92	36.95	35.77–39.00	<0.001**
Mandibular inter-canine width [mm]	21.60	20.67–23.07	21.35	19.85–21.82	0.046*
Mandibular inter-molar width [mm]	34.50	32.35–36.32	25.15	34.35–36.35	0.021*

Go-Gn – distance from Go to Gn; Co-Gn – distance from Co to Gn; \*  $p \leq 0.05$ ; \*\*  $p \leq 0.01$  (the Wilcoxon signed-rank test).

the 2<sup>nd</sup> phase of fixed orthodontic treatment. The improvement achieved by means of TBA therapy was sustained after fixed appliance treatment. The literature supports the claim that subjects with a retrognathic mandible have decreased airway dimensions.<sup>30,31</sup> A lowered posture of the tongue depicted in our study after TBA therapy minimizes the chance of collapsibility of the velopharynx; this occurs as a result of the tongue being attached to the lateral walls of the soft palate via the palatoglossal arch.<sup>32</sup> The gravitational influence of the tongue on the soft palate, though weak in nature, is also reduced by its lowered posture and, in effect, increases the airflow.<sup>32</sup> Our findings are in agreement with studies conducted by various authors who have reported an increase in the tongue area and in the intermaxillary space as a result of functional appliance therapy.<sup>18,19</sup> Liu et al. stated that the tongue dorsum is lowered after the use of mandibular anterior repositioning appliances in patients with OSA.<sup>33</sup>

There is a controversy in the literature regarding the change in the position of the hyoid bone.<sup>2,17,34</sup> Schendel and Epker and LaBanc and Epker reported that, due to compensatory action, the hyoid bone moves to its original position.<sup>35,36</sup> However, we found the vertical repositioning of the hyoid bone to be significant, whereas the change in angulation after TBA therapy was non-significant. Growth guidance may allow the mutual adaptability of form and function to the altered position of the hyoid bone.<sup>37</sup> Adaptations may

occur within the connective tissue attachments of the hyoid bone or in the belly of suprahyoid muscles.<sup>38</sup>

The transverse dimensions of the maxillary and mandibular arches were determined by measuring the inter-canine and inter-molar widths, which revealed significant differences. Active expansion during TBA therapy remains stable after fixed appliance treatment. Ozbek et al. state that the expansion of the dentoalveolar segments creates additional space for the tongue to accommodate within the oral cavity.<sup>39</sup> Improvement in the tongue posture and an increase in the nasal canal area result in better retropalatal and retroglottal airflows.<sup>40</sup>

An abnormal tongue posture is one of the causative factors for malocclusion and post-treatment relapse.<sup>6,40</sup> The normalization of the tongue posture might break the cycle of imbalanced muscular activity, thus leading to the harmonious growth patterns of the jaws and stable occlusion.<sup>29,40</sup> We speculate that this kind of intervention for treating a retrognathic mandible may help to eliminate the predisposing factors for OSA and prevent complex treatment modalities in adulthood.

It was a single-center study, which is why the results may not be extrapolated to different ethnic groups. The limitation of this cross-sectional study is that it was conducted on a group of treated patients using routine cephalograms, which provides two-dimensional (2D) information.


We recommend a prospective cohort study to compare the normal growth of the mandible, and changes in the hyoid bone position and in the tongue posture in non-treated individuals using a three-dimensional (3D) imaging modality for a comprehensive evaluation. Furthermore, there should be a long-term follow up to evaluate the changes achieved with TBA therapy and the stability of the results.

## Conclusions

This cross-sectional study demonstrated a lowered repositioning of the tongue and the inferior displacement of the hyoid bone after TBA therapy. There was improvement in the sagittal skeletal relationship due to an increased mandibular body length. The expansion achieved during TBA therapy was significant and stable after the completion of fixed appliance treatment.

### ORCID iDs

Erum Afzal  <https://orcid.org/0000-0001-5403-858X>

Mubassar Fida  <https://orcid.org/0000-0003-4842-9896>

### References

- Proffit WR, Fields HW, Sarver DM. *Contemporary Orthodontics*. 5<sup>th</sup> ed. St. Louis, MO: Mosby; 2013.
- Bavbek NC, Tuncer BB, Turkoz C, Ulusoy C, Tuncer C. Changes in airway dimensions and hyoid bone position following class II correction with forsus fatigue resistant device. *Clin Oral Investig*. 2016;20(7):1747–1755.
- Carlson DS. Theories of craniofacial growth in the postgenomic era. *Semin Orthod*. 2005;11(4):172–183.
- Gul-e-Erum, Fida M. Pattern of malocclusion in orthodontic patients: A hospital-based study. *J Ayub Med Coll Abbottabad*. 2008;20(1):43–47.
- Giuntini V, Vangelisti A, Masucci C, Defraia E, McNamara JA Jr, Franchi L. Treatment effects produced by the Twin-block appliance vs the Forsus Fatigue Resistant Device in growing Class II patients. *Angle Orthod*. 2015;85(5):784–789.
- Yamaguchi H, Sueishi K. Malocclusion associated with abnormal posture. *Bull Tokyo Dent Coll*. 2003;44(2):43–54.
- Bandy HE, Hunter WS. Tongue volume and the mandibular dentition. *Am J Orthod*. 1969;56(2):134–142.
- Jacobs RM. Muscle equilibrium: Fact or fancy. *Angle Orthod*. 1969;39(1):11–21.
- Lin YC, Lin HC, Tsai HH. Changes in the pharyngeal airway and position of the hyoid bone after treatment with a modified bionator in growing patients with retrognathia. *J Exp Clin Med*. 2011;3(2):93–98.
- Ghodke S, Utreja AK, Singh SP, Jena AK. Effects of twin-block appliance on the anatomy of pharyngeal airway passage (PAP) in class II malocclusion subjects. *Prog Orthod*. 2014;15:68.
- Graber TM. *Orthodontics: Principles and Practice*. 2<sup>nd</sup> ed. Philadelphia, PA: W.B. Saunders Company; 1966.
- Santos Junior JF, Abrahão M, Gregório LC, Zonato AI, Gumieiro EH. Genioplasty for genioglossus muscle advancement in patients with obstructive sleep apnea-hypopnea syndrome and mandibular retrognathia. *Braz J Otorhinolaryngol*. 2007;73(4):480–486.
- Cozza P, Baccetti T, Franchi L, De Toffol L, McNamara JA Jr. Mandibular changes produced by functional appliances in Class II malocclusion: A systematic review. *Am J Orthod Dentofacial Orthop*. 2006;129(5):599.e1–e12.
- Clark WJ. The twin block technique. A functional orthopedic appliance system. *Am J Orthod Dentofacial Orthop*. 1988;93(1):1–8.
- Ehsani S, Nebbe B, Normando D, Lagravere MO, Flores-Mir C. Dental and skeletal changes in mild to moderate Class II malocclusions treated by either a Twin-block or Xbow appliance followed by full fixed orthodontic treatment. *Angle Orthod*. 2015;85(6):997–1002.
- Brierley CA, DiBiase A, Sandler PJ. Early class II treatment. *Aust Dent J*. 2017;62(S1):4–10.
- Restrepo C, Santamaría A, Peláez S, Tapias A. Oropharyngeal airway dimensions after treatment with functional appliances in class II retrognathic children. *J Oral Rehabil*. 2011;38(8):588–594.
- Ozdemir F, Ulkur F, Nalbantgil D. Effects of fixed functional therapy on tongue and hyoid positions and posterior airway. *Angle Orthod*. 2014;84(2):260–264.
- Yassaei S, Tabatabaei Z, Ghafurifard R. Stability of pharyngeal airway dimensions: Tongue and hyoid changes after treatment with a functional appliance. *Int J Orthod Milwaukee*. 2012;23(1):9–15.
- Steiner CC. Cephalometrics in clinical practice. *Angle Orthod*. 1959;29(1):8–29.
- DeVincenzo JP. Changes in mandibular length before, during, and after successful orthopedic correction of Class II malocclusions, using a functional appliance. *Am J Orthod Dentofacial Orthop*. 1991;99(3):241–257.
- Charlier JP, Petrovic A, Herrmann-Stutzmann J. Effects of mandibular hyperpropulsion on the prechondroblastic zone of young rat condyle. *Am J Orthod*. 1969;55(1):71–74.
- DeVincenzo JP. A study in human subjects using a new device designed to mimic the protrusive functional appliances used previously in monkeys. *Am J Orthod*. 1987;91(3):213–224.
- Jena AK, Duggal R. Treatment effects of twin-block and mandibular protraction appliance-IV in the correction of class II malocclusion. *Angle Orthod*. 2010;80(3):485–491.
- Baysal A, Uysal T. Soft tissue effects of Twin Block and Herbst appliances in patients with Class II division 1 mandibular retrognathia. *Eur J Orthod*. 2011;35(1):71–81.
- Johnston LE Jr. Functional appliances: A mortgage on mandibular position. *Aust Orthod J*. 1996;14(3):154–157.
- Mills CM, McCulloch KJ. Posttreatment changes after successful correction of Class II malocclusions with the twin block appliance. *Am J Orthod Dentofacial Orthop*. 2000;118(1):24–33.
- Schütz TC, Dominguez GC, Hallinan MP, Cunha TC, Tufik S. Class II correction improves nocturnal breathing in adolescents. *Angle Orthod*. 2011;81(2):222–228.
- Tseng YC, Wu JH, Chen CM, Hsu KJ. Correlation between change of tongue area and skeletal stability after correction of mandibular prognathism. *Kaohsiung J Med Sci*. 2017;33(6):302–307.
- Muto T, Yamazaki A, Takeda S. A cephalometric evaluation of the pharyngeal airway space in patients with mandibular retrognathia and prognathia, and normal subjects. *Int J Oral Maxillofac Surg*. 2008;37(3):228–231.
- Nanda M, Singla A, Negi A, Jaj HS, Mahajan V. The association between maxillomandibular sagittal relationship and pharyngeal airway passage dimensions. *J Ind Orthod Soc*. 2012;46(1):48–52.
- Poon KH, Chay SH, Chiong KF. Airway and craniofacial changes with mandibular advancement device in Chinese with obstructive sleep apnea. *Ann Acad Med Singapore*. 2008;37(8):637–644.
- Liu Y, Zeng X, Fu M, Huang X, Lowe AA. Effects of a mandibular repositioner on obstructive sleep apnea. *Am J Orthod Dentofacial Orthop*. 2000;118(3):248–256.
- Zhou L, Zhao Z, Lu D. The analysis of the changes of tongue shape and position, hyoid position in Class II, division 1 malocclusion treated with functional appliances (FR-I) [in Chinese]. *Hua Xi Kou Qiang Yi Xue Za Zhi*. 2000;18(2):123–125.
- Schendel SA, Epker BN. Results after mandibular advancement surgery: An analysis of 87 cases. *J Oral Surg*. 1980;38(4):265–282.
- LaBanc JP, Epker BN. Changes of the hyoid bone and tongue following advancement of the mandible. *Oral Surg Oral Med Oral Pathol*. 1984;57(4):351–356.
- Graber LW. Hyoid changes following orthopedic treatment of mandibular prognathism. *Angle Orthod*. 1978;48(1):33–38.
- Eggensperger N, Smolka K, Johner A, Rahal A, Thüer U, Iizuka T. Long-term changes of hyoid bone and pharyngeal airway size following advancement of the mandible. *Oral Surg Oral Med Oral Pathol Oral Radiol Endod*. 2005;99(4):404–410.
- Ozbek MM, Memikoglu UT, Altug-Atac AT, Lowe AA. Stability of maxillary expansion and tongue posture. *Angle Orthod*. 2009;79(2):214–220.
- Iwasaki T, Saitoh I, Takemoto Y, et al. Tongue posture improvement and pharyngeal airway enlargement as secondary effects of rapid maxillary expansion: A cone-beam computed tomography study. *Am J Orthod Dentofacial Orthop*. 2013;143(2):235–245.