



THE AGA KHAN UNIVERSITY

eCommons@AKU

---

Medical College Documents

Medical College, Pakistan

---

3-2020

## Anomalous origin of the left coronary artery from the pulmonary artery: A surgical certainty

Ayesha Butt  
*Aga Khan University*

Muhammad Muneer Amanullah  
*National Institute of Cardiovascular Diseases, Pakistan*

Mehnaz Atiq Ahmed  
*National Hospital and Medical College, Karachi, Pakistan*

Asif Hasan  
*Freeman Hospital, Newcastle Upon Tyne, UK.*

Waris Ahmad  
*Aga Khan University, waris.ahmad@aku.edu*

Follow this and additional works at: [https://ecommons.aku.edu/pakistan\\_fhs\\_mc\\_mc](https://ecommons.aku.edu/pakistan_fhs_mc_mc)



Part of the [Cardiology Commons](#), [Cardiovascular Diseases Commons](#), [Pulmonology Commons](#), [Respiratory Tract Diseases Commons](#), and the [Surgery Commons](#)

---

### Recommended Citation

Butt, A., Amanullah, M. M., Ahmed, M. A., Hasan, A., Ahmad, W. (2020). Anomalous origin of the left coronary artery from the pulmonary artery: A surgical certainty. *JPMA. The Journal of the Pakistan Medical Association*, 70(3), 561-564.

Available at: [https://ecommons.aku.edu/pakistan\\_fhs\\_mc\\_mc/110](https://ecommons.aku.edu/pakistan_fhs_mc_mc/110)

## Anomalous origin of the left coronary artery from the pulmonary artery: A surgical certainty

Ayesha Butt<sup>1</sup>, Muhammad Muneer Amanullah<sup>2</sup>, Mehnaz Atiq Ahmed<sup>3</sup>, Asif Hasan<sup>4</sup>, Waris Ahmad<sup>5</sup>

### Abstract

This study aims to assess the clinical presentation and the outcomes of a surgical correction of an anomalous origin of the left coronary artery from the pulmonary artery (ALCAPA). A retrospective review was carried out on the charts of six patients admitted for ALCAPA surgery at Aga Khan University Hospital, Karachi from March 2017 to May 2018. Dyspnoea, palpitation, poor feeding, fatiguability, pallor and a murmur of mitral regurgitation were the main presenting features. The pre-operative median left ventricular ejection fraction (LVEF) was 64%. Coronary re-implantation was performed in all the patients with a mitral valve repair being done in only one patient. The mean LVEF was 66.3%, post-operatively. Mitral regurgitation (MR) improved in patients post-operatively with trace in 2 patients and mild MR in one. Surgical correction by coronary re-implantation yields favourable outcomes in ALCAPA and significantly reduces the morbidity and mortality rates associated with the disease.

**Keywords:** Bland-White-Garland syndrome, ALCAPA, Cardiovascular Diseases, Congenital Heart Defects, Coronary Vessel Anomalies

<https://doi.org/10.5455/JPMA.34200>

### Introduction

<sup>1</sup>Anomalous origin of a left coronary artery from the pulmonary artery (ALCAPA) is a rare congenital abnormality comprising 0.25 %-0.5 % of all congenital heart anomalies and occurs in 1 in every 300,000 live births.<sup>1</sup> The left coronary artery (LCA) branches off the pulmonary artery rather than the aorta in this condition. Reduced pulmonary artery pressures arising postnatally

leads to a 'coronary steal' phenomenon, in which the blood is directed away from the myocardial vessels to the pulmonary artery resulting in a left to right shunting of the blood along with a left ventricular (LV) dysfunction and mitral regurgitation (MR) secondary to a myocardial ischaemia. This condition leads to a mortality in 90% of the affected infants<sup>1</sup> and the chances of sudden death in surgically uncorrected individuals occurring at a mean age of 35 years, is 80-90% in those who experience adulthood.<sup>2</sup> Hence, a diagnosis of ALCAPA mandates urgent surgical correction.<sup>3</sup> There is a dearth of literature on surgical correction of ALCAPA in the Pakistani population and in this report, we aim to describe the clinical presentation and surgical correction for ALCAPA.

### Case Series

A retrospective review of the charts of six consecutive patients who underwent surgical correction for ALCAPA in the Aga Khan University Hospital from March 2017 to May 2018 was carried out. Patient demographics, presentation, operative details and postoperative course were noted. Simple frequencies and proportions were calculated to describe the data using an IBM SPSS version 23. Consent of the all patients/guardians was taken prior to writing this manuscript.

### Results

A total of six patients (Table 1) who underwent surgical correction for ALCAPA were included in this study. There were three male and three female patients. Pre-operative mean left ventricular ejection fraction (LVEF) was 64% (range 19-67).

ALCAPA with normal/mildly depressed Left ventricular ejection fraction (LVEF) and mild to moderate mitral regurgitation (MR): Dyspnoea was present in 3 out of the 4 symptomatic patients (Table) in this category. Symptoms of chest pain and palpitation were reported by one patient and poor feeding was present in the other. The third patient had an incidental finding of ALCAPA on

<sup>1</sup>4th Year MBBS Student, Aga Khan University Medical College, Karachi, Pakistan;

<sup>2</sup>Department of Pediatric Cardiac Services, National Institute of Cardiovascular Diseases, Karachi, Pakistan; <sup>3</sup>Department of Pediatrics, Liaquat National Hospital and Medical College, Karachi, Pakistan; <sup>4</sup>Department Cardio thoracic Surgery, Freeman Hospital, Newcastle, United Kingdom; <sup>5</sup>Department of Surgery, Aga Khan University Hospital, Karachi, Pakistan

**Correspondence:** Ayesha Butt. e-mail: ayeshabutt21@outlook.com

**Table:** Patient details: demographics, pre-operative and post-operative details [LVEF: Left ventricular ejection fraction, MR: Mitral Regurgitation].

Characteristic	Patient 1	Patient 2	Patient 3	Patient 4	Patient 5	Patient 6
Age at surgery, years	15	1.5	9	14	8	6
Sex	Male	Female	Male	Female	Male	Female
Presenting symptoms or signs	Dyspnoea Poor feeding	Poor feeding, fatiguability Pallor	Incidental finding	Dyspnoea, Palpitation	Dyspnoea, Chest pain, Palpitation	Dyspnoea
<b>Preoperative Echocardiography findings</b>						
(Detailed records not available for Patient 5: Work up done at another centre)						
Fractional Shortening, %	30	12	36	30	-----	25
Preoperative LVEF, %	66	19	67	64	-----	50
Preoperative MR	Moderate	Mild	Trivial	Moderate to severe	Mild	Mild
<b>FINDINGS AT FOLLOW UP</b>						
LVEF at follow up, %	74	25	Lost to follow up	Lost to follow up	67.5	67
Improvement in LVEF after surgery, %	12	32	Lost to follow up	Lost to follow up	-----	34

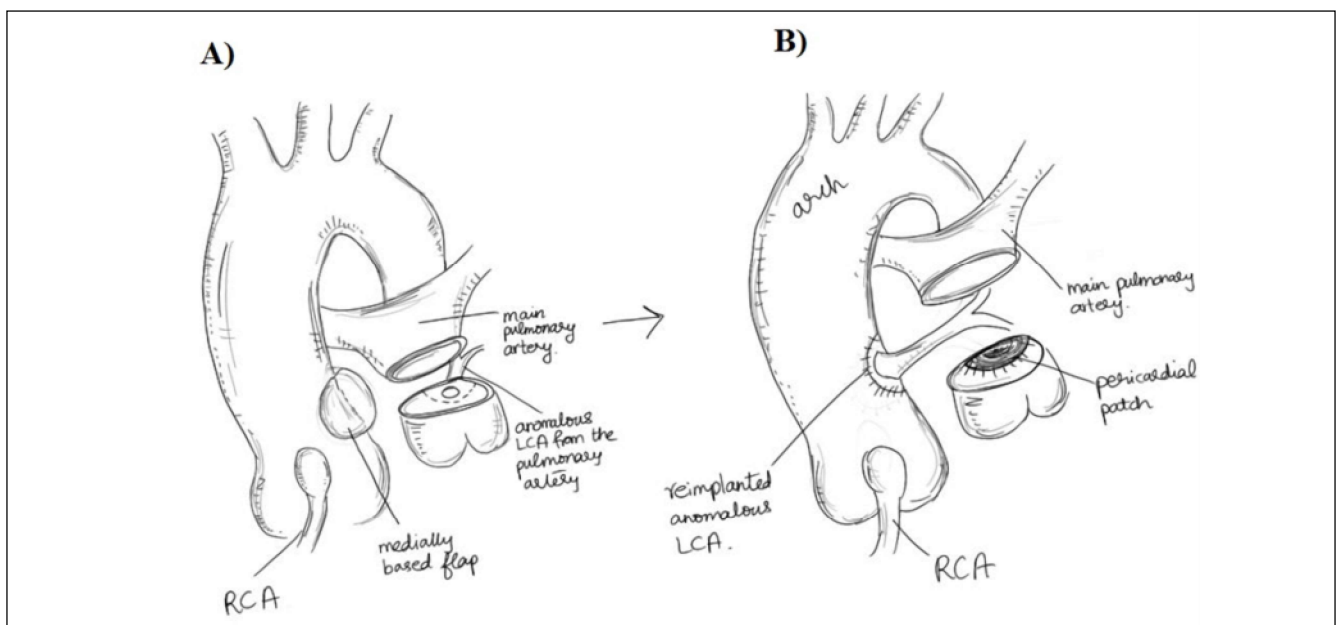
echocardiography. A grade 2 murmur of MR was present in only one patient.

**ALCAPA with severe MR:** Dyspnoea, palpitation and recurrent respiratory tract infections in the first two years of life were present in one patient with severe MR. On echocardiography, left ventricle was dilated with no hypertrophy. In addition to coronary re-implantation, repair of mitral valve (annuloplasty) was done in this patient.

**ALCAPA with severely depressed left ventricular function:** Poor feeding, fatiguability, pallor, signs of poor peripheral perfusion and cardiomegaly were present in this patient with a LVEF of 19%. A globular hugely dilated

left ventricle was seen on echocardiography. She showed a 31.58% improvement in the LVEF after surgery.

**Surgical technique:** A median sternotomy was done followed by a partial dissection of the thymus and the pericardium. The aorta and pulmonary arteries were dissected and slings were created around the branch pulmonary arteries. Following this, the right atrium and the aorta were cannulated for a cardiopulmonary bypass. After initiation of the hypothermia, an aortic cross-clamp was used and the pulmonary arteries were obstructed with slings. In order to cause a diastolic arrest with preservation of the myocardium, an ante-grade cold blood cardioplegia was used.



**Figure:** In this technique, the first step (A) is to transect the pulmonary trunk, and harvest the button containing the anomalous left coronary artery. The button is then re-implanted to the aorta (B), and the defect in the proximal part of the pulmonary trunk is repaired using a patch of autologous pericardium. (RCA: Right Coronary Artery LCA: Left Coronary Artery).

Transection of the pulmonary artery was carried out 5 millimetre higher than the commissures. The anomalous LCA was then dissected from the pulmonary artery in the form of a large button (the posterior facing sinus wall was completely used as a button); LCA was dissected as much as possible from the surrounding structures using a sharp dissection in order to achieve greatest mobility and tension free anastomosis. Left wall of the aorta was cut open and a medially based flap was created to seat the ALCAPA button. The button was then anastomosed to the aortic wall using 6-0 prolene suture. An autologous pericardial patch was used to rebuild the defect in the pulmonary artery. The pulmonary trunk was also anastomosed using a 6-0 prolene suture. Mitral valve repair was undertaken in one patient through a left atrial approach. The median aortic cross clamp time was  $65.0 \pm 30.6$  minutes and the median cardiopulmonary bypass time was  $105.0 \pm 26.5$  minutes. Sternal closure was delayed in one patient with a poor LV function; it was closed 24 hours later with good haemodynamics.

**Post-operative Course:** No mortality was noted. Supra Ventricular Tachycardia occurred in one patient. Patients were discharged on an anti-failure therapy.

**Follow-Up:** Loss to follow-up occurred in two cases. In the remaining four patients, the mean LVEF was 66.3% at follow up. MR also improved in all patients post-operatively. No stenosis of the coronary ostium was observed in any patient.

## Discussion

ALCAPA is a highly significant cause of myocardial infarction in the paediatric population and an early diagnosis is crucial for a favourable prognosis. A review of ALCAPA patients revealed the presence of symptoms of angina, dyspnoea, palpitations or fatigue in 66% of the patients; ventricular arrhythmia, syncope or sudden death in 17% patients while 14% of the patients remained asymptomatic.<sup>4</sup> The main symptom in infants is irritability upon slight exertion such as feeding.<sup>1</sup> Similar symptoms were seen in our study.

In ALCAPA patients, chest X-ray often shows cardiomegaly<sup>5</sup> and there is an evidence of an anterolateral infarct pattern on the ECG with presence of Q waves in almost 50% of the patients.<sup>4</sup> A dilated right coronary artery (RCA), retrograde Doppler flow from the left coronary artery (LCA) to pulmonary artery (PA) and a septal flow due to collaterals are characteristic findings on

echocardiography.<sup>6</sup> Presence of a large, tortuous RCA and collateral filling of the LCA is demonstrated on the coronary angiography and is visualized on a cardiac computerised tomography (CT) and/or magnetic resonance imaging (MRI). These imaging techniques allow visualization of the origin of LCA from PA while MRI allows assessment of the myocardial viability and ischaemia.<sup>7</sup>

Different techniques for the surgical rectification of the ALCAPA including ligation of the anomalous left coronary artery and subclavian-left coronary artery anastomosis have been described.<sup>8</sup> However, in recent times, surgery is aimed at creating a two-coronary system by any of the following methods, a) transection of the anomalous LCA and a bypass graft from the saphenous vein or a mammary artery b) Takeuchi procedure, where an intrapulmonary window from aorta-pulmonary window to an anomalous LCA is made c) coronary re-implantation, in which the LCA is translocated from the PA to the aorta.<sup>5</sup> Coronary re-implantation has shown superior results compared to other methods and is the method of choice<sup>1,8</sup> and was the technique used for surgical correction in all the patients in this study.

Performing mitral valve repair simultaneously with an initial surgery is not recommended as mitral regurgitation improves with ALCAPA repair<sup>3</sup> and the added ischaemic time in surgery could be deleterious on the background of a poor ventricular function.<sup>2</sup> Among the patients in this study, simultaneous repair of the mitral valve was undertaken in only one patient who had moderate to severe mitral regurgitation pre-operatively.

However, surgical repair of ALCAPA yields excellent results with a study showing 20 year survival in 94.8% patients.<sup>8</sup> Similarly, in this study no mortality was noted and the patients were doing well at follow-ups.

## Conclusion

Establishment of a two-coronary system by coronary artery re-implantation has favourable outcomes in treating ALCAPA leading to improvement in the left ventricular function and mitral regurgitation. It significantly reduces the morbidity and mortality associated with the disease and is the treatment of choice.

**Disclaimer:** none to declare

**Conflict of Interest:** none to declare

**Funding Disclosure:** none to declare

## References

1. Rodriguez-Gonzalez M, Tirado AM, Hosseinpour R, de Soto JS. Anomalous origin of the left coronary artery from the pulmonary artery: diagnoses and surgical results in 12 pediatric patients. *Tex Heart Inst J* 2015;42:350-6.
  2. Muneer Amanullah M, Rostron AJ, Leslie Hamilton JR, Chaudhari MP, Hasan A. Towards an anatomically correct repair for anomalous left coronary artery arising from the pulmonary trunk. *Cardiol Young* 2008;18:372-8.
  3. Ling Y, Bhushan S, Fan Q, Tang M. Midterm outcome after surgical correction of anomalous left coronary artery from the pulmonary artery. *J Cardiothorac Surg* 2016;11:137.
  4. Yau JM, Singh R, Halpern EJ, Fischman D. Anomalous origin of the left coronary artery from the pulmonary artery in adults: a comprehensive review of 151 adult cases and a new diagnosis in a 53-year-old woman. *Clin Cardiol* 2011;34:204-10.
  5. Kristensen T, Kofoed KF, Helqvist S, Helvind M, Sondergaard L. Anomalous origin of the left coronary artery from the pulmonary artery (ALCAPA) presenting with ventricular fibrillation in an adult: a case report. *J Cardiothorac Surg* 2008;3:33.
  6. Yang YL, Nanda NC, Wang XF, Xie MX, Lu Q, He L, et al. Echocardiographic diagnosis of anomalous origin of the left coronary artery from the pulmonary artery. *Echocardiography* 2007;24:405-11.
  7. Pena E, Nguyen ET, Merchant N, Dennie C. ALCAPA syndrome: not just a pediatric disease. *Radiographics* 2009;29:553-65.
  8. Lange R, Vogt M, Horer J, Cleuziou J, Menzel A, Holper K, et al. Long-term results of repair of anomalous origin of the left coronary artery from the pulmonary artery. *Ann Thorac Surg* 2007;83:1463-71.
-