



THE AGA KHAN UNIVERSITY

eCommons@AKU

---

Section of Pulmonary & Critical Care

Department of Medicine

---

April 1996

# Endobronchial tuberculosis--manifesting by coughing up of bronchial cartilage

A.M. Memon  
*Aga Khan University*

A Shafi

H Thawerani

Follow this and additional works at: [https://ecommons.aku.edu/pakistan\\_fhs\\_mc\\_med\\_pulm\\_critcare](https://ecommons.aku.edu/pakistan_fhs_mc_med_pulm_critcare)



Part of the [Critical Care Commons](#), and the [Pulmonology Commons](#)

---

## Recommended Citation

Memon, A. M., Shafi, A., Thawerani, H. (1996). Endobronchial tuberculosis--manifesting by coughing up of bronchial cartilage. *Journal of Pakistan Medical Association*, 46(4), 86-88.

**Available at:** [https://ecommons.aku.edu/pakistan\\_fhs\\_mc\\_med\\_pulm\\_critcare/93](https://ecommons.aku.edu/pakistan_fhs_mc_med_pulm_critcare/93)

# Endobronchial Tuberculosis Manifesting by Coughing Up of Bronchial Cartilage

Pages with reference to book, From 86 To 88

Abdul Majeed Memon ( Department of Medicine, Aga Khan University Hospital, Karachi. )

Anwar Shafi ( Ziauddin Postgraduate Institute of Medical Sciences, Karachi. )

Hasina Thawerani ( National Institute of Cardiovascular Diseases, Karachi. )

## Introduction

As compared to the Tuberculosis involving the lung parenchyma, endobronchial tuberculosis (EBTB) is less well known. The importance of endobronchial tuberculosis lies in the fact that it has varied clinical manifestations and the diagnosis can be missed at initial presentation. We describe a case where endobronchial tuberculosis manifested by expectoration of bronchial cartilage.

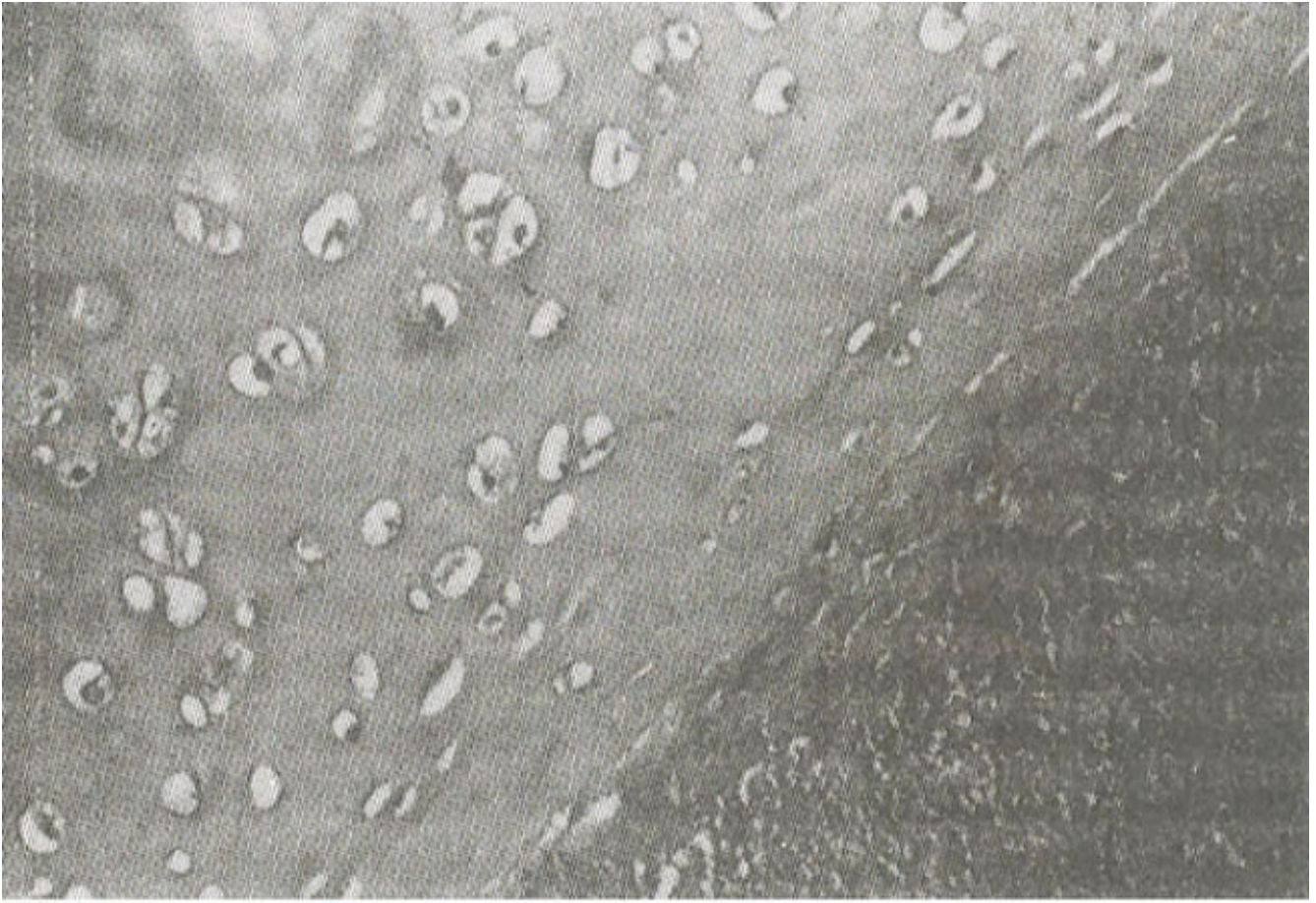
## Case Report

A 32 years old physician presented with a four months history of severe cough, initially dry but later on productive with copious whitish sputum, dyspnea and wheezing. The cough and dyspnea were aggravated on lying down causing difficulty in sleeping at night. He gave no history of fever, haemoptysis or weight loss. The past medical history was insignificant and he denied any family history of tuberculosis. He did not have any wheezing spells in the past.

Physical examination revealed an apparently healthy young man with normal weight, temperature and blood pressure. There was no lymphadenopathy. Abdominal, cardiovascular and central nervous system examination were normal. The chest examination revealed moderate bilateral wheeze.

His Hb was 13.9 g/dl, WBC  $7.7 \times 10^9/L$  with neutrophils 72% and lymphocytes 21% and ESR 40 mmHg after the first hour. Chest X- ray, PA and lateral views did not show any infiltrative or cavitory lesion.

He was given bronchodilators and oral as well as inhalation steroid therapy with minimal relief of symptoms. Approximately a week later he coughed up a whitish meat like mass measuring 1.5x1.0x0.6 cm in volume after which his wheezing and dyspnea subsided and he had minimal residual cough. Microscopic examination of the expectorated material revealed a crescentic rim of focally necrotic hyaline cartilage (Figure 1)



**Figure 1. Portion of hyaline cartilage in the expectorated material.**  
around necrotic material with partially autolysed granulomas (Figure 2),



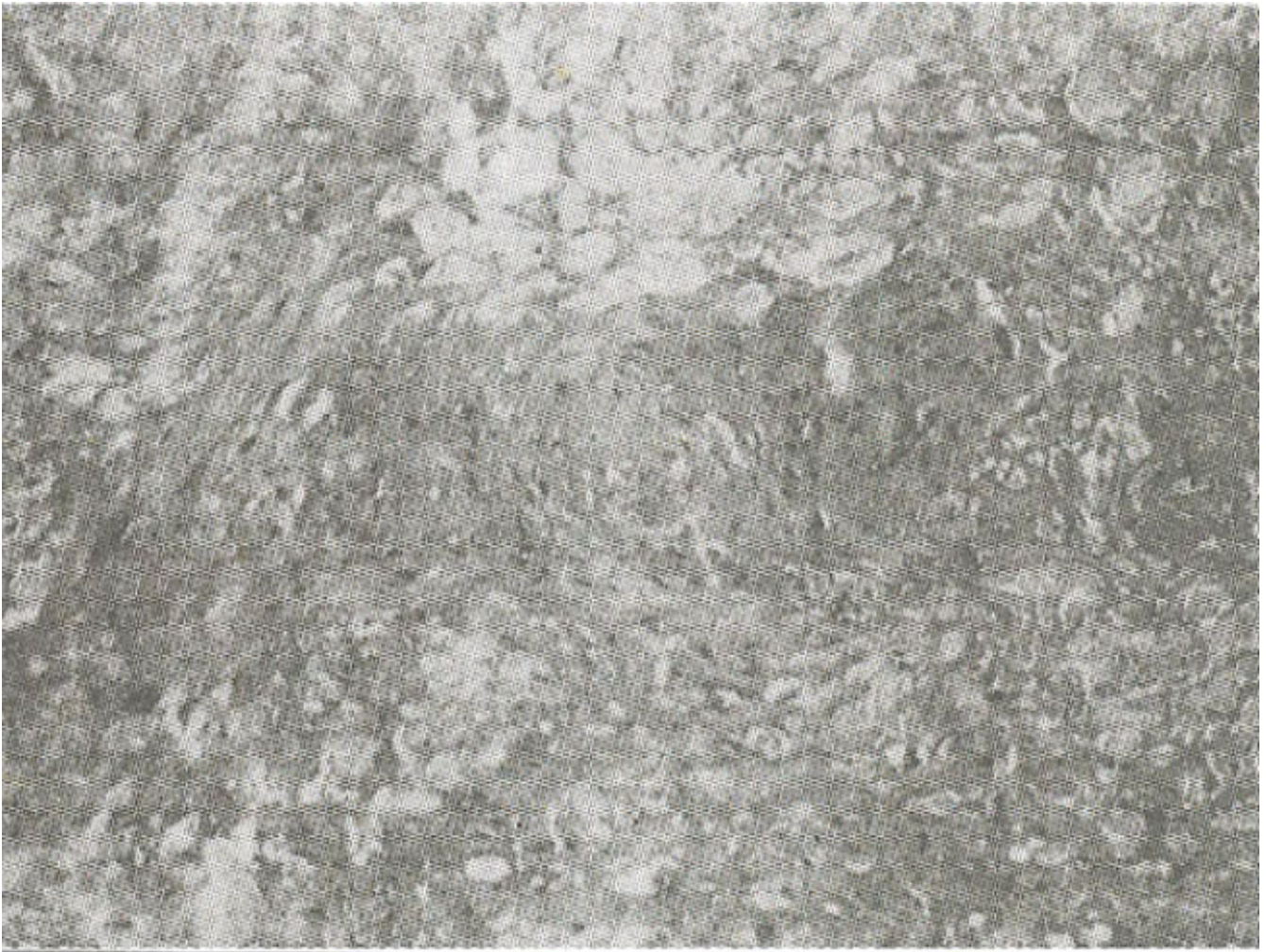
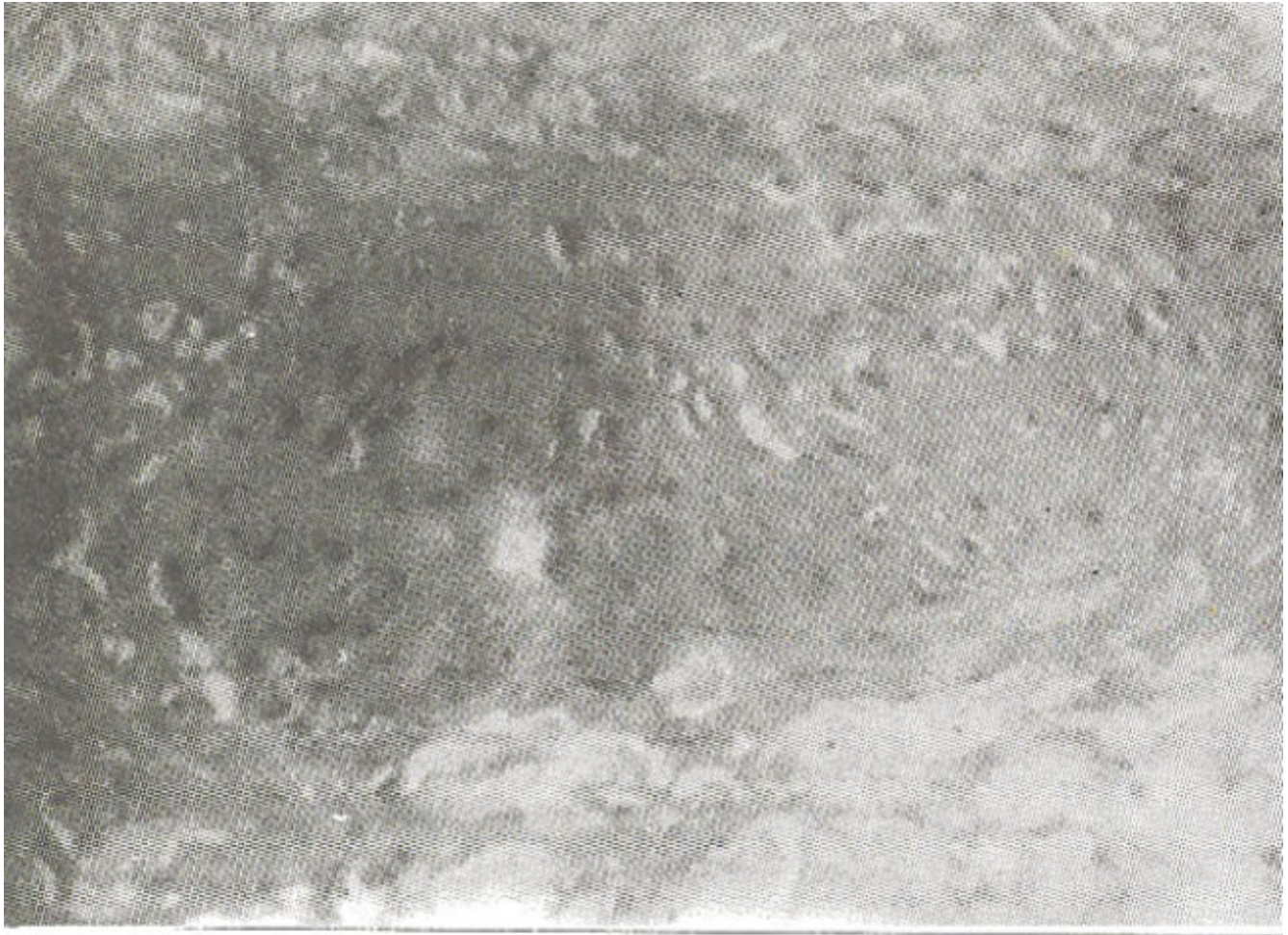


Figure 2. Epithelioid granulomas in the expectorated material (low power view). composed of epithelioid cells admixed with few lymphocytes and occasional multinucleated giant cells (Figure 3).





**Figure 3. Epithelioid granuloma (high power view).**

Periodic acid Schiff stain was negative for fungi and Ziehl-Neelsen stain was negative for acid fast bacilli. His symptoms returned after three weeks while on bronchodilators. He again expectorated a small piece of similar material which revealed necrotic tissue on histopathologic examination. Computerized Axial Tomographic (CAT) scan of the chest was performed to look for any parenchyma damage but no lesion was seen.

Fiberoptic bronchoscopy under L.A. showed partial obstruction of the left main stem bronchus and total obstruction of the left upper lobe bronchus by necrotic tissue. The wall of the left upper bronchus was completely collapsed. Bronchiolavage was done and biopsy obtained. A biopsy of the left upper lobe showed necrotic material and bronchial washing for AFB smear was negative. A post-bronchoscopic sputum sample smear was, however, loaded with AFB. This was later confirmed by microbial culture which yielded mycobacterium tuberculosis.

The patient was started on INH, Rifampacin, Etbambutol and Pyrazinamide. He is asymptomatic on these medications and has stopped coughing. No further expectoration of necrotic material has occurred since six months.

## **Discussion**

Endobronchial tuberculosis can be seen in both primary as well as post-primary tuberculosis<sup>1</sup>. Because of its location and the fact that it can present without any abnormality on chest x-ray, it constitutes a definite diagnostic problem<sup>2</sup>. A shift in age distribution, from younger to older age group after the

advent of effective anti-tuberculosis chemotherapy<sup>3</sup>, in western countries adds another dimension of difficulty for the physicians in diagnosing this disease.

Although, many cases of endobronchial tuberculosis have been reported over the years, coughing tip of a piece of bronchial cartilage has not been reported. A medline search did not uncover any reported case in the last 30 years. In adults bronchial lesions are most commonly secondary to repeated implantation of tubercle bacilli from an adjacent parenchymal source. On rare occasions small portions of bronchial wall may be sloughed off.

Early diagnosis of endobronchial tuberculosis is of paramount importance keeping in mind the fact that serious complications or even death may result due to missed or delayed diagnosis<sup>4</sup>. Diagnosis is usually delayed because endobronchial tuberculosis can masquerade as different disease. It can present as obstructive airway disease<sup>2,5</sup>. In elderly patients, it can simulate lung cancer especially on visual appearance at bronchoscopy<sup>6</sup>. A chest X-ray showing unilateral obstructive emphysema may also be a presenting feature<sup>7</sup>.

Traditional methods like chest X-ray and sputum tests for acid fast bacilli employed in the diagnosis of pulmonary tuberculosis may not be very helpful as endobronchial tuberculosis may be present in the absence of chest X-ray abnormality and a negative AFB smear<sup>8</sup>. It has been shown that sputum AFB smear may be negative in 85% of cases of endobronchial tuberculosis<sup>3</sup>. Although in our case the simple sputum test clinched the diagnosis.

Fiberoptic bronchoscopy has proved to be a very useful procedure not only from the diagnostic point of view but also by virtue of its value in disease management and follow-up<sup>5</sup>. However, in our case, the histopathologic studies of bronchoscopic biopsy did not reveal any acid fast bacilli and bronchial washing was also negative for acid fast bacilli. Bronchoscopy has been shown to relieve atelectasis with improved success of treatment with anti-tuberculosis drugs<sup>9</sup>. It can also be used to evaluate the response of endobronchial tuberculosis to medications<sup>10</sup>. CT scan can also be employed to assess the degree of endobronchial involvement<sup>2</sup>. In our case CT scan was, however, normal.

Treatment consists of the standard anti-tuberculosis drugs, which generally give good results<sup>10,11,13</sup>. There is no documented role of corticosteroids in the treatment of endobronchial tuberculosis<sup>12</sup>.

The most common complication of endobronchial tuberculosis is residual bronchostenosis which can occur despite proper anti-tuberculosis chemotherapy<sup>4,11</sup>. It has been reported that some degree of bronchial stenosis is present in greater than 90% of patients with endobronchial tuberculosis<sup>14</sup>. In some cases stenosis can be severe and may require surgical treatment<sup>11</sup>. Surgical treatment consists of sleeve resection of the bronchus and lobectomies<sup>11,15</sup>. Other forms of treatment for bronchial stenosis secondary to endobronchial tuberculosis include balloon dilatation and laser photoresection<sup>2</sup>. A case has been reported which was successfully treated with self expanding metallic stent<sup>14</sup>.

The value of careful sputum study for acid fast bacilli is probably under stress. In a country like ours, with non-availability of bronchoscopic facility at most institutions, the need for cost effective tests cannot be over emphasized. Pulmonary tuberculosis is very common in our daily practice, all we need to do is look for more patients with endobronchial tuberculosis and help prevent major complications.

## References

1. Smith, L.S. and Schillaci, R.F. Endobronchial tuberculosis - serial fiberoptic bronchoscopy and natural history. *Chest*, 1987;91:644-7.
2. Khan. J.A., Islam, N., Akhter, J. et al. Endobronchial tuberculosis simulating bronchial asthma. *J. Pak. Med. Assoc.*, 1994;44:49-50.

3. Mary, S.M, Lam, W.K. and Mok, C.K. Endobronchial tuberculosis revisited. *Chest*, 1986;89:727-30.
4. Chang, S.C., Lee, P.Y., Perng, R.P. The value of roentgenographic and fibero bronchoscopic findings in predicting outcome of adults with lower lung field, T.B. *Arch. Intern. Med.*, 1991;151:1581-83.
5. Abdulla, F and Dietrich, K.A. Endobronchial tuberculosis manifested as obstructive airway disease in a 4 months old infant. *South Med. J.*, 1990;83: 715-17.
6. Van-Den, B.P., Lamberechts, M., Tack, J. et al. Endobronchial tuberculosis mimicking lung cancer in elderly patients. *Respir. Med.*. 1991 ;85:107-9.
7. Wood, G.S., Gonzalez, C., Done, S. et al., Endobronchial tuberculosis in children. A case report and review, *Int. J Pediatr Otorhinolaryngol.*, 1990;20:241-45.
8. Teo, S.K. Endobronchial tuberculosis. A case report of 5 cases. *Singapore Med. J.*, 1990;31:447-50.
9. Lee, J.H., Park, S.S., Lee, D.H. et al. Endobronchial tuberculosis - Clinical and bronchoscopic features in 121 cases *Chest*, 1992;102:990-4.
10. Kim, Y.fl., Kim, H.T., Lee, KS. et al. Serial fiberoptic observations of endobronchial tuberculosis before and early after anti-tuberculosis chemotherapy. *Chest*, 1993;103:673-7.
11. Tse, C.Y. and Natkunam, R. Serious sequelae of delayed diagnosis of endobronchial tuberculosis. *Tubercle*, 1988,69 213-16.
12. Chan, H.S., Sun. A. and Hoheisel, GB. Endobronchial tuberculosis - Is corticosteroid treatment useful? A report of 8 cases and review of literature. *Postgrad. Med. J.*, 1990;66:822-6.
13. Van, D., Brande, P.M., Van-De, M.F. et al. Clinical spectrum of endobronchial tuberculosis in elderly patients. *Arch. Intern Med.*, 1990;150:2105-8.
14. Han, J.K., Im. JO., Park, J.H. et al. Bronchial stenosis due to endobronchial tuberculosis. Successful treatment with self expanding metallic stent (AiR) *Am. J. Roentgenol.*. 1992;159:971-2.
15. Watanabe, Y., Murakami, S. and Iwa, T Bronchial stricture due to endobronchial tuberculosis. *Thorac. Cardiovaac Surg.*, 1988;36:27-32.