



THE AGA KHAN UNIVERSITY

eCommons@AKU

Section of Orthopaedic Surgery

Department of Surgery

July 2005

Delayed supramalleolar flap--an innovative technique for enhanced viability

Kamran Ahmed

Aga Khan University, kamran.ahmed@aku.edu

Pervaiz Hashmi

Aga Khan University, pervaiz.hashmi@aku.edu

Follow this and additional works at: https://ecommons.aku.edu/pakistan_fhs_mc_surg_orthop

Recommended Citation

Ahmed, K., Hashmi, P. (2005). Delayed supramalleolar flap--an innovative technique for enhanced viability. *Journal of Ayub Medical College, Abbottabad*, 17(3), 76-79.

Available at: https://ecommons.aku.edu/pakistan_fhs_mc_surg_orthop/88

See discussions, stats, and author profiles for this publication at: <https://www.researchgate.net/publication/7447884>

Delayed supramalleolar flap--an innovative technique for enhanced viability

Article in *Journal of Ayub Medical College, Abbottabad: JAMC* · July 2005

Source: PubMed

CITATIONS

3

READS

60

2 authors:



Syed Kamran Ahmed

Indus Hospital

19 PUBLICATIONS 46 CITATIONS

[SEE PROFILE](#)



Pervaiz Hashmi

Aga Khan University Hospital, Karachi

32 PUBLICATIONS 109 CITATIONS

[SEE PROFILE](#)

Some of the authors of this publication are also working on these related projects:



intra articular scapular fracture [View project](#)

CASE SERIES

DELAYED SUPRAMALLEOLAR FLAP – AN INNOVATIVE TECHNIQUE FOR ENHANCED VIABILITY

Syed Kamran Ahmed, Pervaiz Mehmood Hashmi,

Division of Orthopaedics, Department of Surgery, The Aga Khan University Hospital, Karachi, Pakistan.

Background: Delaying flap rotation for 48 to 72 hours leads to opening of choke anastomotic vessels linking adjacent vascular territories. This mechanism enhances flap circulation. Lateral supramalleolar flap with larger dimensions or vascular variations can potentially have survival problems. The purpose of this study is to assess the outcome of delayed lateral supramalleolar flap. **Methods:** This descriptive case series was conducted at Aga Khan University Hospital, Karachi from May 1999 to December 2004. Eight cases of delayed lateral supramalleolar flap were identified through medical records maintained through Health Information Management Systems (HIMS). A detailed questionnaire was developed addressing variables of interest. **Results:** Eight patients required flap delay for 48 hours out of 25 patients, who underwent lateral supramalleolar flap for coverage of foot and ankle soft tissue defects. There were six male (75%) and two female (25%) patients with average age of 31.25 years ranging from 5-52. The reasons for delaying lateral supramalleolar flap were larger flap dimension in four (50%), absent peroneal artery perforator in three (37.5%) and one patient (12.5%) had poor circulation in immediate postoperative period. All the patients required two stage procedure and had excellent coverage of defects. No flap failure occurred subsequent to the delay procedure. **Conclusions:** Flap delay enhanced survival and extended the viable dimensions of lateral supramalleolar flap. Compromised circulation in larger flaps and flaps with vascular variations can be improved by delaying flap transfer to the recipient site for 48 hours following its elevation.

Keywords: Delayed flap, Lateral supramalleolar flap, Foot and ankle soft tissue defects.

INTRODUCTION

Lateral supramalleolar flap is based on the perforating branch of peroneal artery. The peroneal artery runs in the flexor hallucis longus muscle in posterior compartment; it enters the anterior compartment of leg by piercing the interosseous membrane between tibia and fibula 5-7 cm above the ankle joint. At its emergence, the perforating branch of the artery gives a relatively constant skin perforator which supplies a large area on the lateral aspect of distal 1/3 of leg. This supramalleolar flap is based on this branch. Yoshimura¹ was first to describe the proximally and distally based peroneal island flap in 1985 based on sacrifice of peroneal artery. Masquelet² in 1988 described the lateral supramalleolar fasciocutaneous flap based on cadaveric and patient study. Without compromise to the major blood vessels of the foot including the peroneal artery, this flap has proved to be a reliable fasciocutaneous flap for the loco regional coverage of distal third of the leg, ankle, perimalleolar region, dorsum and plantar aspect of foot,²⁻⁵ except weight bearing region of heel,³⁻⁶ as the flap is insensate and relatively thin. The pedicle of the flap is long (8.0 cm in rotation flaps² to 15 cm in distally based flaps with compound pedicle)⁴ and the pivot point of pedicle is sinus tarsi which increases the arc of rotation. The flap is most commonly employed as distally based

pedicle island flap. The potential problems of the flap² include some amount of venous congestion in reversed island flaps and anatomic vascular variations.^{2,7,8} The usefulness of lateral supramalleolar flap has been demonstrated by its use as a delay flap for tendoachilles⁹ coverage in difficult situations like Werner's syndrome, coverage of ischemic ulcer in Buerger's disease,⁷ and limb reconstruction.⁸

Certain anatomic variations of the flap include the inconstant but frequent presence of a proximal inferolateral collateral artery,⁷ presence of the anterior peroneal artery, presence of a vascular network instead of a well defined artery, absence of perforating branch of the peroneal artery⁷ and the basis of cutaneous circulation solely on anterior tibial perforators.

Flap delay has evolved over years subsequent to better understanding of vascular anatomy of flaps.^{10,11} The application of surgical delay in flap surgery is multifold. It can be used to define the survival length of an unknown flap, to improve circulation in a known flap or to increase the viable length of a known flap by strategic division of vessels along the flap axis. There is accelerated rate of 'choke' vessel dilatation by 48 to 72 hours following elevation of flap^{12,13} from the donor area due to multiple factors. Shear stress, physical effect

of blood flow,¹⁴ vascular endothelial relaxing factors like nitric oxide, prostacyclin and endothelium derived hyperpolarizing factor¹⁵ seem to play a role. There is hypertrophy and hyperplasia of the vessel wall leading to increase in the diameter of the existing choke vessels and the microvascular bed of the flap, shown to be a permanent effect in experimental trials, without any increase in new vessel formation.^{12,13} Experimental and clinical trials show almost double surface area of flap viability if surgical delay is combined with intraarterial vascular endothelial growth factor (VEGF). It has been shown to be 99.6 percent if surgical delay is combined with intraarterial VEGF. If flap delay or other intervention is not done, it is 50 percent. It is 83 percent, if only surgical delay is applied, 90.6 percent, if intraarterial VEGF alone is used and 87 percent, if intramuscular VEGF is used.¹⁶ Therefore judicious use of surgical delay alone can lead to enhanced flap survival.^{12,16-18} The practical application of this phenomenon was demonstrated by delaying lateral supramalleolar flap in difficult situations like Werner's syndrome.¹⁹ Keeping this concept in view, we studied the phenomenon of delay flap in patients who underwent lateral supramalleolar flap for soft tissue coverage of defects around the foot and ankle region.

MATERIAL AND METHODS

This descriptive case series conducted between May 1999 to December 2004, at Aga Khan University Hospital, Karachi. It is a tertiary care center for microsurgery cases with expertise available by virtue of experienced microsurgeons in the section of Orthopaedics, Department of Surgery. Cases of lateral supramalleolar flap were identified through medical records maintained in Health Information Management Systems (HIMS). One surgeon operated all the patients and loupe magnification was used in all cases. No preoperative Doppler or angiography was done to assess the status of vascular pattern of the flap. All benefits and disadvantages of the operation were discussed in detail with the patients before operation. A detailed questionnaire was developed addressing the variables of interest.

RESULTS

Eight patients required flap delay for 48 hours before rotation to the recipient site out of 25 patients, who underwent lateral supramalleolar flap for coverage of soft tissue defects around the foot and ankle. There were six male and two female patients with average age of 31.25 years ranging from 5-52. There were two cases of each with road traffic accident; spoke wheel injury and pressure sore and one case each of neuropathic ulcer and bomb blast injury. Three patients had soft tissue defects over the dorsum of

foot and ankle, three had around heel and tendoachillus and two had over the plantar aspect of foot. The average size of flap was 13.5cm long and 7cm wide ranging from 8cm to 20cm in length and 6cm to 11cm in breadth. Five flaps were raised as retrograde and three as antgrade.

In our series, four elective flap delay was performed due to larger flap dimensions (more than 14cm in length), leading to delayed appearance of distal circulation of the flap. In one case, the flap needed to be placed back on the donor bed in immediate postoperative period due to poor perfusion. In three cases, per-operative evidence of absent peroneal perforator and decreased distal perfusion led to the decision of flap delay. Interesting to note is the association of absent peroneal artery perforator in three cases, flap being raised on ante-grade skin circulation from inferolateral collateral artery, branch of anterior tibial artery.

In short the decision to delay flap rotation was per-operative in seven patients and immediate postoperative in one patient. Successful rotation to the recipient bed was performed after 48 hours in all cases. No flap necrosis, infection or failure was encountered. The donor site was covered by split thickness graft in all cases.

Case Example: Case- 1 a 48 years male presented with soft tissue and bony defect over the dorsolateral and plantar aspect of right foot as a result of bomb blast injury (Fig. 1.a & b). The flap size elevated was 20x8 cm. As the distal perfusion was sluggish on flap elevation, therefore flap delay was done for 48 hours (Fig. 2). After rotation, excellent final outcome was obtained (Fig.3).

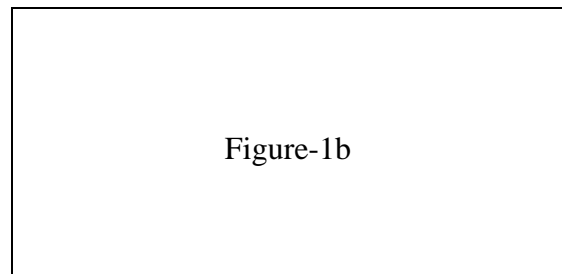



Fig.1-a & 1.b: Soft tissue and bony defect on the dorsolateral and plantar aspect of the right foot as a result of bomb blast injury.

Figure-2

Figure-3

Fig- 2: After elevation, lateral supramalleolar flap sutured back on donor bed to be delayed for 48 hours.

Fig-3: Late clinical follow up at six months.

Table-1: Demographic features, mechanism, defect size and site, flap pattern, vascular anomaly and outcome of delayed flap

No.	Sex	Age	Skin defect	Injury	Flap dimensions (cm)	Pattern of flap	Vascular variation	Reason for delay	Results
01	M	48	Dorsum of Right foot lateral and plantar aspect	Bomb blast Injury	20 X 8	Retrograde pedicle island	Nil	Larger flap dimension & poor circulation	Complete survival
02	F	48	Left tendo achilles	Pressure sore in cast after fixation of calcaneum	9 X 6	Retrograde pedicle island	Nil	Poor immediate postoperative circulation	Complete survival
03	M	52	Left heel	Pressure sore, bed bound due to traction for hip dislocation	8 X 6	Antegrade pedicle island	No Peroneal artery perforator, based on inferolateral collateral artery	Absent perforator	Complete survival
04	M	34	Dorsum of Left foot	Road Traffic Accident	17 X 11	Retrograde pedicle island	Nil	Larger flap dimension	Complete survival
05	M	5	Lateral aspect of left heel	Spoke wheel injury	10 X 6	Peninsular rotation	No peroneal artery perforator, based on inferolateral collateral artery	Absent perforator	Complete survival
06	F	6	Plantar skin avulsion from bases of toes to tendo achilles	Spoke wheel injury	14 x 7	Retrograde pedicle island	Nil	Larger flap dimension	Complete survival
07	M	12	Dorsum of ankle and lateral malleolus	Road Traffic Accident	10 x 6	Antegrade pedicle island	No Peroneal artery perforator, based on inferolateral collateral artery	Absent perforator	Complete survival
08	M	45	Diabetic Ulcer over planter aspect of foot	Neuropathic Ulcer	20 x 7	Retrograde pedicle island	Nil	Larger flap dimension And diabetic patient	Complete survival

DISCUSSION

Delay flap as a surgical entity has been well studied in experimental trials but in limited clinical studies. Apart from a case report of lateral supramalleolar flap use in Werner's syndrome, no other data of delay flap is available to compare with our results.^{12,17,20}

The largest flap size of lateral supramalleolar flap reported in previous clinical series was 15×8 cm.^{2,5} In dye injection studies in fresh cadavers, maximum stainable area was 22×9 cm.⁸ Four cases in our series, (number 1, 4, 6 and 8) had flap dimensions larger than cited above. This may be the principal factor leading to delayed appearance of circulation. Vascular abnormality was present in three out of eight cases, which may also be the contributing factor.

The use of surgical delay has been advocated in sural artery flap where poor venous return is anticipated due to absence of lesser saphenous vein in multimorbid patients.²⁰

A similar phenomenon was demonstrated in experimental neurovascular island skin flap. Denervation alone leaving the blood supply intact or devascularization leaving nerve supply intact lead to increased flap survival.²¹ The only large clinical series of delay flap is done for TRAM flap in 76 consecutive cases.¹⁷

Experimental trials have shown choke vessel dilatation as a permanent and irreversible event. The process is also similar for different species and different tissues suggesting universal application for the process in difficult situations.

Based on our observations it is recommended to delay the lateral supramalleolar flap for 48 hours if a vascular variation is encountered or a flap of larger dimension is harvested. Peroperative assessment of the flap circulation at the end of surgery as well as in the immediate post operative period is necessary to pick up circulatory problems.

Although flap delay makes the procedure two stages, the end result is much more reliable and encouraging.

REFERENCES

1. Yoshimura M, Shimada T, Imura S, Shimamura K, Yamauchi S. Peroneal island flap for skin defects in the lower extremity. *J Bone Joint Surg Am* 1985;67(6):935-41.
2. Masquelet AC, Beveridge J, Romana C, Gerber C. The lateral supramalleolar flap. *Plast Reconstr Surg* 1988;81(1):74-81.
3. Leung PC, Hung LK, Leung KS. Use of the medial plantar flap in soft tissue replacement around the heel region. *Foot Ankle* 1988;8(6):327-30.
4. Menesi L. [The lateral supramalleolar fasciocutaneous flap and its modification]. *Magy Traumatol Ortop Kezseb Plasztikai Seb* 1994;37(4):371-4.
5. Valenti P, Masquelet AC, Romana C, Nordin JY. Technical refinement of the lateral supramalleolar flap. *Br J Plast Surg* 1991;44(6):459-62.
6. Nohira K, Shintomi Y, Sugihara T, Ohura T. Replacing losses in kind: improved sensation following heel reconstruction using the free instep flap. *J Reconstr Microsurg* 1989;5(1):1-6.
7. Saitoh S, Hata Y, Murakami N, Seki H, Kobayashi H, Shimizu T, et al. The 'superficial' peroneal artery: a variation in cutaneous branching from the peroneal artery, nourishing the distal third of the leg. *Br J Plast Surg* 2001;54(5):428-33.
8. Wolff KD. The supramalleolar flap based on septocutaneous perforators from the peroneal vessels for intraoral soft tissue replacement. *Br J Plast Surg* 1993;46(2):151-5.
9. Beveridge J, Masquelet AC, Romana MC, Vinh TS. Anatomic basis of a fascio-cutaneous flap supplied by the perforating branch of the peroneal artery. *Surg Radiol Anat* 1988;10(3):195-9.
10. Cormack GC, Lamberty BG. A classification of fascio-cutaneous flaps according to their patterns of vascularisation. *Br J Plast Surg* 1984;37(1):80-7.
11. Whetzel TP, Barnard MA, Stokes RB. Arterial fasciocutaneous vascular territories of the lower leg. *Plast Reconstr Surg* 1997;100(5):1172-85.
12. Dhar SC, Taylor GI. The delay phenomenon: the story unfolds. *Plast Reconstr Surg* 1999;104(7):2079-91.
13. Morris SF, Taylor GI. The time sequence of the delay phenomenon: when is a surgical delay effective? An experimental study. *Plast Reconstr Surg* 1995;95(3):526-33.
14. Bevan JA. Shear stress, the endothelium and the balance between flow-induced contraction and dilation in animals and man. *Int J Microcirc Clin Exp* 1997;17(5):248-56.
15. JD. C. endothelial regulation of vascular tone. *Hosp Pract* 1994;29:117-26.
16. Seify H, Bilkay U, Jones G. Improvement of TRAM flap viability using human VEGF-induced angiogenesis: a comparative study of delay techniques. *Plast Reconstr Surg* 2003;112(4):1032-9.
17. Erdmann D SB, Moquin KJ, Young H, Georigiade GS. Delay in unpedicled TRAM flap for reconstruction of breast. *Plast Reconstr Surg* 2002;110:762-67.
18. Jensen JA. Tram flap delay: two techniques and an unresolved question. *Plast Reconstr Surg* 2003;111(7):2478-9.
19. Okazaki M, Ueda K, Kuriki K. Lateral supramalleolar flap for heel coverage in a patient with Werner's syndrome. *Ann Plast Surg* 1998;41(3):307-10.
20. Baumeister SP, Spierer R, Erdmann D, Sweis R, Levin LS, Germann GK. A realistic complication analysis of 70 sural artery flaps in a multimorbid patient group. *Plast Reconstr Surg* 2003;112(1):129-40; discussion 141-2.
21. Finseth F, Cutting C. An experimental neurovascular island skin flap for the study of the delay phenomenon. *Plast Reconstr Surg* 1978;61(3):412-20.

Address for Correspondence:

Dr. Pervaiz Mehmood Hashmi, Hand and Microsurgeon, Division of Orthopaedics, Department of Surgery, The Aga Khan University Hospital, P.O.Box 3500, Stadium Road, Karachi, Pakistan. Tel: 92 21 48594751/52; Fax: 92 21 4934294;

E-mail: pervaiz.hashmi@aku.edu