



THE AGA KHAN UNIVERSITY

eCommons@AKU

Section of Cardiothoracic Surgery

Department of Surgery

January 2006

Giant multiple intra-abdominal hydatid cysts

Naila Nadeem
Aga Khan University

Hassan Khan
Aga Khan University

Saulat H. Fatimi
Aga Khan University, saulat.fatimi@aku.edu

Mohammad Nadeem Ahmad
Aga Khan University

Follow this and additional works at: https://ecommons.aku.edu/pakistan_fhs_mc_surg_cardiothoracic



Part of the [Surgery Commons](#)

Recommended Citation

Nadeem, N., Khan, H., Fatimi, S., Ahmad, M. (2006). Giant multiple intra-abdominal hydatid cysts. *Journal of Ayub Medical College*, 18(4), 70-71.

Available at: https://ecommons.aku.edu/pakistan_fhs_mc_surg_cardiothoracic/84

CASE REPORT

GIANT MULTIPLE INTRA-ABDOMINAL HYDATID CYSTS

Naila Nadeem, Hassan Khan*, Saulat Fatimi, Mohammad Nadeem Ahmad**
 The Aga Khan University, Karachi, Pakistan.

INTRODUCTION

Hydatid disease is endemic in the cattle grazing areas particularly Australia, New-Zealand, Middle East, India, Africa, South America and Turkey ¹. It is a parasitic infection caused by the cestode tapeworm *Echinococcus granulosus*. The dogs are the definitive host and the adult worms are found in their small intestine. Humans get infected either by contact with the definitive host or by consuming vegetables and water contaminated with the hydatid ova ². In humans the hydatid disease commonly involves the liver (75%) and the lungs (15%). The remaining (10-15%) of the cases include the other regions of the body ¹. The disseminated intra-peritoneal hydatid disease is a very rare finding ¹. We report such a presentation wherein the abdominal cavity is seen to contain multiple hydatid cysts.

CASE REPORT

A 42 yr old lady presented with shortness of breath on exertion, orthopnea and progressively increasing abdominal distention. She had past history of hydatid disease and had three laparotomies and a right thoracotomy, in the past five years. On physical examination, she was an extremely thin woman with a large protruding abdomen. Her abdomen was distended but nontender. Her vital signs were- pulse of 92/minute, Blood pressure was 95/60 mmHg, Respiratory rate of 24/min and temperature of 37 degrees centigrade. She had decreased breath sounds in both lower lung fields. Rest of the physical examination was unremarkable. Her routine laboratory investigations were normal. Echinococcus antibody titres were 1:64 (Normal 1:32). The CT (Computed Tomography) scan revealed multiple, well defined cysts throughout the abdomen. A few cysts showed septae and daughter cysts. These cysts were producing a pressure affect on surrounding structures but not invading them. Appearance is consistent with multiple hydatid cysts

She was offered another laparotomy and right thoracotomy but the patient refused to undergo any further surgical procedure. She was discharged from the clinic with a prescription of Albendazole 400 mg twice a day for an indefinite period. The patient never returned for follow up later.

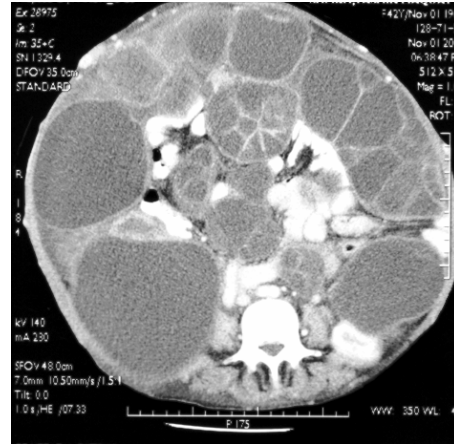


Figure 1 A “wheel spoke” pattern can be observed as he daughter cysts are separated by hydatid matrix

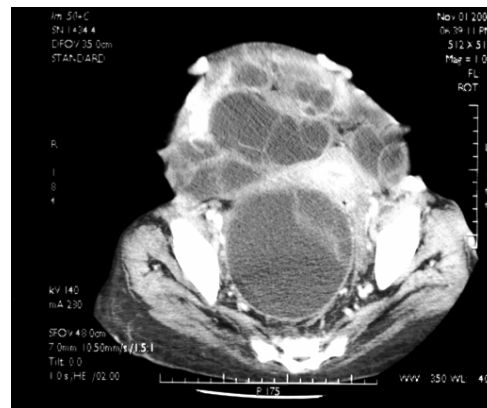

Figure 2 Enhanced CT of the Abdomen. Multiple well defined mesenteric cysts with septae

DISCUSSION

The close association of people with sheep and dogs and the in availability of clean potable water supplies in Pakistan make it a region endemic to the disease. Majority of the cases of hydatid disease seen come from rural areas or people who have settled in urban centers after spending life in villages. Most of the people acquire the disease during their childhood but do not present with the clinical signs and symptoms until late adult hood ¹. The natural progression of an untreated cyst may include calcification and death of the cyst, however more frequently the cyst gradually enlarges ³. The case we present typically highlights the features of intra abdominal cysts in reference to the radiological imaging.

The liver and lung are the commonest sites of involvement, although no site in the body may be completely immune from it⁴. These atypical and rare presentations of the disease may be seen in kidneys (3%), usually the upper and the lower pole of the kidney may be involved². The spleen may be involved in about (4%) of the cases and is associated with splenomegaly, fever and abdominal pain⁴. Cerebral Hydatid cysts occur in only 2% of all the cases reported. The region of the middle cerebral artery distribution specially the parietal lobe is most frequently involved.⁴ Cardiac hydatid disease is very rare (0.02%–2% of cases) and most commonly affects the left cardiac chamber especially the left ventricle in (50%–60%) of cases.⁴ The other sites that have been reported to be involved are bones, pancreas, breast, ovaries, scrotum, thyroid gland, inguinal canal and soft tissues^{2,4}.

Hydatid cysts can also be found rarely in the peritoneum.¹ Most of these cases are the result of traumatic or surgical rupture of a hepatic, splenic, or mesenteric cyst.⁵ The prevalence of peritoneal hydatid cysts in cases of abdominal Hydatid disease is approximately 13%. In our case the patient had already undergone three laparotomies and it is likely that these findings may be associated to previous surgical rupture, although spontaneous rupture of micro cysts into the peritoneum may also occur in about 12% of the cases.¹ The hydatid cysts may resemble a multiloculated mass filling the entire peritoneal cavity. Such a condition is referred to as peritoneal hydatidosis.¹

Hydatid cyst may be solitary or multiple. The type of the imaging modality used depends on the site and the size of the hydatid cyst. Ultrasonography (USG) is the first line of screening for abdominal hydatidosis and it is especially useful for detection of cystic membrane, septa, and hydatid sand. CT scan best demonstrates cyst wall calcification and cyst infection. CT scan imaging is also the modality of choice in peritoneal seedling.¹

The CT scan shows well defined solitary or multiple cysts that may be thin walled or thick walled. A hydatid cyst typically demonstrates a high-attenuation value at unenhanced CT even without calcification (Figure 1). Multivesicular cysts can depict a typical honeycomb pattern.¹ The septa represent the walls of the daughter cysts housed within the mother cyst. A “wheel spoke” pattern can be observed when the daughter cysts are separated by hydatid matrix¹.

There are different types of serological tests which can be carried out for the diagnosis, screening and follow up of patients with hydatid disease. These

include the immunoelectrophoresis, enzyme-linked immunosorbent assay (ELISA), latex agglutination and indirect haemagglutination (IHA) test⁴. The diagnosis of HD can thus be established with the help of radiologic and serologic findings⁴. The diagnosis is also easier when the lesion has multiple locations involving different organs or when daughter cysts, germinal membrane detachment and calcification are present².

Surgery is the mainstay of treatment for hydatid cysts of the liver. Laparotomy is the most common surgical approach⁷. Liver resection and pericystectomy are procedures that resect the closed cysts with a wide safety margin, however they are considered too radical procedures for hydatid cyst removal. Conservative procedures such as cystectomy and omentoplasty for hydatid disease should be the standard surgical procedure because of their safety, simplicity, and effectiveness in fulfilling the surgical treatment criteria of hydatid disease⁷. The peritoneal hydatidosis has also been successfully surgically removed with similar conservative procedures^{5,8}.

In conclusion, symptomatic or large cysts should be surgically treated. In cases suspected of having peritoneal spillage, antihelminthic drugs should be administered⁹. In addition, small asymptomatic cysts, some daughter cysts, and peritoneal secondary cysts and splenic cysts may also be effectively treated with Albendazole⁹.

REFERENCES

1. Pedrosa I, Saiz A, Arrazola J, Ferreiros J, Pedrosa CS. Hydatid disease: radiologic and pathologic features and complications. *Radiographics* 2000; 3:795-817.
2. Polat P, Kantarci M, Alper F, Suma S, Koruyucu MB, Okur A. Hydatid Disease from Head to Toe. *Radiographics* 2003; 23:475-94.
3. Ammann RW, Eckert J. Cestodes. *Echinococcus*. *Gastroenterol Clin North Am* 1996; 3:655-89.
4. Husen YA, Nadeem N, Aslam F, Bhaila I. Primary splenic hydatid cyst: a case report with characteristic imaging appearance. *J Pak Med Assoc* 2005; 5:219-21
5. Karavias DD, Vagianos CE, Kakkos SK, Panagopoulos CM, Androulakis JA. Peritoneal echinococcosis. *World J Surg* 1996; 20:337-40.
6. Kune GA, Morris DI. Hydatid disease In: Schwasyz & Ellis, eds. *Maingot's Abdominal Operations*, 9th edn. Appleton & Lange 1989; 1225-40.
7. Buttenschoen K, Carli Buttenschoen D. *Echinococcus granulosus* infection: the challenge of surgical treatment. *Langenbecks Arch Surg* 2003; 4:218-30.
8. Hamamci EO, Besim H, Korkmaz A. Unusual locations of hydatid disease and surgical approach. *ANZ J Surg* 2004; 5:356-60
9. Balik AA, Celebi F, Basglu M, Oren D, Yildirgan I, Atamanalp SS. Intra-abdominal extrahepatic echinococcosis. *Surg Today* 2001; 10:881-4.