



THE AGA KHAN UNIVERSITY

eCommons@AKU

Department of Radiology

Medical College, Pakistan

December 2010

CONCOMITANT GASTRIC AND LUNG UPTAKE OF TC-99M MDP ON BONE SCAN IN A PATIENT WITH DIFFUSE LARGE B-CELL NON-HODGKIN'S LYMPHOMA

Maseeh uz Zaman
Aga Khan University

Riffat Hussain Riffat Hussain
Aga Khan University

Zafar Sajjad
Aga Khan University

Mansoor Naqvi Mansoor Naqvi
Aga Khan University

Khalil Khan
Aga Khan University

See next page for additional authors

Follow this and additional works at: https://ecommons.aku.edu/pakistan_fhs_mc_radiol

 Part of the [Radiology Commons](#)

Recommended Citation

Zaman, M. u., Riffat Hussain, R., Sajjad, Z., Mansoor Naqvi, M., Khan, K., Khan, G., Pirani, Z. (2010). CONCOMITANT GASTRIC AND LUNG UPTAKE OF TC-99M MDP ON BONE SCAN IN A PATIENT WITH DIFFUSE LARGE B-CELL NON-HODGKIN'S LYMPHOMA. *pakistan journal of radiology*, 20(4), 171-173.

Available at: https://ecommons.aku.edu/pakistan_fhs_mc_radiol/80

Authors

Maseeh uz Zaman, Riffat Hussain Riffat Hussain, Zafar Sajjad, Mansoor Naqvi Mansoor Naqvi, Khalil Khan, Gufran Khan, and Zohra i Pirani

CONCOMITANT GASTRIC AND LUNG UPTAKE OF TC-99M MDP ON BONE SCAN IN A PATIENT WITH DIFFUSE LARGE B-CELL NON-HODGKIN'S LYMPHOMA

Maseeh uz Zaman, Riffat Hussain, Zafar Sajjad, Mansoor Naqvi, Khalil Khan, Gufran Khan, Zohra Pirani

Nuclear Medicine Section, Department of Radiology, Aga Khan University Hospital, Karachi, Pakistan.

PJR October - December 2010; 20(4): 171-173

ABSTRACT

Extra osseous uptake of Tc-99m Methylene Di Phosphonate (MDP) is not an uncommon finding on skeletal scintigraphy. However, concomitant lung and gastric uptake is a rare presentation. We presented a case report of a young male whose bone scan revealed lung and stomach uptake with a cold lesion over T7 vertebra. CT guided biopsy revealed diffuse large B-cell Non-Hodgkin's lymphoma. Lung and gastric uptake of Tc-99m MDP on bone scan guides the reporting physician about the soft tissue calcinosis due to hypercalcemia associated with either malignant or non-malignant conditions.

Case Report

Bone scintigraphy using Technetium-99m Methylene Diphosphonate (Tc-99m MDP) is a commonly used procedure in every nuclear medicine department. Normal sites of soft tissue tracer uptake on bone imaging are kidneys and urinary bladder. Abnormal extra-osseous localization of MDP is not an uncommon finding and most commonly lungs are the primary sites.¹ The underlying mechanism is micro calcification in soft tissue secondary to abnormality in calcium metabolism resulting in hypercalcaemia and associated renal failure in most of cases.² Simultaneous uptake over multiple sites like lungs and stomach is fairly uncommon and associated with malignant (breast and bladder cancers, multiple myeloma and Hodgkin's disease)³ and non-malignant conditions like parathyroid adenoma, Vit-D intoxication or Paget's disease.⁴ We present a case report of a bone scan with abnormal lung and gastric uptake of Tc-99m MDP in a patient with Diffuse Large B Cell Non-Hodgkin's Lymphoma (DLBCL according to WHO classification).

Correspondence : Dr. Maseeh uz Zaman
Section of Nuclear Physician, Dept. of Radiology
Aga Khan University Hospital,
Stadium Road, P.O. Box 3500, Karachi 74800
Pakistan. Tel. No: 34930051 - Ext. 2020
maseeh.uzzaman@aku.edu

Clinical Data

This is a 25 year old man who was admitted through emergency room with history of progressive weight loss, fever, paraparesis and altered consciousness. His past history was unremarkable and he was a chain smoker and farmer by profession. On examination he had a thin skinny look with sunken eyes and his temperature was 101°F and other vitals were normal. His chest had a harsh vesicular breathing, abdomen was soft and non-tender and his lower limbs had marked motor weakness. His investigations revealed hemoglobin 7 gm/dl, total leucocytes counts 16000/mm³ (with neutrophilic shift) and ESR 40 mm 1st hr. His biochemistry revealed a blood urea nitrogen 89 mg/dl (normal 6-20), creatinine 3.4 mg/dl (normal 0.9-1.3), calcium 15.3 mg/dl (normal 8.4-10.2), phosphate 6.1 mg/dl (normal 2.5-4.6), total protein 5.3 g/dl (normal 6.7-8.2) and albumin 2.21 g/dl (normal 3.2-5.5) with a A/G ration of 0.72 (normal 1.1-2.4). His serum parathormone level was normal and Vit D level was 12.1 ng/ml (low). Ultrasound abdomen revealed bilateral renal parenchymal disease and CSF examination revealed markedly elevated protein (1014 mg/dl),

normal glucose with no malignant cell. X-ray chest (Fig. 1) showed ill defined consolidation involving left upper lung, blunted bilateral costophrenic angles and no evidence of parenchymal calcification. His MRI (Fig.2)

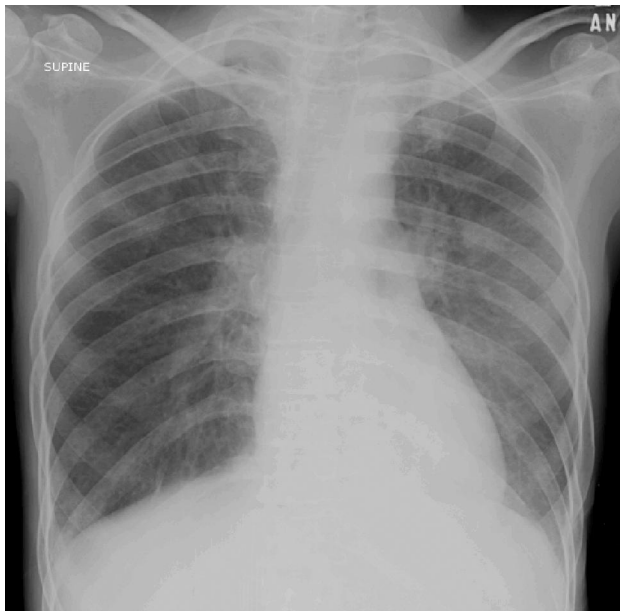


Figure 1: Chest X-ray (PA view): shows an ill defined consolidation involving left upper lung, blunted bilateral costophrenic angles and no evidence of parenchymal calcification

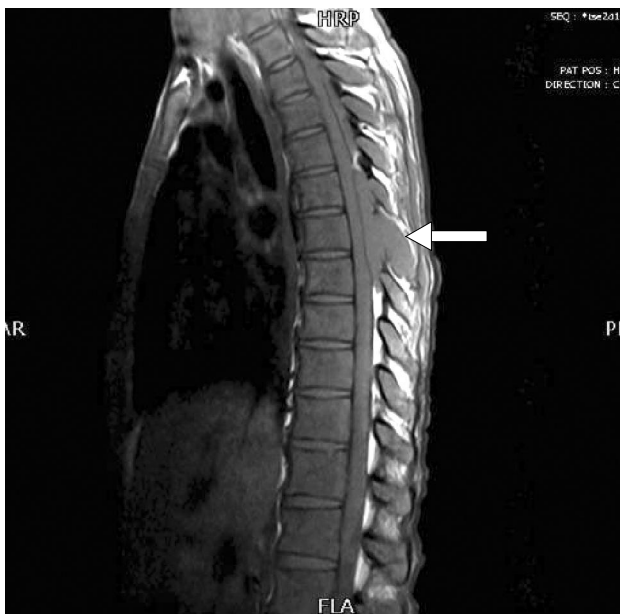

Figure 2: T1 weighted sagittal image (non-contrast) revealing an epidural mass (arrow) extending posteriorly with evidence of cord compression as well.

showed epidural and para-vertebral soft tissue masses at C7-T1, T3-5 and T7-8 levels with contour abnormality of spinal cord and diffuse signal changes within cord substances. Whole body skeletal imaging(Fig.3)

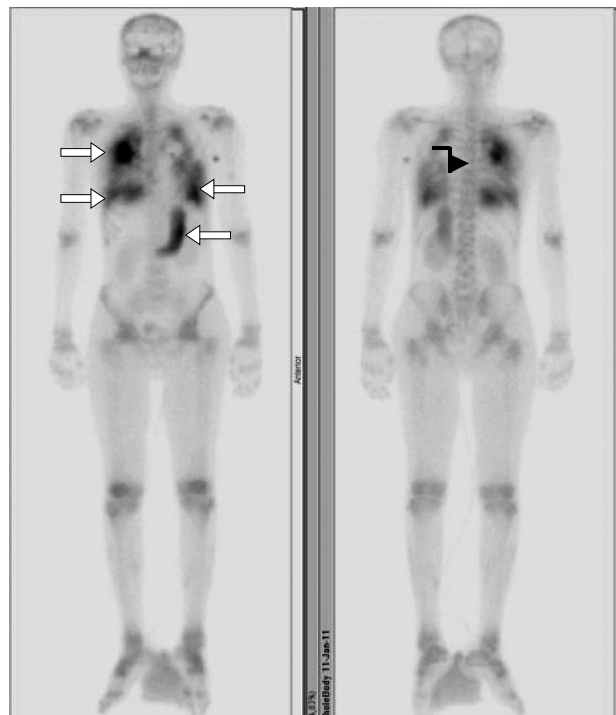

Figure 3: Whole body bone scan (anterior and posterior 3 hr delayed images) showing gastric and bilateral lung uptake (white thick arrows) and an ill-defined photon deficient area (thin black arrow) over T7 region.

performed with 25 mCi of Tc-99m MDP revealed an ill-defined photon deficient area involving the left side of T7 with extra-osseous tracer uptake involving different segments of both lungs, diffuse uptake over stomach and homogenously enhanced uptake over rest of skeleton. CT guided biopsy of para-spinal mass at T7 revealed diffuse large B-cell Non-Hodgkin's lymphoma and bone marrow (trephine) biopsy revealed metastatic infiltration as well.

Discussion

Hypercalcemia has been reported to occur in 20-30% of patients with cancer at some stage during course of disease.⁵ The incidence of hypercalcemia in malignant lymphoma is about 10%.⁶ Hypercalcemia leads to progressive mental impairment and renal

failure. Macrophage inflammatory proteins 1a and 1b (MIP 1a & 1b) and Receptor Activator of Nuclear factor (NF-KappaB) Ligand (RANKL) are over-expressed in NHL⁶ which activate osteoclasts resulting in hypercalcemia. It has a bad prognostic value in patients with malignancy and approximately 50% of patients die within 30 days.⁷ Intense uptake of Tc-99m MDP in soft tissue like lungs and stomach is caused by calcinosis resulting from prolonged hypercalcemia and hyperphosphatemia.¹ The reason of selective pulmonary and gastric appreciable localization of MDP is precipitation of calcium and phosphate at acid-base balance.² False positive uptake of MDP in stomach is caused by sub-optimal preparation (uptake of free pertechnetate) and we have ruled it out by absent thyroid uptake on bone scan and other scans done on same day were not showing abnormal soft tissue uptake too.

Lung and gastric uptake of Tc-99m MDP on bone scan guides the reporting physician about the soft tissue calcinosis due to hypercalcemia associated with either malignant or non-malignant conditions.

lymphoma presenting with hypercalcemia and multiple osteolysis. Informa Healthcare. 2004; **45(2)**: 397-400.

7. Andrew Fs. Hypercalcemia associated with cancer. N Engl J Med. 2005; **352**: 373-9.

References

1. Ayten G, Elly MD, Stephan JLB, Guido AKH, Marinus JPG. Lung and gastric uptake in bone scintigraphy of sarcoidosis. J Nucl Med. 1996; **37**:150-32.
2. Heck LL. Extra osseous localization of phosphate bone agents. Semin Nucl Med. 1980; **10**: 311-3.
3. Jayabalan V, De Witt B. Gastric calcification detected in vivo by Tc-99m pyrophosphate imaging. Clin Nucl Med. 1978; **3**: 27-9.
4. Corstens F, Kerremans A, Claessens R. Resolution of massive Technetium-99m MDP uptake in the stomach in vit D intoxication. J Nucl Med. 1986; **27**: 219-22.
5. Roodman GD. Mechanism of bone metastasis. N Engl J Med. 2004; **350**: 1655-64.
6. Matsushashi Y, Tasaka T, Uehara E, Fujimoto M, Fujita M, Tamura T, et al. Diffuse large B cell