



THE AGA KHAN UNIVERSITY

eCommons@AKU

Section of Neurosurgery

Department of Surgery

January 2004

Patterns of tuberculosis in the central nervous system

Soobia Raza
Aga Khan University

Aliyah Sadaf
Aga Khan University

Faisal Fecto
Aga Khan University

Rushna Pervez Ali
Aga Khan University

Ehsan Bari
Aga Khan University

See next page for additional authors

Follow this and additional works at: http://ecommons.aku.edu/pakistan_fhs_mc_surg_neurosurg



Part of the [Neurology Commons](#)

Recommended Citation

Raza, S., Sadaf, A., Fecto, F., Ali, R., Bari, E., Enam, S. (2004). Patterns of tuberculosis in the central nervous system. *Infectious Diseases Journal of Pakistan*, 99-104.

Available at: http://ecommons.aku.edu/pakistan_fhs_mc_surg_neurosurg/75

Authors

Soobia Raza, Aliyah Sadaf, Faisal Fecto, Rushna Pervez Ali, Ehsan Bari, and S. Ather Enam

Patterns of Tuberculosis in the Central Nervous System

Soobia Raza¹, Aliyah Sadaf¹, Faisal Fecto¹, Rushna Pervez Ali¹, Ehsan Bari², S. Ather Enam²
The Aga Khan University Medical College¹, Section of Neurosurgery², Aga Khan University Hospital, Karachi.

Introduction

Tuberculous involvement of central nervous system (CNS), although not very frequent, results in severe morbidity. Tuberculosis (TB) is endemic in developing countries but even in developed countries, after an initial decline up until 1980's, incidence of TB is on the rise. The AIDS epidemic, emergence of multi-drug resistant strains and immigration of people from endemic areas are some of the factors significantly contributing to this increase. Consequently, the burden of central nervous system tuberculosis has increased significantly worldwide.

Infection of CNS by tuberculosis (TB) can develop in several patterns. The old adage "Syphilis - the Great Masquerader", probably applies to tuberculosis as well when it involves the central nervous system. This poses a constant challenge to the clinicians in making a definitive diagnosis. The various extra-pulmonary manifestations of tuberculosis and the multitude of organs involved complicate the task further. Central nervous system (CNS) tuberculosis forms a significant proportion of extra-pulmonary tuberculosis¹. In most cases, infection is thought to spread hematogenously. Due to a lack of reliable diagnostic tests and due to morbidity inherent in surgical procedures for diagnosis, the decision to treat central nervous system tuberculosis is done empirically in most endemic areas. Thus its purulent to be cognizant of the patterns of CNS infection by TB.

There are four major patterns of CNS TB:

- 1- tuberculous meningitis (TBM)
- 2- tuberculomas in brain and spinal cord (TBT)
- 3- tubercular brain abscess (TBA)
- 4- tuberculous encephalopathy (TBE)

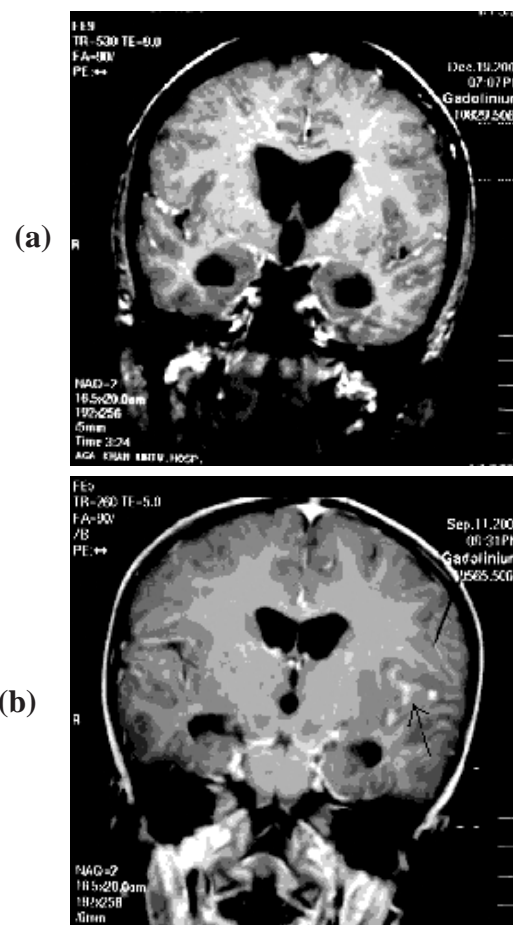
Tuberculous Meningitis

The most common form that tuberculosis takes in the central nervous system is TBM. This is characterized by accumulation in the meninges of gelatinous exudates commonly affecting the cranial nerves. This exudate is composed of mononuclear cells, epithelioid cells and Langhans' giant cells. It usually arises from subependymal regions from small caseous foci known as "Rich" foci (Greenfield). Copious exudates of TBM may cause obstruction in CSF flow at the level of basal

cisterns (basal arachnoiditis) resulting in communicating hydrocephalus (Figure 1). An incidence of hydrocephalus as high as 80% in tuberculous meningitis has been reported. Accumulation of exudates in the basal regions may compress optic chiasm, nerves and internal carotid arteries. Opto-chiasmatic arachnoiditis can lead to blindness in 5-10% of cases with TBM. Patients with tuberculous meningitis are clinically staged according to their presenting symptoms and their stage at diagnosis correlates directly with individual prognosis (Table 1).

Figure 1. MR image in a case of tuberculous meningitis.

Coronal cut showing enhancement of the meninges in the left Sylvian fissure (a) and basal meninges (a,b). Resultant hydrocephalus is also evident in the MR images particularly in (b)

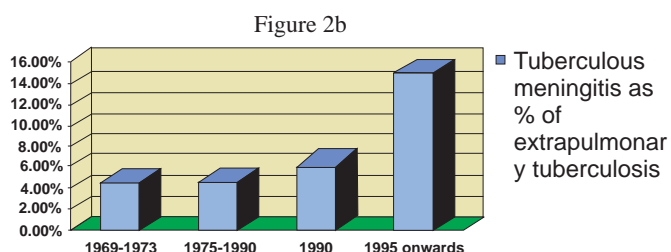
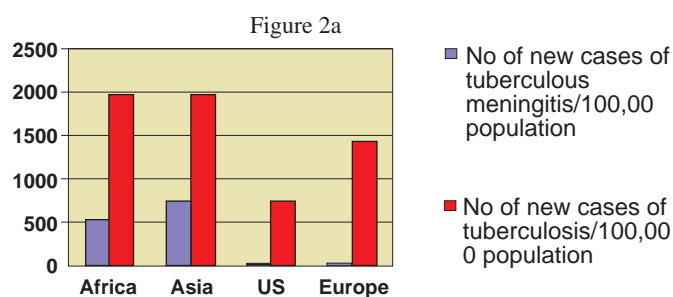


Corresponding Author: S. Ather Enam, MD, PhD, FRCSI, FRCS, FACS Head, Section of Neurosurgery and Associate Professor, The Aga Khan University, Karachi, Pakistan
E-mail: ather.enam@aku.edu

Table 1

TUBERCULOUS MENINGITIS	
Constitutional symptoms	80%
Headache	86%
Meningism	25-30%
Cranial nerve palsies	15-40%
Altered mental status, Focal neurological deficits, n/vulsions	
INTRACRANIAL TUBERCULOMA	
S/s of space occupying lesion i.e. headache, seizures	60-100%
Focal neurological deficits	33-68%
S/s of raised intracranial pressure	56-93%
Fever, signs of meningeal irritation and cranial nerve palsies less common	
TUBERCULAR BRAIN ABSCESS	
Constitutional symptoms	46%
Headache	47%
Focal neurological deficits	71%
Seizures	35%
Altered consciousness	24%

In many developing countries tuberculous meningitis is especially common in patients younger than 5 years. Infants usually present with non-specific symptoms, which include irritability, restlessness poor feeding, and physical signs of hydrocephalus. In immunocompromised patients, tuberculous meningitis manifests clinically in a similar manner. That TBM complicates a significant number of TB in developing countries and that TBM incidence is increasing progressively compared to other extra-pulmonary TB even in developed countries is shown in Figure 2.

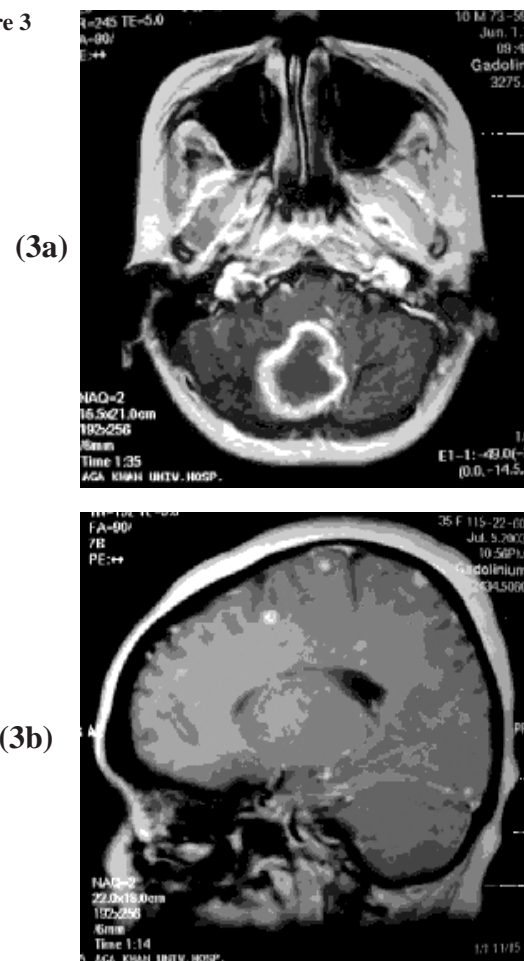


Two other conditions that need to be considered with TBM are tuberculous vasculitis and tuberculous encephalitis⁴. The exudative inflammatory change in the meninges may extend along the perforating vessels and incite reactive proliferation of microvessels. This extension can give rise to encephalitis which may or may not be focal. Vasculitis may cause thrombosis in the perforating and other small vessels and occasionally in larger vessels such as middle cerebral artery leading to ischemic changes and multiple infarcts, one of the main perilous outcomes of TBM.

Tuberculomas

A tuberculoma is an infrequent manifestation of central nervous system tuberculosis. It may occur singly but is more often multiple. In approximately 16% of patients, it may co-exist with culture positive tuberculous meningitis⁵. At Aga Khan University Hospital (AKUH), Karachi, Pakistan 246 patients were admitted during the period of 2000-2004 with the suspicion of tuberculous meningitis. 89 (36.1%) of these had tuberculomas, either with or without culture positive tuberculous meningitis (unpublished observations). The most common site for TBT is posterior cranial fossa (Figure3).

Figure 3



The reason for this is not well understood but might be the predilection of TBM to occur in basal regions which eventually gives rise to TBT. Posterior fossa location of TBT is particularly more common in patients less than 20 years. Compression of the CSF pathway either in the 4th ventricle or at the cerebral aqueduct by tuberculomas gives rise to hydrocephalus. Microscopically, it is composed of a caseous center surrounded by a granulomatous reaction including giant cells, lymphocytes and fibrosis. Unusual presentations of TBT may consist of multiple small perivascular “incipient type” granulomas which develop as gradual conglomeration on cortical surface, miliary neuro-tuberculosis, cystic tuberculomas, and tuberculomas in subdural or trans-dural locations⁶. Tuberculomas were one of the most common space occupying lesions in the beginning of the twentieth century. Their incidence dropped to less than 2% during the latter half of the same century in developed countries but it continues to constitute a significant proportion of intracranial mass lesions in developing countries (8-12%)⁷. The clinical features of intracranial tuberculomas are related to the mass effect, local or general, produced by the lesion (Table 2).

TABLE 2
Staging of Patient with TBM (Ref 35)

STAGING	CLINICAL MANIFESTATIONS
Stage 1	Fully conscious, no focal neurological deficits
Stage 2	Inattentive, confused, focal neurological signs
Stage 3	Coma, stupor, multiple cranial nerve palsies, hemiplegia or paraplegia

Tuberculomas in the spinal cord may present with signs and symptoms of myelopathy spinal cord compression, or rarely radiculopathy⁸.

Tubercular Brain Abscess

TBA is a rare form of central nervous system tuberculosis. It is characterized by an encapsulated collection of pus, containing viable tubercular bacilli with or without evidence of tubercular granuloma⁹. Not more than 25 cases have been reported so far in literature. They are typically larger than tuberculomas and evolve rapidly. The exact mechanism of their formation is unknown. Occasionally tuberculomas may contain super-infection by other bacteria¹⁰. The signs and symptoms due to TBA may not be much different than those from TBT except for its fast progression (Table3).

Table 3

Predictors of Poor Prognosis in CNS TB (Ref. 29-33)

■	Clinical condition
●	Decreased mental status
●	Focal neurological deficits
●	Cranial nerve palsies
●	Convulsions
●	Mechanical ventilation
■	Coexisting miliary or extrameningeal tuberculosis/ coinfection with HIV
■	Age
●	Very young
●	Age greater than 60 years
■	CSF values
●	Culture positive for MTB
●	Raised protein
●	Reduced glucose
■	Delayed or interrupted treatment

Tuberculous Encephalopathy

TBE is another rare outcome of TB invading CNS. It is usually more common in younger population and is characterized by diffuse brain edema and demyelination which usually is extensive¹¹. Microscopically it is characterized by microvascular necrosis with perivascular macrophage reaction and demyelination along with focal glial nodules in the white matter and occasional hemorrhagic lesions. Combination of progressive tuberculosis along with severe alcoholic intoxication has been characterized as acute toxic encephalopathy syndrome¹². This syndrome is characterized by impaired consciousness, epileptic seizures, disseminated intravascular coagulation, signs and symptoms of meningitis without spinal fluid changes. This syndrome may be one of the leading causes of neurologic devastation and death in CNS TB patients with high alcohol intake.

Spinal tuberculosis (Pott’s disease), the most common form of skeletal tuberculosis will be mentioned here briefly as it frequently leads to neurologic deficits. It may result in serious consequences like deformity and paraplegia due to bony destruction. TB spine may also lead to epidural tuberculous abscess or less commonly subdural tuberculous abscess. An increased predominance of spinal TB in immunocompromised individuals has been noted. Chemotherapy is the mainstay of treatment, with surgical procedures reserved for cases which are medically untreatable.

Diagnosis

Both TBT and TBA remain difficult to diagnose and rapid-turn around testing with high predictive values is needed. Clinical features supported by indirect evidence such as CSF examination and imaging studies of the head and spine have been used for early diagnosis. The differentials to be considered

in tuberculous meningitis are other bacterial meningitides, fungal infections, central nervous system toxoplasmosis and central nervous system lymphoma. The differential diagnosis of tuberculoma should include sarcoid granuloma, primary brain tumors, pyogenic abscess, fungal infections, cystic astrocytoma, lymphoma, cysticercosis and metastatic lesions. The differential diagnosis in AIDS patients must include opportunistic infections such as toxoplasmosis.

Laboratory Methods

Conventional bacteriological methods rarely detect *Mycobacterium tuberculosis* in cerebrospinal fluid (CSF) and are of limited use in the diagnosis of TBM. CSF protein between 100-200 mg/dl, CSF glucose less than 40 mg/dl, CSF leukocyte count between 50-500/microl with predominant CSF lymphocytes are considered characteristic findings in TBM patients¹⁵. Tuberculous meningitis could be confirmed in half of clinically suspected cases by this method.

Polymerase Chain Reaction (PCR) offers a rapid and fairly accurate diagnosis of tuberculous meningitis^{14,15}. Although specificity and sensitivity as high as 100% have been reported, until there is advancement in PCR technique, this test alone is insufficient as a single diagnostic test for tuberculosis^{16,17}. Furthermore, in recent studies, immunological diagnostic techniques were found to be superior to PCR. These methods, owing to their rapid yield and easier method, also seem convenient for use in laboratories in the developing world¹⁸. Gene probes, gene amplification methods and in situ approaches offer unparalleled capability to enhance the diagnosis of tuberculosis in the near future¹⁹.

Radiological Evaluation

Modern imaging is a cornerstone in the early diagnosis of central nervous system tuberculosis and may prevent unnecessary morbidity and mortality.

Chest X-ray:

The chest x-ray in patients with central nervous system tuberculosis may show features of miliary or pulmonary tuberculosis. In about 47% of central nervous system tuberculosis patients, the CXR may not reveal any abnormalities²⁰.

Computerized Tomography (CT):

In patients with tuberculous meningitis, hydrocephalus is the most common (80%) abnormality detected by CT. Less commonly; parenchymal/basal cistern enhancement is noted. Cerebral infarcts and surrounding edema can be detected in approximately 13% of patients, while tuberculomas can be detected in up to 5% of patients with tuberculous meningitis. The CT can be normal in up to 12% of patients²⁰.

In patients with tuberculomas, the characteristic CT finding is a nodular enhancing lesion with a central hypodense region. Such a lesion arising due to tuberculous involvement of the central nervous system is difficult to differentiate on CT from other intracranial diseases i.e. abscesses, neoplasms, multiple sclerosis, gliosis etc.²¹. Extensive surrounding edema and mass effects are usually seen in the acute inflammatory stage but are not as prominent in chronic tuberculomas²⁰. The appearance of TBA on CT is similar to tuberculomas and to that of other intracranial abscesses, showing lesions with central hypodensity and peripheral enhancement.

Magnetic Resonance Imaging (MRI):

Contrast enhanced MRI is generally considered as the modality of choice for detecting and assessing central nervous system involvement by tuberculosis. The MRI may demonstrate localized lesions and meningeal enhancement^{22,23}. It is useful for assessment of the location of lesions and their margins, as well as ventriculitis, meningitis and spinal involvement (sensitivity 86%, specificity 90%). Choroid plexus enhancement with ventricular enlargement on MRI is highly suggestive of TBM. In TBM, MRI shows diffuse, thick, meningeal enhancement. Cerebral infarcts can be seen in nearly 30% of cases²⁴. While current radiological methods such as CT and MRI are able to identify abnormalities highly suggestive and in some cases diagnostic of TBM, their overall diagnostic yield is less than optimal.

The MRI features of the individual tuberculoma depend on whether the granuloma is non-caseating, caseating with a solid center, or caseating with a liquid center. The non-caseating granuloma usually is hypointense relative to brain on T1-W images and hyperintense on T2-Weighted (T2-W) images and shows homogenous post-contrast enhancement. The caseating granuloma with solid caseation appears relatively hypointense or isointense on T1-W images and isointense to hypointense on T2-W images. The granulomas with central liquefaction of the caseous material appear centrally hypointense on T1-W image and hyperintense on T2-W images with a peripheral hypointense rim on T2-W images. Gadolinium enhanced T1-W images show rim enhancement in caseating granulomas.

Role of Biopsy

Establishing a diagnosis of TBT can be very challenging as the TBT lesions are similar to myriad of other lesions on imaging studies. Accurate diagnosis of tuberculoma is not possible until the brain lesion in question is subjected to histopathological examination. Seven out of 13 patients, who underwent biopsy at AKUH for suspicion of tuberculoma, had other diagnoses (unpublished observations). Although surgical intervention is considered mandatory in clinically diagnosed tuberculoma patients with worsening clinical or radiological features, definite guidelines regarding surgical biopsy for diagnosis are lacking.

Treatment and Prognosis

Anti-tubercular therapy (ATT) is the mainstay of management in central nervous system tuberculosis. Meta-analysis and RCT have suggested that corticosteroids are beneficial in the survival of patients with CNS TB^{25,26}. The duration of ATT may need to be adjusted to radiological response when treating tuberculomas²⁷. Despite ATT, mortality is reported to be high in tubercular abscesses⁹.

Surgery has a role both in the diagnosis and treatment of tuberculoma. It is usually indicated in cases of clinical deterioration that fail to respond to medical management and when the diagnosis of tuberculoma is in doubt. Surgical treatment options for TBA include simple puncture, continuous drainage, fractional drainage, repeated aspiration through a burr hole, stereotactic aspiration and total excision of the abscess. Ventriculoperitoneal shunts may be required in patients with TBM or TBT who develop obstructive hydrocephalus. Ventriculoperitoneal shunt should be performed at the time the need for shunting is determined and should not be delayed waiting for the infection to resolve²⁸.

Despite prompt initiation of effective ATT, central nervous system tuberculosis continues to have a poor prognosis. Complications of tuberculous meningitis constitute the major causes of morbidity and mortality of central nervous system tuberculosis, especially in the pediatric population.

Patients with stage 1 disease at presentation usually make a complete recovery or are left with only mild neurological deficits, while around 30% of patients with advanced stage at presentation succumb to severe residual neurological sequelae²⁹. Those who survive central nervous system tuberculosis are left with serious dysfunctions such as cognitive disturbances, seizures, hemiparesis, ataxia, visual impairment, optic atrophy and other persistent cranial nerve palsies. Children and older persons, because of their less competent immune systems are more vulnerable to contracting central nervous system tuberculosis. In a recent study, approximately 28% of paediatric patients with central nervous system tuberculosis died and 40% were left with permanent severe neurological sequelae³⁰. Some of the predictors of poor prognosis in patients with central nervous system tuberculosis are shown in table 3. It is likely that BCG protects against a fatal outcome in tuberculous meningitis³⁶.

Conclusion

Central nervous system tuberculosis is one of the more severe forms of extra-pulmonary tuberculosis. There has been a significant increase in the incidence of CNS TB worldwide over the last couple of decades.

It may present as tuberculous meningitis, tuberculoma, tuberculous abscess, or encephalopathy. Its diagnosis relies on

laboratory studies of the CSF and/or visualization of a lesion on CT or MRI. Newer diagnostic techniques, such as PCR, have not been assessed completely and are not possible in most settings in the developing world. Neurosurgeons have been actively involved in the treatment of central nervous system tuberculosis due to its propensity to cause obstructive hydrocephalus, intracranial mass lesions, and compressive myelopathy. Surgery has a role both in the diagnosis and/or treatment of tuberculoma and tubercular brain abscess although definite guidelines have yet to be formulated. A high index of suspicion is required in order to avoid delays in diagnosis, which may influence treatment outcome. Death may occur as a result of missed diagnosis and delayed treatment.

References

1. Bernaerts A, Vanhoenacker FM, Praizel PM, et al. Tuberculosis of the central nervous system; overview of neuroradiological findings. *Eur Radiol* Aug 2003;13(8):1876-90.
2. Pathology and pathogenetic mechanisms in neurotuberculosis *Radiol Clin North Am.* 1995 Jul;33(4):733-52.
3. Davis LE, Rastogi KR, Lambert LC, et al. Tuberculous meningitis in the southwest United States: a community-based study. *Neurology* 1993;43:1775-78.
4. Sinh G, Pandya SK, Dastur DK. Pathogenesis of unusual intracranial tuberculomas and tuberculous space-occupying lesions. *J Neurosurg* 1968 Aug;29(2):149-59.
5. Tiel R, Rosenblum ML. Chronic granulomatous lesions: Tuberculosis, leprosy, sarcoidosis, in Wilkins RH, Rengachary SS (ed) *Neurosurg.* New York, NY: McGraw Hill pp 3341- 3353. 1996.
6. MacDonell AH, Baird RW, Bronze MS. Intramedullary tuberculomas of the spinal cord; case report and review. *Reviews of infectious diseases* 1990 May-June;12(3):430-39.
7. Vidal JE, Cimerman S, Da Silva PR, et al. Tuberculous brain abscess in a patient with AIDS: case report and literature review. *Rev Inst Med Trop Sao Paulo.* 2003 Mar-Apr;45(2):111-4. Epub 2003 May 14.
8. Siddiqui AA, Sarwari AR, Chishti KN. Concomitant tuberculous and pyogenic brain abscess. *Int J Tuberc Lung Dis.* 2001 Jan;5(1):100-1.
9. Dastur DK. The pathology and pathogenesis of tuberculous encephalopathy and radiculomyelopathy: a comparison with allergic encephalomyelitis. *Childs Nerv Syst.* 1986;2(1):139.
10. Kornilova ZK, Khokhlov IK, Savin AA, et al. Clinical aspects, diagnosis and treatment of neurological complications of tuberculosis. *Probl Tuberk.* 2001;(3):29-32.
11. Adams RD, Victor M. Nonviral infections of the nervous system. In Adams RD, Victor M *Principles of Neurology.* Pp 599-638. 1993.
12. Kox LF, Kuijper S, Kolk AH. Early diagnosis of tuberculous meningitis by polymerase chain reaction. *Neurology* 1995 Dec;45(12):2228-32.

-
13. Rafi A, Naghily B. Efficiency of polymerase chain reaction for the diagnosis of tuberculous meningitis. *Southeast Asian J Trop Med Public Health*. 2003 Jun;34(2):357-60.
 14. Lin JJ, Harn HJ, Hsu YD, et al. Rapid diagnosis of tuberculous meningitis by polymerase chain reaction assay of cerebrospinal fluid. *J Neurol*. 1995 Feb;242(3):147-52.
 15. Jatana SK, Nair MNG, Lahiri KK, et al. Polymerase chain reaction in the diagnosis of tuberculosis. *Indian Pediatrics* 2000;37:375-382.
 16. Sumi MG, Mathai A, Reuben S, et al. A comparative evaluation of dot immunobinding assay (Dot-Iba) and polymerase chain reaction (PCR) for the laboratory diagnosis of tuberculous meningitis. *Diagn Microbiol Infect Dis* 2002 Jan;42(1):35-8.
 17. Katoch VM. Newer diagnostic techniques for tuberculosis. *Indian J Med Res*. 2004 Oct;120(4):418-28.
 18. Ozates M, Kemalolu S, Gurkan F, et al. CT of the brain in tuberculous meningitis. A review of 289 patients. *Acta Radiologica* 41 (2000) 13-17.
 19. Weisberg LA. Granulomatous diseases of the CNS as demonstrated by computerized tomography. *Comput Radiol*. 1984 Sep-Oct;8(5):309-17.
 20. Pui MH, Memon WA. Magnetic resonance imaging findings in tuberculous meningoencephalitis. *Can Assoc Radiol J*. 2001 Feb; 52(1):43-9.
 21. Wasay M, Khealeani BA, Moolani MK et al. Brain CT and MRI findings in 100 consecutive patients with intracranial tuberculoma. *J Neuroimaging*. 2003 Jul; 13(3): 240-7
 22. Kioumeh F, Dadestan MR, Rooholamini SA, et al. Central nervous system tuberculosis: MRI. *Neuroradiology* 1994;36(2):93-6.
 23. Roos KL. Pearls and pitfalls in the diagnosis and management of central nervous system infectious diseases. *Semin Neurol* 1998;18(2):185-96.
 24. Thwaites GE, Nguyen DB, Nguyen HD, et al. Dexamethasone for the treatment of tuberculous meningitis in adolescents and adults. *NEJM* Oct 2004;351(17):1741-51
 25. Poonnoose SI, Rajshekhar V. Rate of resolution of histologically verified intracranial tuberculomas. *Neurosurgery* 2003 Oct; 53(4) 873-879.
 26. Schoeman J, Donald P, VanZyl L. Tuberculous hydrocephalus: comparison of different treatments with regard to ICP, ventricular size and clinical outcome. *Dev Med Child Neurol* 1991;33:396-405.
 27. Kent SJ, Crowe SM, Yung A, et al. Tuberculous meningitis: a 30-year review. *Clin Infect Dis* 1993;17:987-94.
 28. Farinha NJ, Razali KA, Holzel H, et al. Tuberculosis of the central nervous system in children: a 20-year survey. *General of Infection* (2000) 41, 61-68
 29. Schoeman CJ, Nienkemper DC, Herst I. The effect of tuberculous meningitis on the cognitive and motor development of children. *S Afr Med J* 1997a;87:7072
 30. Wang JT, Hung CC, Sheng WH, et al. Prognosis of tuberculous meningitis in adults in the era of modern antituberculous chemotherapy. *J Microbiol Immunol Infect*, 2002 Dec;35(4):215-22.
 31. Wasay M, Moolani MK, Zaheer J, et al. Prognostic indicators in patients with intracranial tuberculoma: a review of 102 cases. *J Pak Med Assoc*. 2004 Feb;54(2):83-7.
 32. Hosoglu S, Geyik MF, Balik I, et al. Predictors of outcome in patients with tuberculous meningitis. *Int J Tuberc Lung Dis*, 2002 Jan;6(1):64-70.
 33. Qureshi HU, Merwat SN, Nawas SA, et al. Predictors of inpatient mortality in 190 adult patients with tuberculous meningitis. *JPMA*, 2002 April;52(4):1596-3.
 34. Udani TM. BCG vaccination in India and TB in children. *Indian J Pediatr*, 1994 Sep-Oct;61(5):451-62
 35. Zahra Ahmadinejad, Vahid Ziaee, Masood Aghsaefar, et al. The prognostic factors of tuberculous meningitis. *The Internet Journal of Infectious Diseases*. 2003. Volume 3 Number 1.
 36. Jamison DT, Creese A, Prentice T: World Health Report 1999. World Health Organization.
-