



THE AGA KHAN UNIVERSITY

eCommons@AKU

Section of Dental-Oral Maxillofacial Surgery

Department of Surgery

January 2016

Deep Bite Malocclusion: Exploration Of The Skeletal And Dental Factors

Nita Kumari Bhateja

Aga Khan University, nita.kumari@aku.edu

Mubassar Fida

Aga Khan University, mubassr.fida@aku.edu

Attiya Shaikh

Aga Khan University

Follow this and additional works at: https://ecommons.aku.edu/pakistan_fhs_mc_surg_dent_oral_maxillofac

Recommended Citation

Bhateja, N. K., Fida, M., Shaikh, A. (2016). Deep Bite Malocclusion: Exploration Of The Skeletal And Dental Factors. *Journal of Ayub Medical College*, 28(3), 449-454.

Available at: https://ecommons.aku.edu/pakistan_fhs_mc_surg_dent_oral_maxillofac/66

ORIGINAL ARTICLE

DEEP BITE MALOCCLUSION: EXPLORATION OF THE SKELETAL AND DENTAL FACTORS

Nita Kumari Bhateja, Mubassar Fida, Attiya Shaikh

Section of Dentistry, Department of Surgery, The Aga Khan University Hospital, Karachi-Pakistan

Background: Correction of deep bite is crucial for maintenance of dental hard and soft tissue structures and for prevention of temporomandibular joint disorders. Exploration of underlying skeletal and dental factors is essential for efficient and individualized treatment planning. To date etiological factors of dental and skeletal deep bite have not been explored in Pakistani orthodontic patients. The objectives of this study were to explore frequencies of dental and skeletal etiological factors in deep bite patients and to determine correlations amongst dental and skeletal etiological factors of deep bite. **Methods:** The study included a total of 113 subjects (males=35; females=78) with no craniofacial syndromes or prior orthodontic treatment. Pre-treatment orthodontic records were used to evaluate various dental and skeletal parameters. Descriptive statistics of each parameter were calculated. The various study parameters were correlated using Pearson's Correlation. **Results:** Deep curve of Spee was most frequently seen factor of dental deep bite (72.6%), followed by increased coronal length of upper incisors (28.3%), retroclined upper incisors (17.7%), retroclined lower incisors (8%) and increased coronal length of lower incisors (5.3%). Decreased gonial angle was most commonly found factor of skeletal deep bite (43.4%), followed by decreased mandibular plane angle (27.4%) and maxillary plane's clockwise rotation (26.5%). Frankfort mandibular plane angle and gonial angle showed a strong positive correlation ($r=0.66$, $p=0.000$). **Conclusions:** Reduced gonial angle is most frequently seen skeletal factor, signifying the importance of angulation and growth of ramus in development of deep bite. Deep curve of Spee is most frequently seen dental etiological component in deep bite subjects, hence signifying the importance of intruding the lower anterior teeth

Keywords: Deep bite, dental factors, skeletal factors

J Ayub Med Coll Abbottabad 2016;28(3):449-54

INTRODUCTION

Malocclusion is demarcated as an occlusion in which there are irregularities in tooth position beyond standard limits, or there is an abnormal relationship.¹ From initial eras of orthodontics, overbite is an essential occlusal characteristic that has been the focused for treatment alterations.² Improvement of overbite has also been considered to evaluate the excellence of orthodontic treatment results.³ Deep bite malocclusion is described as "the overlap of upper incisors on the labial surface of lower incisors vertically when the standard limit of 1-2 mm is exceeded".⁴ Deep bite is frequently seen malocclusion in an orthodontic practice and it is the most challenging aberration to treat efficiently.⁴ Proffit *et al*⁵ reported that severe deep bites (overbite ≥ 5 mm) are seen in approximately 20% of the children and 13% of the adult population, demonstrating around 95.2% of the occlusal deviations in vertical plane. Likewise, the most recent national health and nutrition examination survey (NHANES III) discovered that in US population normal overbite was around 3 mm. Around 14% population presented with an overbite of ≤ 0 mm and nearly 16% of the population presented with a deep

bite ≥ 5 mm and demonstrating a frequent occurrence of overbite problems.⁶

A local study conducted in Pakistan on orthodontic patients showed that normal overbite (1-2 mm) was seen in only 16% of their sample, whereas, mild (3-4 mm), moderate (5-6 mm) and severe deep bites (>7 mm) were found in around 28.2%, 20.5% and 30.8% of their sample, respectively.⁷ Being a frequently seen disharmony, this is one of the major concerns for an orthodontist. In addition to that, deep bite causing trauma to gingival or palatal tissues is considered as severe problem definitely needing treatment in orthodontic practice.⁸

Incisor over eruption, extreme overjet, malposed canine, molar infra-occlusion, mandibular ramus height, vertical facial type,⁴ accentuated curve of Spee,⁹ and excessive root torque of the upper incisors labially¹⁰ are features related to the aetiology of deep overbite malocclusion. Faerovig and Zachrisson¹¹ in their study found that deep bite malocclusion is associated with increased anterior and decreased posterior alveolar basal heights. Furthermore, Zhylich and Suri¹² in their systematic review confirmed that the choice of extraction of

mandibular incisors leads to arch collapse with a resultant bite deepening effect.

Accurate diagnosis and precise appreciation of underlying etiological components will aid the understanding of the condition, prevention, early prediction and eventually in optimal treatment outcomes. Most investigators have described the treatment strategies using anterior bite plane,¹³ functional appliances,¹⁴ continuous arch wire mechanics,¹⁵ cervical headgear,¹⁶ utility arches,¹⁷ mini screw implants^{18,19} and orthognathic surgery²⁰. Even though there are several approaches available for management of deep bite but the ideal treatment method will be determined by the treatment goals and patient's characteristics. Nonsurgical treatment substitutes consist extrusion of molars, intrusion of incisors or both in combination.¹³⁻¹⁹ Noroozi²¹ demonstrated that extrusion of posterior teeth by every 1 mm reduces the overbite by 1.5 mm anteriorly, confirming that lesser quantities of molar extrusion can cause substantial anterior bite opening. But in deep bite patients with predisposition towards vertical growth pattern, opening bite by extruding posterior segments is not suggested. For these patients true incisor intrusion is an excellent treatment opportunity. Ng *et al*²² in their systematic review verified that extent of intrusion was only 1.9 mm for lower incisors and 1.5 mm for the upper anterior teeth maximally.

Untreated deep bite can cause ulceration of the gingival tissues, attrition of lower incisors, temporomandibular joint disorders and abnormal mandibular function.²³ Therefore, improvement of deep overbite is essential objective of orthodontic therapy. Investigation of underlying aetiological elements is imperative for customized and effective treatment planning. To the best of our understanding, to date dental and skeletal features of deep bite have not been evaluated in Pakistani orthodontic patients. Hence, current study was aimed to determine frequencies of various etiological features and the correlations amongst them.

MATERIAL AND METHODS

This was a cross sectional study design carried out at the Aga Khan University Hospital, Karachi, Pakistan. The time period of present study was from January to December 2014. The present study mainly concentrated on the deep bite malocclusion in patients presenting for the orthodontic treatment. The subjects of Pakistani origin having good quality pre-treatment records, deep bite of greater than 5 mm and fully eruption of permanent 2nd molars were included. Patients with craniofacial anomalies, prior history of orthodontic treatment and clinically missing permanent teeth other than third molars were

excluded. A non-probability purposive sampling technique was used.

The data were acquired from pre-treatment dental casts and lateral cephalometric radiographs of the subjects visiting orthodontic clinics from January 2010 to November 2014. Total number of the subjects who were registered during this time period came out to be 656 patients. Deep bite of greater than 5 mm was seen in 141 patients. From this group, 28 patients were excluded because of un-erupted permanent second molars, presence of craniofacial syndromes and clinically missing permanent teeth. Finally the total sample size comprised of 113 subjects.

Cephalometric dental and skeletal measurements^{24,25} and dental cast measurements²⁵ were used in the study to assess the various skeletal and dental factors of deep bite as shown in figure-1 and 2 and table-1. To minimize the chances of error, linear parameters were measured via digital Vernier calliper (0-150 mm ME00183, Dentaureum, Pforzheim, Germany) with reliability of 0.01 mm and an accuracy of 0.02 mm manufacturer's specification.

SPSS version 19.00, Chicago, Inc. was used for data analyses. Means and standard deviations for age of female and male subjects were determined. Descriptive statistics were used to calculate frequencies as well as the means and standard deviations of various skeletal and dental deep bite etiological factors. All these parameters were correlated using Pearson correlation coefficient. A *p*-value of <0.05 was taken as statistically significant.

RESULTS

The entire sample comprised of 113 individuals (35 males; 78 females). The female patients were found to have the mean age of 15.7±5 years and the mean age of male patients was 17.2±5 years.

Key outcomes of present cross-sectional study indicate that in individuals with deep bite increased curve of Spee and decreased gonial angle are most frequently seen dental and skeletal factors respectively. Frankfort mandibular plane angle and gonial angle showed the statistically significant strong positive correlation ($r=0.66, p=0.000$).

Table-2 shows the descriptive statistics of various study parameters of deep bite patients. Table-3 represents the frequencies of skeletal and dental deep bite factors. Increased curve of Spee was most commonly seen factor of dental deep bite (72.6%), and increased coronal length of lower incisors was least frequent component (5.3%). Diminished gonial angle was most usually seen characteristic of skeletal deep bite (43.4%) and clockwise rotation of maxillary plane was least frequent parameter (26.5%).

Several dental and skeletal deep bite components were correlated by using Pearson

correlation coefficient as shown in table-4. In the correlations amongst skeletal factors, gonial angle was found to have statistically significant negative correlation with ramus/Frankfort horizontal ($r= -0.57, p=0.000$) and positive correlation with mandibular plane angle ($r=0.66, p=0.000$).

In the correlation between dental factors, statistically significant positive correlation was seen between maxillary and mandibular posterior dentoalveolar heights ($r=0.35, p=0.000$). Likewise, statistically significant positive correlation was seen amongst maxillary and mandibular anterior dentoalveolar heights ($r=0.47, p=0.000$). Furthermore, statistically significant positive correlation was also appreciated amongst increased clinical crown lengths of upper and lower incisors ($r=0.48, p=0.000$).

In the correlations between dental and skeletal parameters, increased lower incisor inclination was observed to have statistically significant negative correlations with mandibular plane angle ($r= -0.36, p=0.000$) and gonial angle ($r= -0.42, p=0.000$).

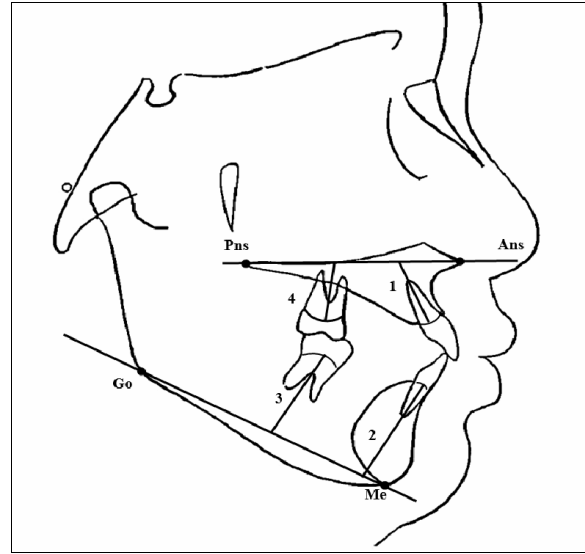


Figure-2: Dental Cephalometric Linear Measurements^{24,25}

Dental Cephalometric Linear Measurements	
1) Maxillary anterior alveolar and basal height (Mx-AABH, mm)	Distance between midpoint of alveolar meatus of maxillary central incisor and intersection point between palatal plane and long axis of maxillary central incisor
2) Mandibular anterior alveolar and basal height (Md-AABH, mm)	Distance between midpoint of alveolar meatus of mandibular central incisor and intersection point between mandibular plane and long axis of mandibular central incisor
3) Mandibular posterior alveolar and basal height (Md-PABH, mm.)	Perpendicular distance between midpoint of alveolar meatus of mandibular first molar and mandibular plane
4) Maxillary posterior alveolar and basal height (Mx-PABH, mm)	Perpendicular distance between midpoint of alveolar meatus of maxillary first molar and palatal plane

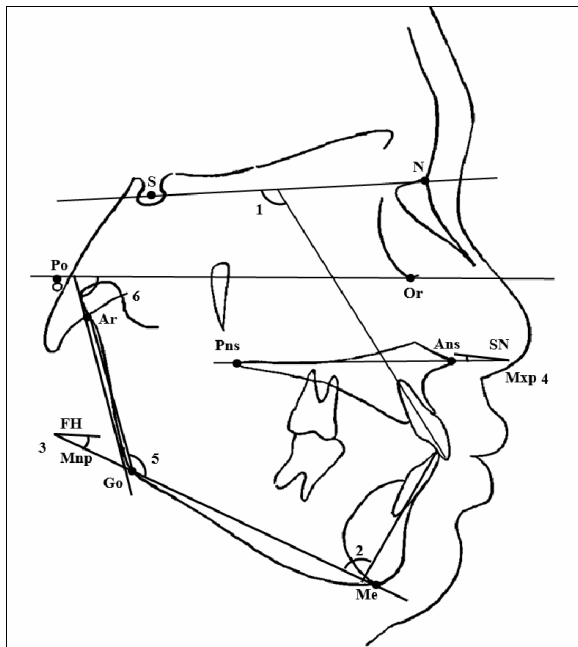


Figure-1: Dental and Skeletal Cephalometric Measurements^{24,25}

Dental Cephalometric Angular Measurements	
1) Maxillary incisor inclination (U1/SN, °)	Angle formed between extension of long axis of maxillary incisor and sella-nasion plane
2) Mandibular incisor inclination (LI/MP, °)	Angle formed between extension of long axis of mandibular incisor and mandibular plane
Skeletal Cephalometric Angular Measurements	
3) Mandibular plane angle (MndP-FH, °)	Angle formed between mandibular plane and Frankfort horizontal plane
4) Maxillary plane angle (SN-MxP, °)	Angle formed between maxillary plane and sella-nasion plane
5) Gonial angle (Ar-Go-Me, °)	Angle formed at gonial area between posterior border of ramus and a corpus line
6) Ramus/FH (RFH, °)	Angle formed between tangent to posterior ramus border and Frankfort horizontal plane

Table-1: Dental Cast Measurements²⁵

Measurement	Definition
Crown lengths of maxillary / mandibular central incisors (Mx-UI / Mnd-LI length, mm)	Line formed between midpoint of cervical margin of tooth and midpoint of incisal edge
Curve of Spee (COS, mm)	Line formed between deepest point on mandibular buccal segment and a horizontal line formed between most over erupted mandibular incisor and molar

Table-2: Values of dental and skeletal Factors of deep bite

Factor	Maximum	Minimum	Mean	±SD
Dental				
Mx-AABH, (mm)	29.00	11.00	20.24	3.44
Mx-PABH, (mm)	27.00	8.00	14.66	3.11
Md-AABH, (mm)	40.00	20.00	31.04	3.79
Md-PABH, (mm)	32.00	14.00	22.37	3.11
U1/SN, (°)	129.00	68.00	106.42	11.07
LI/MP, (°)	125.00	73.00	97.68	8.55
Mx-UI length, (mm)	13.00	7.00	9.97	1.09
Mnd-LI length, (mm)	11.00	6.00	7.83	1.03
COS, (mm)	6.00	1.00	3.10	1.13
Skeletal				
Ar-Go-Me, (°)	142.00	105.00	124.14	7.64
MndP-FH, (°)	36.00	7.00	24.55	5.73
SN-MxP, (°)	19.00	2.00	8.44	3.52
RFH, (°)	95.00	63.00	81.53	5.98

N=113, Descriptive statistics

Table-3: Frequencies of dental and skeletal factors of deep bite

Factor	Percentage (%)
Dental	
Increased COS, (mm)	72.6
Increased Mx-UI length, (mm)	28.3
Decreased U1/SN, (°)	17.7
Decreased L1/MP, (°)	8
Increased Mnd-UI length, (mm)	5.3
Skeletal	
Decreased Ar-Go-Me, (°)	43.4
Decreased MndP-FH, (°)	27.4
Increased SN-MxP, (°)	26.5

N=113, Descriptive statistics

Table-4: Correlations between dental and skeletal factors of deep bite malocclusion

	A	B	C	D	E	F	G	H	I	J	K	L	M	N
A	1													
B	.56**	1												
C	.47**	.37**	1											
D	.27**	.35**	.44**	1										
E	.29**	.07	.14	-.16	1									
F	.14	-.03	.23*	.07	.15	1								
G	.23*	.08	.04	-.01	-.17	-.36**	1							
H	.17	.04	-.06	-.11	.07	-.42**	.66**	1						
I	-.25**	-.11	-.16	-.11	-.14	-.02	.15	-.10	1					
J	.26**	.10	.15	.05	.29**	.30**	-.01	.03	-.10	1				
K	.26**	.02	.27**	.10	.32**	.15	.10	.12	-.07	.48**	1			
L	.10	.11	.14	.04	.03	-.12	.10	.03	-.23*	.11	.04	1		
M	-.16	-.5	-.20*	-.10	-.18	-.11	-.05	-.15	-.01	-.13	-.13	.12	1	
N	.11	.12	.20*	.18	-.23*	.08	.05	-.57**	.20*	-.09	-.06	.06	.012	1
A- Mx-AABH, (mm)									H- Ar-Go-Me, (°)					
B- Mx-PABH, (mm)									I- SN-MxP, (°)					
C- Md-AABH, (mm)									J- Mx-UI length, (mm)					
D- Md-PABH, (mm)									K- Mnd-UI length, (mm)					
E- U1/SN, (°)									L- COS, (mm)					
F- L1/MP, (°)									M- Overbite					
G- MndP-FH, (°)									N- RFH, (°)					

N=113, Pearson Correlation, **Correlation is significant at the 0.01 level (2-tailed), *Correlation is significant at the 0.05 level (2-tailed)

DISCUSSION

A deep bite malocclusion is clinical manifestation of various skeletal and dental discrepancies. The inspection of such skeletal and dental factors helps to design efficient mechanics which are crucial for stable deep bite correction.

Ceylan and Erozt²⁶ evaluated the effect of overbite on mandibular and maxillary morphology. Moreover, Baydas *et al*⁹ examined the relationship between positions of incisors, overjet, overbite, lower anterior crowding and depth of curve of Spee. The present study targeted at illuminating the numerous skeletal as well as dental factors of deep bite, along with scrutinizing their frequencies and determining the correlations among the investigated factors.

The ramus/Frankfort horizontal angle shows the mandibular ramus angulation with reference to Frankfort horizontal plane. El-Dawlatly *et al*²⁵ in their study on deep bite patients reported the mean value of this angle to be 82.06°±5.54. In our study, the mean value of ramus/Frankfort horizontal angle was found to be 81.53±5.98, which was comparable to their reported value. El-Dawlatly *et al*²⁵ further

revealed that reduced gonial angle was most usually seen skeletal factor whereas increased maxillary plane angle was the least common factor, supporting the influence of angulation and growth of mandibular ramus in increasing deep bite compared with maxillary factors. Our results were in agreement to their study in this aspect.

Marshall *et al*²⁷ in their study reported that an accentuated Spee’s curve plays an important role in development of dental deep bite. Similarly, in present study, the increased Spee’s curve also had the greatest influence amongst all the etiological factors. This highlights the significance of levelling Spee’s curve for correction of deep bite by extrusion of lower posterior teeth and intrusion of lower anterior teeth in most deep bite patients.

Second most frequent dental factor was the increased coronal length of upper incisors. Burstone²⁸ in his study supported intrusion of the upper incisors as the best option for deep bite treatment but, extent of intrusion depends on numerous factors to avoid detrimental effects to the facial appearance. Zachrisson²⁹ in his study described that the treatment

choice relies on extent of visibility of the upper incisors on smile and at rest; extreme incisor show is best treated with intrusion of the upper front teeth. Extruding posterior teeth or intruding lower front teeth are better treatment options in patients with average or diminished incisor show. The smile arc also guides for designing individualized treatment plan of patients with deep bite malocclusion. For subjects presenting with flat smile arc, intrusion of the upper front teeth is not recommended.

Sangcharearn and Christopher¹⁰ reported that there is negative correlation amongst inclination of maxillary anterior teeth and the amount of overbite. They established that 6 degrees reduction in inclination leads to 0.3 mm overbite enhancement. In contrast, in our study the retroclination of the upper and lower incisors were the very uncommon factors of deep bite malocclusions. Moreover, inclination of the maxillary incisors and the amount of overbite were not found to have any statistically significant correlation ($r = -0.18, p = 0.057$).

Upper and lower anterior dentoalveolar heights showed statistically significant medium positive correlation ($r = 0.47, p = 0.000$). In this aspect, our findings were in agreement with those of El-Dawlatly *et al.*²⁵ This finding specifies that in individuals in whom upper incisor intrusion is planned for deep overbite improvement, intrusion of lower incisors should be considered and vice versa. This approach can improve stability, avoid excessive intrusion and reduces the risk of root resorption.

In our study increased lower incisor inclination was found to have negative correlation with parameters evaluating the vertical facial growth pattern. This conclusion was in agreement with the Tweed analysis³⁰, confirming that as the tendency towards vertical facial growth pattern of increases, the lower incisor inclination tends to decrease and vice versa.

The present study had a limitation. As this study primarily targeted on deep bite components in orthodontic patients, therefore outcomes do not represent the trend of whole Pakistani population. Hence, further research needs to be carried out to measure the etiological deep bite factors on a larger sample on community basis.

CONCLUSIONS

- Reduced gonial angle is the most frequently seen skeletal factor, ratifying the impact of angulation of mandibular ramus and growth in increasing deep bite.
- A deep Spee's curve is most frequently seen dental parameter, ratifying the significance of intrusion of lower anterior teeth.

- Retroclination of maxillary and mandibular incisors and increased mandibular incisor length were amongst least frequent factors.

Conflicts of interest: There are no conflicts of interest to the authors in the present study.

AUTHOR'S CONTRIBUTION

Topic selection and conceptualization of study design was done by MF and AS. Literature search, data collection, data analysis, data interpretation and write-up was performed by NKB. Proof reading was performed by all the authors.

ACKNOWLEDGEMENTS

All the dental faculty and residents

REFERENCES

1. Daskalogiannakis J, Ammann A. Glossary of orthodontic terms. Quintessence Books Chicago; 2000.
2. Strang R. An analysis of the overbite problems in Malocclusion. *Angle Orthod* 1934;4(1):65-84.
3. Bergerson EO. A longitudinal study of anterior vertical overbite from eight to twenty years of age. *Angle Orthod* 1988;58(3):237-56.
4. Parker CD, Nanda RS, Currier GF. Skeletal and dental changes associated with the treatment of deep bite malocclusion. *Am J Orthod Dentofacial Orthop* 1995;107(4):382-93.
5. Proffit WR, Fields HW, editors. Contemporary orthodontics. St Louis: C. V. Mosby; 2007;3-92.
6. Drury TF, Winn DM, Snowden CB, Kingman A, Kleinman DV, Lewis B. An overview of the oral health component of the 1988-1991 National Health and Nutrition Examination Survey (NHANES III-Phase 1). *J Dent Res* 1996;75:620-30.
7. Gul-e-Erum, Fida M. Pattern of malocclusion in orthodontic patients: a hospital based study. *J Ayub Med Coll Abbottabad* 2008;20(1):43-7.
8. Brook PH, Shaw WC. The development of an index of orthodontic treatment priority. *Eur J Orthod* 1989;11(3):309-20.
9. Baydas B, Yavuz I, Atasalar N, Ceylan I, Dagsuyu I. Investigation of the changes in the positions of upper and lower incisors, overjet, overbite, and irregularity index in subjects with different depths of curve of Spee. *Angle Orthod* 2004;74(3):349-55.
10. Sangcharearn Y, HO C. Effect of incisors angulation on overjet and overbite in class II camouflage treatment. *Angle Orthod* 2007;77(6):1011-8.
11. Faerovig E, Zachrisson BU. Effects of mandibular incisor extraction on anterior occlusion in adults with class III malocclusion and reduced overbite. *Am J Orthod Dentofacial Orthop* 1999;115(2):113-24.
12. Zhylich D, Suri S. Mandibular incisor extraction: a systematic review of an uncommon extraction choice in orthodontic treatment. *J Orthod* 2011;38(3):185-95.
13. Forsberg CM, Hellsing E. The effect of a lingual arch appliance with anterior bite plane in deep overbite correction. *Eur J Orthod* 1984;6(2):107-15.
14. Mills CM, McCulloch KJ. Treatment effects of the twin block appliance: a cephalometric study. *Am J Orthod Dentofacial Orthop* 1998;114(1):15-24.
15. Bernstein RL, Preston CB, Lampasso J. Leveling the curve of Spee with a continuous archwire technique: a long term cephalometric study. *Am J Orthod Dentofacial Orthop* 2007;131(3):363-71.
16. Godt A, Kalwizki M, Goz G. Effects of cervical headgear on overbite against the background of existing growth patterns.

- A retrospective analysis of study casts. *Angle Orthod* 2007;77(1):42–6.
17. Aydogdu E, Ozsoy OP. Effects of mandibular incisor intrusion obtained using a conventional utility arch vs. bone anchorage. *Angle Orthod* 2011;81(5):767–75.
 18. Senisik NE, Turkkahraman H. Treatment effects of intrusion arches and mini-implant systems in deep bite patients. *Am J Orthod Dentofacial Orthop* 2012;141(6):723–33.
 19. Ishihara Y, Kuroda S, Sugawara Y, Balam TA, Takano-Yamamoto T, Yamashiro T. Indirect usage of miniscrew anchorage to intrude overerupted mandibular incisors in a Class II patient with a deep overbite. *Am J Orthod Dentofacial Orthop* 2013;143(4 Suppl):S113–24.
 20. Jager A, Kubein-Meesenburg D, Luhr HG. Longitudinal study of combined orthodontic and surgical treatment of class II malocclusion with deep overbite. *Int J Adult Orthodon Orthognath Surg* 1991;6(1):29–38.
 21. Noroozi H. A simple method of determining the bite-opening effect of posterior extrusion. *J Clin Orthod* 1999;33(12):712–4.
 22. Ng J, Major PW, Heo G, Flores-Mir C. True incisor intrusion attained during orthodontic treatment: a systematic review and meta-analysis. *Am J Orthod Dentofacial Orthop* 2005;128(2):212–9.
 23. McDowell EH, Baker IM. The skeletodental adaptations in deep bite correction. *Am J Orthod Dentofacial Orthop* 1991;100(4):370–5.
 24. Jacobson A, Jacobson R. *Radiographic Cephalometry From Basic to 3-D Imaging*. 2nd ed. Hanover Park, IL: Quintessence Publishing Co; 2006.
 25. El-Dawlatly MM, Fayed MM, Mostafa YA. Deep overbite malocclusion: analysis of the underlying components. *Am J Orthod Dentofacial Orthop* 2012;142(4):473–80.
 26. Ceylan I, Erozu UB. The effects of overbite on the maxillary and mandibular morphology. *Angle Orthod* 2001;71(2):110–5.
 27. Marshall SD, Caspersen M, Hardinger RR, Franciscus RG, Aquilino SA, Southard TE. Development of the curve of Spee. *Am J Orthod Dentofacial Orthop* 2008;134(3):344–52.
 28. Burstone CR. Deep overbite correction by intrusion. *Am J Orthod* 1977;72(1):1–22.
 29. Zachrisson BU. Esthetic factors involved in anterior tooth display and the smile vertical dimension. *J Clin Orthod* 1998;32(7):432–45.
 30. Tweed CH. The Frankfort-mandibular plane angle in orthodontic diagnosis, classification, treatment planning, and prognosis. *Am J Orthod Oral Surg* 1946;32(4):175–230.

Address for Correspondence:

Dr. Nita Kumari Bhateja, Resident Orthodontics, Section of Dentistry, Department of Surgery, The Aga Khan University Hospital, P.O Box 3500, Stadium Road, Karachi 74800-Pakistan

Cell: +92 345 368 8144

Email: drnita@live.com