



THE AGA KHAN UNIVERSITY

eCommons@AKU

Section of Internal Medicine

Department of Medicine

September 2001

Cryptococcus--diversity of clinical presentation

S B. Memon

Aga Khan University

A M. Memon

Aga Khan University

S Faisal

Aga Khan University

N Kapadia

Aga Khan University

I N. Soomro

Aga Khan University

Follow this and additional works at: https://ecommons.aku.edu/pakistan_fhs_mc_med_intern_med

Recommended Citation

Memon, S. B., Memon, A. M., Faisal, S., Kapadia, N., Soomro, I. N. (2001). Cryptococcus--diversity of clinical presentation. *Journal of Pakistan Medical Association*, 51(9), 337-339.

Available at: https://ecommons.aku.edu/pakistan_fhs_mc_med_intern_med/57

Cryptococcus - Diversity of Clinical Presentation

S. B. Memon (Final year Medical Student, The Aga Khan University, Karachi.)
A. M. Memon, S. Faisal (Departments of Medicine, The Aga Khan University, Karachi.)
N. Kapadia (Departments of Dermatology, The Aga Khan University, Karachi.)
I. N. Soomro (Departments of Pathology, The Aga Khan University, Karachi.)

Introduction

Cryptococcus neoformans is an encapsulated yeast, which is highly prevalent in the soil, animals and as a colonist in humans¹. The most important event involved in host defense against Cryptococcus neoformans is the development of an adequate cell-mediated immune response² particularly T cell mediated immunity³. The level of immunity can cause the spectrum to vary from mere colonization of the respiratory tract to serious meningitic or disseminated forms of illness⁴. However, human cryptococcal disease is generally encountered in patients with leukemia, Hodgkin's disease or non-Hodgkin's lymphoma, in those receiving prolonged steroid therapy, or in people who have Acquired Immunodeficiency Syndrome. Although the immune status is an important factor in determining the degree of infection, reports have shown that 50% of patients do not have any recognizable antecedent or concomitant immunodeficiency^{5,6}.

We came across two unusual cases. In the first case marked eosinophilia was noted. The second patient had cryptococcal infection in the breast.

Case Report

Case 1

A 16-year-old female student presented with a history of pyrexia and cough for eight months. The fever was low grade, occurred in the evenings and was not associated with rigors. She occasionally produced yellow sputum. There was no history of dyspnea.

Auscultation revealed coarse crackles bilaterally. Her chest X-ray showed diffuse bilateral interstitial infiltrates with honey comb pattern. An ultrasound of the abdomen showed hepatosplenomegaly. Her hemoglobin level was 9.8 gm/dl, total leukocyte count was 21,000 and the peripheral blood smear showed 50% eosinophils, 27% neutrophils and 21% lymphocytes. A bone marrow aspirate and trephine revealed normal hemopoietic precursor cells, erythropoiesis was normoblastic and myelopoiesis showed increase in the eosinophilic precursors which comprised about 40-45% of the total nucleated cells in the bone marrow. No evidence of parasitic infection was found on stool examination. Empirical treatment with mebendazole for three days did not result in any improvement in eosinophilia. Her sputum AFB smear was negative. ANA, ASMA and AMA were negative. On the basis of her clinical presentation she was started on anti tuberculosis therapy. Her condition worsened over the next month with her temperature increasing to 101-102.0 F and she developed hemoptysis. She had also developed an acneiform, umbilicated pustular rash on her face similar to Molluscum contagiosum (Figure 1).

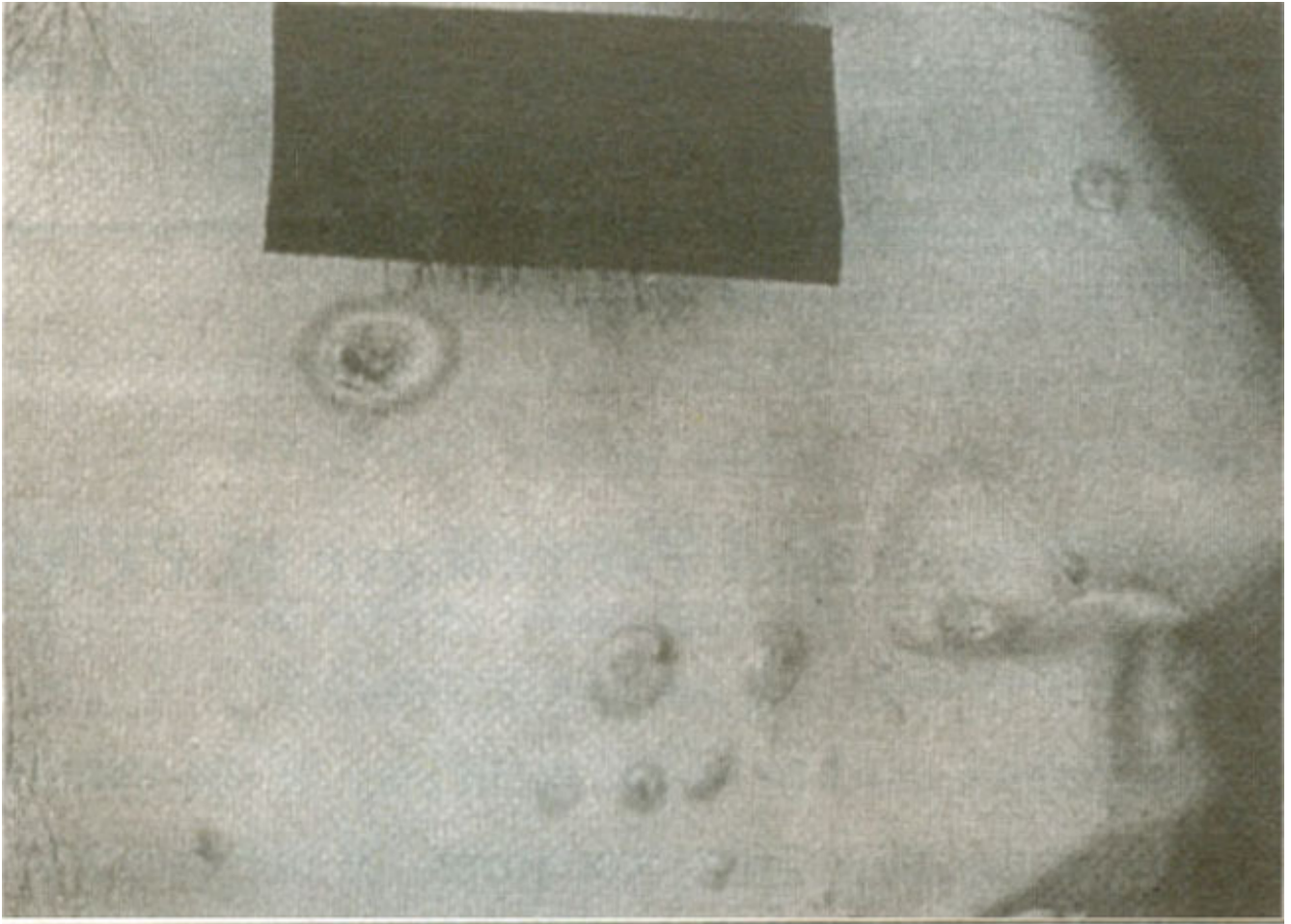


Figure 1.

A screening test for human immunodeficiency virus antibodies by enzyme-linked immunosorbent assay was negative. During hospitalization her left cervical lymph node became enlarged. Discrete 1-2 cms diameter firm, non tender lymph nodes were palpable below the angle of the left mandible. The histopathological examination of one of these lymph nodes revealed chronic granulomatous reaction composed of macrophages, lymphocytes and foreign body giant cells. Small cystic space filled with numerous cryptococci were seen. The entire tissue was studded with *Cryptococcus neoformans* (Figure 2).

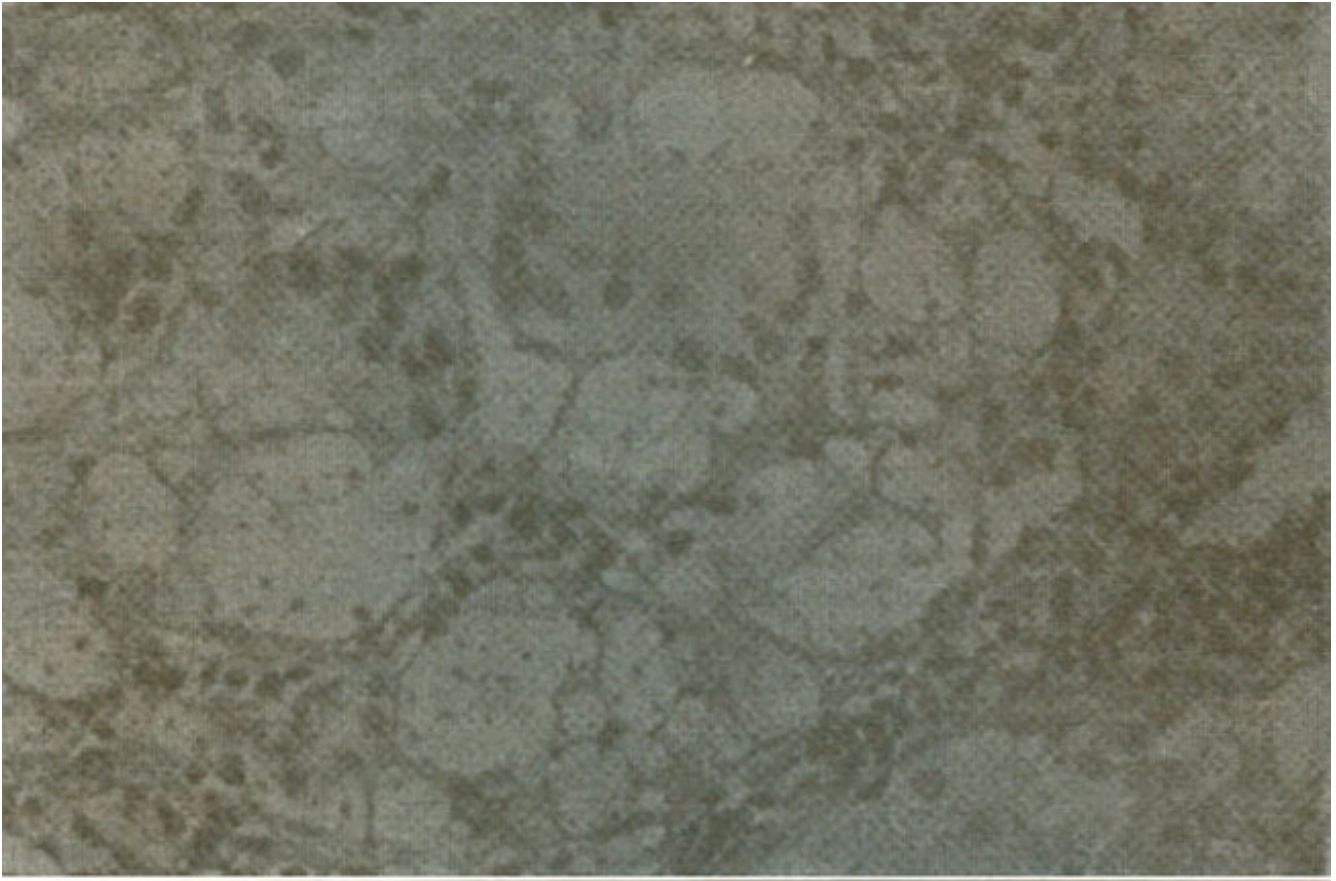


Figure 2

She was started on amphotericin and was discharged in improved status.

Case 2

A 45-year-old diabetic housewife presented with fever, history of weight loss and enlarging subcutaneous masses over various parts of her body since the past six months. These masses were of varying size and the largest swelling was present in the upper outer quadrant of the left breast. This lump was firm, well defined, non-tender and about 3 cm in diameter. The overlying skin was normal. There was no discharge from her nipple. This lump was associated with a soil left axillary lymph node about 5 cm in diameter. Due to this firm breast mass and associated subcutaneous nodular eruptions, carcinoma of the breast with metastasis was suspected. A mammograph could not be done because of financial constraints and paucity of facilities. A fine needle biopsy of this lump and of another lump in the thigh was performed. Cryptococci were seen with collections of histiocytes and multinucleated giant cells. Presence of typical periodic acid-Schiff yeasts led to the diagnosis of cryptococcal infection.

Treatment with Intravenous Amphotericin for initial two weeks resulted in significant reduction in size of the swellings. Subsequently she was switched to Fluconazole 400 mg, which was administered for eleven weeks. All of her masses disappeared except a scarred single left axillary lymph node. Follow up over last three years has not shown any sign of relapse.

Discussion

The presentation in both of these cases was distinctive. The unique facet of the first case was that cryptococcal disease and eosinophilia were a consistent finding. The serial absolute eosinophil count was above 1.5×10^9 /liter which qualified this case as hypereosinophilia⁷. Eosinophilia to this extent is

usually found in parasitic infections, allergic disorders, vasculitides and lymphoreticular malignancies⁸. Fungal infections in which peripheral eosinophilia has been documented are coccidioidomycosis, especially in disseminated infection⁹ and in allergic bronchopulmonary aspergillosis¹⁰. The apartment building where the first patient grew up was at one time inhabited with wild pigeons. A visit to her house by one of the authors with a team of physicians and a microbiologist did not reveal any source of fungal growth. Cultures taken from the soil of the dormitory where she had been staying for previous two years also did not show any *Cryptococcus*. Cryptococcal infection is usually associated with a slight neutrophilic leukocytosis in the peripheral blood and chronic meningitis in the CSF¹¹. This case as well as others written in the same context revises the need to include cryptococcal infection in the differential diagnosis of peripheral eosinophilia.

In the second case the patient presented with a breast lesion. The most common fungal infection of the breast is *Candida albicans*, which usually occurs in women after childbirth^{12,13}. Cryptococcal infection of the breast is a rare but treatable condition that may occur in both normal and immunocompromised hosts and may mimic other more common forms of breast disease, including carcinoma of the breast¹⁴. In this case we suspected carcinoma of the breast and performed a fine needle biopsy that proved to be diagnostic. The role for surgery alone is questionable and it is advised that surgery should be combined with systemic antifungal even if there is no documented infection outside the breast¹⁴.

We conclude that presence of eosinophilia should not distract us from considering *Cryptococcus* in the differential diagnosis. This fungus should be included in list of causes of breast lump.

References

1. Perfect JR, Durack DT, Gallis HA. Cryptococemia. *Medicine* 1983;62:98:109.
2. Monari C, Retim C, Palazzetti B, Bistoni F, Vecchiarelli A. Regulatory role of exogenous IL-10 in the development of immune response versus *Cryptococcus neoformans*, *Clin. Exp. Immunol.*, 1997;109:242-7.
3. Mody CH, Lipscomb ME, Street NE, Toews GB. Depletion of CD4+ (L3T4+) lymphocytes in vivo impairs murine host defense to *Cryptococcus neoformans*. *J Immunol.*, 1990;144:472-7.
4. Leggaia RJ, Barrett FF, Hughes WT. Extrapulmonary cryptococcosis in immunocompromised infants and children. *Pediatr. Infect. Dis. J.*, 1992;11:43-7.
5. Emmanuel S, Ching E, Lieberman AD, Goldin M. Cryptococcus meningitis in a child successfully treated with Amphotericin-B with a review of the pediatric literature. *J Pediatr.*, 1961;59:577-91.
6. Stewers CMF, Cramblett HG. Cryptococcosis (torulosis) in children. *Pediatrics.* 1964;34:393-400.
7. Spry CJF. The hypereosinophilic syndrome: clinical features, laboratory findings and treatment. *Allergy.* 1982;37:539-51.
8. Shurin SB. Pathologic states associated with activation of eosinophils and with eosinophilia. *Hematol. Oncol. Clin. North. Am.*, 1988;2:171-9.
9. Weller PF. Eosinophilic meningitis. *Am. J. Med.* 1993;95:250-3.
10. Scherinoly M, Hinthom DR. Eosinophilia in coccidioidomycosis. *Arch. Intern. Med.* 1988;148:895-6.
11. Marwaha RK, Trehan A, Jayashree K, Vasishta RK. Hypereosinophilia in disseminated cryptococcal disease. *Pediatr. Infect. Dis. J.*, 1995;14:1102-3.
12. Goldman M, Pottage JC. Cryptococcal Infection of the Breast. *Clinical. Infectious. Diseases.* 1995;21:1166-9.
13. Opri F. Mammary mycoses. *Chemotherapy.* 1982;28(stppl 1):61-5.
14. Amir LH. Candida in the lactating breast: predisposing factors. *J. Human Lactation.* 1991;7:177-81.