



THE AGA KHAN UNIVERSITY

eCommons@AKU

Section of Urology

Department of Surgery

2-2007

Mediastinal parathyroid adenoma causing primary hyperparathyroidism

Farhat Abbas

Aga Khan University, farhat.abbas@aku.edu

Syed Raziuddin Biyabani

Aga Khan University, raziuddin.biyabani@aku.edu

Amanullah Memon

Aga Khan University, amanullah.memon@aku.edu

Jamsheer Jehangir Talati

Aga Khan University, jamsheer.talati@aku.edu

Follow this and additional works at: https://ecommons.aku.edu/pakistan_fhs_mc_surg_urol



Part of the [Surgery Commons](#), and the [Urology Commons](#)

Recommended Citation

Abbas, F., Biyabani, S. R., Memon, A., Talati, J. J. (2007). Mediastinal parathyroid adenoma causing primary hyperparathyroidism. *Journal of the Pakistan Medical Association*, 57(2), 93-95.

Available at: https://ecommons.aku.edu/pakistan_fhs_mc_surg_urol/32

Mediastinal Parathyroid Adenoma causing primary Hyperparathyroidism

Farhat Abbas, Syed Raziuddin Biyabani, Amanullah Memon, Jamsheer Talati
Department of Surgery, The Aga Khan University, Karachi.

Abstract

An ectopically placed parathyroid adenoma in the anterior mediastinum is a rare cause of persistent or recurrent primary hyperparathyroidism (PHPT) and is recognized as an important cause of failed primary neck exploration. We encountered 3 such cases amongst 70 surgically treated patients with PHPT (4.3%) over a 20-year period. In 2 cases, the offending adenoma could be removed at first exploration whereas in the 3rd case, it was successfully removed with mediastinal exploration after 2 failed neck explorations. In established cases of PHPT with equivocal preoperative localization studies or negative neck explorations, an ectopically placed parathyroid adenoma should be considered and once localized, should be surgically removed for cure.

Introduction

Primary hyperparathyroidism (PHPT) is usually caused by a solitary parathyroid adenoma at a juxtathyroid location in the neck. The exact incidence of PHPT in Pakistan is not known, however, in one hospital based series, the reported incidence was 0.05% amongst 67,566 operated patients.¹ In 1-2% of PHPT cases, the hyper-functioning adenoma is ectopically placed in the mediastinum and is recognized as an important cause of failed primary neck exploration. In 28-30% of patients requiring localization studies and re-exploration for persistent or recurrent hypercalcaemia following failed initial surgery, the offending gland is found in the mediastinum. Re-exploration, however, is technically difficult and has a higher morbidity with a success rate ranging from 65-90%.² We encountered and herein report 3 cases of mediastinal parathyroid adenoma amongst 70 patients with PHPT (4.3%) who underwent surgery during 1985-2004.

Case Report

Case 1

A 40-year-old male presented in February 1992 with recurrent long bone fractures sustained with minimal trauma during last seven years. Earlier, he underwent internal fixation for fracture neck of left femur at another hospital with non-union and metal implant failure. There was marked osteopenia and large bone cysts in the neck and shaft region. He had muscular weakness, fatigue, palpitation, mood disturbances, nausea and occasional diarrhoea

during last six months.

Examination revealed an emaciated, bed ridden male with a hip spica for femoral neck fracture. Systemic examination and fundoscopy was normal with no neck masses. Urinalysis, complete blood counts, ESR, blood urea nitrogen, serum creatinine and serum electrolytes (sodium, potassium, chloride and bicarbonate) were normal. Serum calcium was 12.4 mg/dl (normal 8.5-10.5), serum phosphorus 2.0 mg/dl (normal 2.5-4.5) and serum magnesium was 1.1 mg/dl (normal 1.9-2.5). Serum proteins were normal. Twenty four-hour urinary calcium excretion was 750 mg (normal 100-300), and phosphorus was 135 mg (normal 400-1300). Serum parathormone (PTH) (mid-molar assay) level was elevated at 2.07 ng/ml (normal 0.5-1.5). A diagnosis of primary hyperparathyroidism with crippling bone disease was made. An intravenous pyelogram (IVP) and ultrasound revealed bilateral small, non-obstructive renal stones - otherwise the upper tracts were normal.

Preliminary studies with ultrasound, chest X-ray and Thallium - Technetium radioisotope scan of the neck were normal. While awaiting surgical exploration, the patient developed hyperparathyroid crisis with serum calcium at 15.8 mg/dl. This was aggressively managed with saline hydration, frusemide induced diuresis and intravenous Calcitonin therapy. Once stabilized, surgery was performed five days later with pre-operative methylene blue (6 mg/kg body weight) infusion to enhance intra-operative localization of a parathyroid adenoma. At cervical exploration, two superior suppressed parathyroid glands were identified and confirmed at biopsy and frozen section. However, the inferior glands or an adenoma could not be found even at ectopic sites within the neck. The right inferior thyroid artery appeared prominent and was traced down into the superior mediastinum where it led to a dark blue stained, 4x3x2 cms rounded lesion located in the upper half of an involuted thymus, presumed to be the parathyroid adenoma. A transcervical thymectomy, incorporating the adenoma was done. Histopathology confirmed the lesion to be an intrathymic parathyroid adenoma (Figure 1). Postoperatively, he had symptomatic hypocalcaemia needing intravenous calcium and magnesium replacement plus oral activated Vitamin-D therapy. Once stabilized with oral therapy, he was transferred to orthopedic services for continued care. At three months, serum calcium was 8.6 mg/dl and bones were beginning to show remineralization on X-rays.

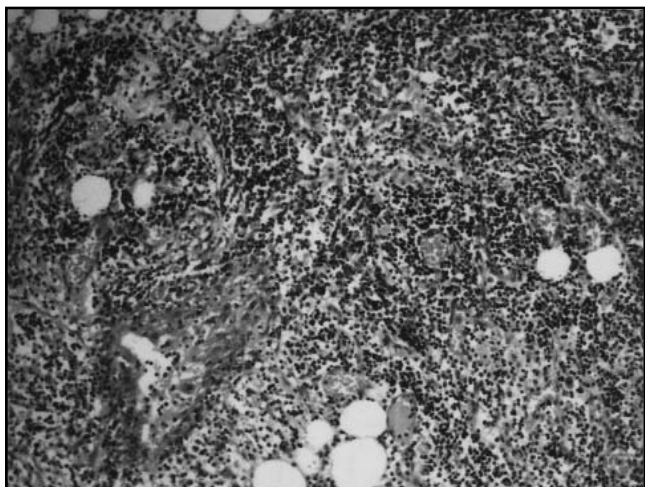


Figure 1. Intrathymic Parathyroid adenoma. Reduced from 400X.

Case 2

A 52-year-old male presented in December 1993 with a 2-year history of recurrent left flank pain and passage of stones per urethra. He also complained of body aches, undue fatigue and lethargy. For a year, he was on anti-hypertensive medications. Physical examination was essentially normal.

Routine laboratory investigations were normal. Serum calcium was 14.6 mg/dl (normal 8.5-10.5) and phosphorus was 2.4 mg/dl (normal 2.5-4.5). Serum uric acid was 11 mg/dl. 24-hour urinary calcium excretion was 306 mg (normal 100-300), whereas phosphorus and uric acid were normal. Serum proteins were normal. Serum parathormone level was elevated at 1.37 ng/ml (normal < 0.27). A chest X-ray was normal. An ultrasound and intravenous pyelogram (IVP) showed left-sided nephrocalcinosis.

With a diagnosis of primary hyperparathyroidism,

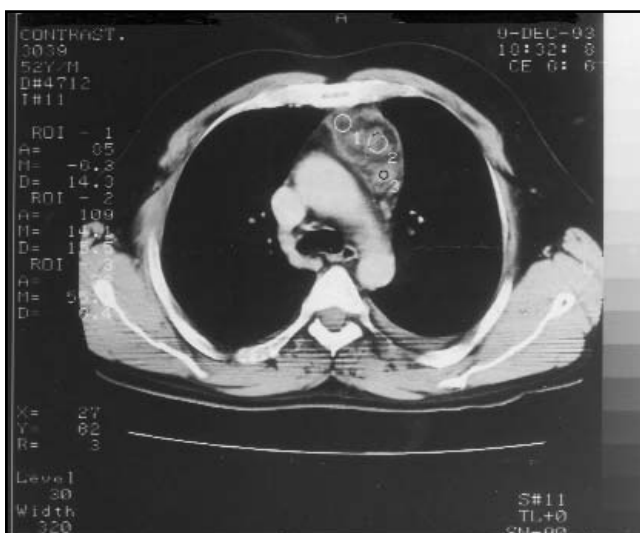

Figure 2. A CT Scan of the chest showing intrathymic parathyroid adenoma.

preliminary screening with an ultrasound and Thallium - Technetium radioisotope scan of the neck was normal. A CT Scan of the neck and chest showed no abnormality in the neck whilst a 6x3 cms sized mass was seen in the superior, anterior mediastinum compatible with a thymic mass (Figure 2). For a presumed intrathymic parathyroid adenoma, median sternotomy and total thymectomy was done jointly with cardiothoracic surgeon. Histopathology confirmed a parathyroid adenoma within an involuted thymus gland. Postoperatively, he became symptomatically hypocalcaemic which stabilized with calcium and vitamin-D replacement therapy. At two years follow up, he was normal.

Case 3

A 40-year-old female presented in February 1986 with a 2-year history of bone pains and spontaneous fracture of right femur which was managed conservatively. On evaluation outside AKU, she was diagnosed with primary hyperparathyroidism and had already undergone a negative neck exploration. Physical examination including the neck was unremarkable. Routine laboratory investigations were normal. Serum calcium was elevated at 12 mg/dl (9-10.6), phosphorous was 1.6 mg/dl (2.5-4.5) and serum proteins were normal with albumin of 4.8 gm/dl (3.5-5). Serum parathormone was 10ng/ml (0.5-1.5).

Based on initial negative neck exploration, localization study with an arteriogram was performed which showed increased vascularity on the left side of the neck raising suspicion of a parathyroid adenoma. A repeat neck exploration was performed which again failed to localize the offending adenoma or hyperplastic glands. Postoperatively, she persisted to have elevated serum calcium levels. A venous sampling was performed which revealed the following PTH levels: Inferior vena cava 4.79 ng/ml (0.43-1.86 ng/ml); left innominate vein - 4.77ng/ml; right innominate vein - 5 ng/ml; and thymic vein - more than 8 ng/ml.

A median sternotomy was performed and an intrathymic parathyroid adenoma was excised. Post-operatively, she became hypocalcemic and required intravenous calcium replacement followed by oral calcium and Vitamin-D therapy. One and a half year later, she underwent femoral osteotomy and metal plate fixation for a malunited fracture. Repeat calcium and phosphorus levels beyond 2 years were normal and PTH was 1.2 ng/ml at 9 months and 0.5ng/ml at 4 years (normal = <0.92).

Discussion

Ectopic mediastinal parathyroid adenomas producing primary hyperparathyroidism appear to be an uncommon entity. Mc Henry et al reported an incidence of 1.3%

amongst 522 surgically treated patients with hyperparathyroidism.² Mariette in his study looked at the reasons for re-operation for persistent or recurrent primary hyperparathyroidism reported that failed parathyroid operation was due to an ectopic parathyroid gland in 75% of cases.³ Of all the ectopic glands, 45% were intrathyroidal, 12.5% intrathyroidal, 7.5% retro-oesophageal, 7.5% in the carotid sheath, 5% interthyrotracheal, and 5% in the mediastinum (extrathyroidal). In another study involving patients re-operated for persistent or recurrent primary hyperparathyroidism, mediastinal approach was necessary in 15% of patients.⁴

The modalities to localize the gland pre-operatively include: CT scan, MRI, radio-isotope scans using 99m-technetium-methoxybutyl isonitrate (MIBI) and the favoured investigation of double-phase Tc-99m sestamibi scan.⁵⁻⁷

Whereas, open surgical excision remains the standard treatment for mediastinal parathyroid adenoma, thoracoscopic removal^{8,9} and angiographic ablation could be considered.¹⁰

In the present series, all of our patients were young as previously reported¹, two had severe bone disease, and two had previous neck explorations performed with one patient having had two negative neck explorations prior to mediastinal exploration. A cervical ultrasound was not helpful in preoperative localization of the lesion. All patients had intrathyroidal adenomas with 2/3rd of them requiring a median sternotomy for successful surgical removal of the offending intrathyroidal adenoma. Despite the significant comorbid condition of these patients, the surgical treatment is generally well tolerated in a tertiary care setting and is the mainstay to bring about a long term cure. The long term metabolic and rehabilitative management is crucial for effective management of these chronically ill patients. It is important that a multi-disciplinary team involving the endocrinologist, surgeons experienced in parathyroid surgery, radiologists, physical therapists and others as needed manage such patients.

Conclusion

Mediastinal location of ectopically placed parathyroid adenoma is rare but can cause persistence or recurrence of primary hyperparathyroidism. In cases of negative neck exploration or equivocal preoperative localization studies, this entity should be considered. Intrathyroidal location is common for ectopic mediastinal adenoma. Mediastinal exploration may be necessary to remove these lesions.

References

1. Biyabani SR, Talati J. Bone and renal stone disease in patients operated for primary hyperparathyroidism in Pakistan: is the pattern of disease different from the west? *J Pak Med Assoc* 1999; 49: 194-8.
2. McHenry C, Walsh M, Jarosz H, Henkin R, Tope J, Lawrence AM, Paloyan E. Resection of parathyroid tumor in the aorticopulmonary window without prior neck exploration. *Surgery* 1988;104: 1090-4.
3. Mariette C, Pellissier L, Combemale F, Quievreux JL, Carnaille B, Proye C. Reoperation for persistent or recurrent primary hyperparathyroidism. *Langenbecks Arch Surg* 1998; 383: 174-9.
4. Amalsteen L, Quievreux L, Huglo D, Pattou F, Carnaille B, Proye C. Reoperation for persistent or recurrent primary hyperparathyroidism. Seventy-seven cases among 1888 operated patients. *Ann Chir* 2004; 129: 224-31.
5. Ipponsugi S, Takamori S, Suga K, Koga T, Hayashi A, Sirouzu K, et al. Mediastinal parathyroid adenoma detected by 99mTc-methoxyisobutylisonitrate: report of a case. *Surg Today* 1997; 27: 80-3.
6. Moka D, Voth E, Larena-Avellaneda A, Schmidt M, Theissen P, Schicha H. Location of a small mediastinal parathyroid adenoma using Tc-99m MIBI SPECT. *Clin Nucl Med* 1998; 23: 186-7.
7. Norton KS, Johnson LW, Griffen FD, Burke J, Kennedy S, Aultman D, et al. The sestamibi scan as a preoperative screening tool. *Am Surg* 2002; 68: 812-5.
8. Furrer M, Leutenegger AF, Ruedi T. Thoracoscopic resection of an ectopic giant parathyroid adenoma: indication, technique, and three years follow-up. *Thorac Cardiovasc Surg* 1996; 44: 208-9.
9. O'Herrin JK, Weigel T, Wilson M, Chen H. Radioguided parathyroidectomy via VATS combined with intraoperative parathyroid hormone testing: the surgical approach of choice for patients with mediastinal parathyroid adenomas? *J Bone Mineral Res* 2002;17: 1368-71.
10. Doherty GM, Doppman JL, Miller DL, Gee MS, Marx SJ, Spiegel AM, et al., Results of a multidisciplinary strategy for management of mediastinal parathyroid adenoma as a cause of persistent primary hyperparathyroidism. *Ann Surg* 1992;215: 101-6.