



THE AGA KHAN UNIVERSITY

eCommons@AKU

Section of Ophthalmology

Department of Surgery

April 2015

Bilateral choroidal neovascularization after pegylated interferon therapy

Pir Salim Mahar
Aga Khan University

Abdul Mone
Aga Khan University, abdul.monem@aku.edu

Follow this and additional works at: [https://ecommons.aku.edu/
pakistan_fhs_mc_surg_ophthalmol](https://ecommons.aku.edu/pakistan_fhs_mc_surg_ophthalmol)

 Part of the [Ophthalmology Commons](#)

Recommended Citation

Mahar, P. S., Mone, A. (2015). Bilateral choroidal neovascularization after pegylated interferon therapy. *Journal of the College of Physicians and Surgeons Pakistan*, 25 Suppl 1, S45-S46.

Available at: https://ecommons.aku.edu/pakistan_fhs_mc_surg_ophthalmol/32

Bilateral Choroidal Neovascularization After Pegylated Interferon Therapy

Pir Salim Mahar^{1,2} and Abdul Sami Memon²

ABSTRACT

A 30-year-old male presented with gradual decrease in vision in his both eyes after the use of interferon alpha for his hepatitis-C. Ocular examination of patient included, Best Corrected Visual Acuity (BCVA), fundus photographs, Fundus Fluorescein Angiography (FFA) and Optical Coherence Tomography (OCT). His BCVA was recorded as 6/18 in the right eye and 6/12 in the left eye. The anterior segments were unremarkable, with normal intraocular Pressure (IOP) in his both eyes. Both fundi revealed the presence of bilateral Choroidal Neovascularization (CNV), confirmed on FFA and OCT. To the best of authors' knowledge, simultaneous presence of CNV in both eyes is not reported in the literature.

Key Words: *Bilateral choroidal neovascularization. Interferon alpha. Hepatitis-C.*

INTRODUCTION

Interferons are cytokines with antiviral, anti-proliferative and immuno-modulation property with ability to interfere with viral replication within host cells. They activate immune cells such as Natural Killer (NK) and cytotoxic-T cells and increase the ability of uninfected host cells to resist new infections by virus, by producing certain proteins known as interferon stimulated genes.¹ Interferon-alpha (IFN-alpha) therapy with or without other antiviral agents is standard care of treatment in patients with hepatitis-C.

We report a case of a patient with hepatitis-C, treated with IFN-alpha who developed ocular complication.

CASE REPORT

A 30-year male presented with gradual, painless decrease in vision in his both eyes for the last few weeks. He had hepatitis-C diagnosed 12 months ago and was treated with IFN-alpha (pegylated) therapy for 6 months. The patient had no history of Diabetes Mellitus (DM), Hypertension (HTN) or any other systemic disorder. He was not on any medical therapy at present.

His Fasting Sugar (FBS), glycated haemoglobin (HbA1c), Complete Blood Count (CBC), lipids and autoimmune profile were all within normal limits. Ocular examination revealed his Best Corrected Visual Acuity (BCVA) of 6/18 in his right eye and 6/12 in his left eye. The biomicroscopic examination showed anterior segments unremarkable in his both eyes with Intraocular Pressure (IOP) of 10 mmHg in his either eye. Fundus examination

with +90D volk lens revealed about two disc diameter, subfoveal lesions in both eyes (Figure 1). Fundus Fluorescein Angiography (FFA) showed hyper-fluorescein areas over macula, due to filling of choroidal neovascular membranes (Figure 2). The Optical Coherence Tomography (OCT) confirmed the presence of subfoveal choroidal neovascular membranes (Figure 3 and 4).

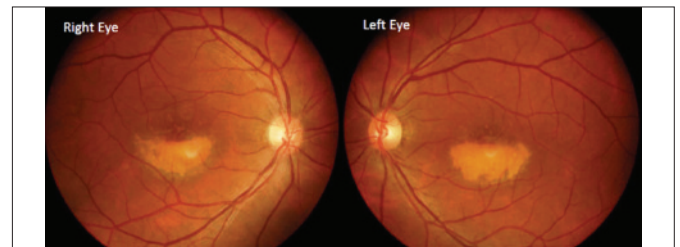

Figure 1: Coloured photographs of fundus.

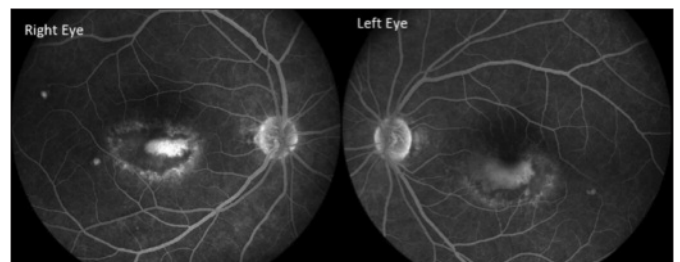


Figure 2: FFA of both eyes.

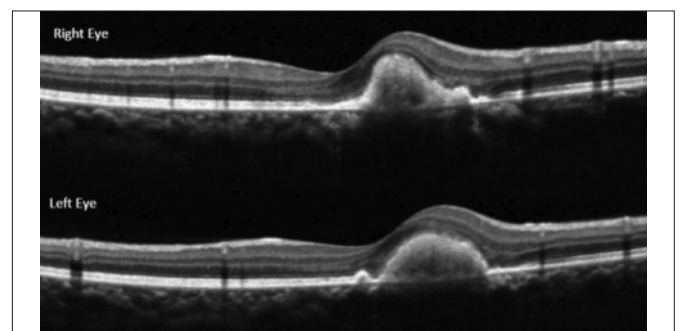


Figure 3: OCT of right and left eyes.

¹ Department of Ophthalmology, The Aga Khan University Hospital, Karachi.

² Department of Ophthalmology, Isra Postgraduate Institute of Ophthalmology, Karachi.

Correspondence: Prof. Pir Salim Mahar, 34/1, Khayaban-e-Mujahid, Near 22nd Street, Phase V, DHA, Karachi.

E-mail: salim.mahar@aku.edu

Received: June 04, 2014; Accepted: September 25, 2014.

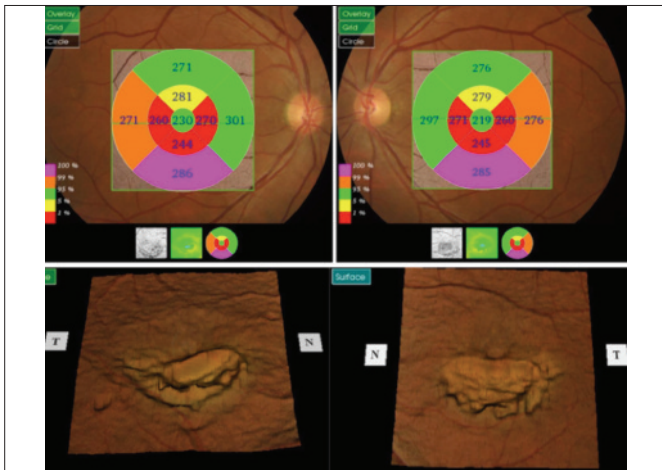


Figure 4: OCT showing macular thickness map.

The patient was advised and given injection Bevacizumab (Avastin) 1.25 mg intravitreally in his both eyes under sterile condition in operating room.

DISCUSSION

To the best of authors' knowledge, simultaneous presence of CNV in both eyes after IFN-alpha therapy is not reported in the literature previously. Retinal ischemia has been a common manifestation of IFN treatment in patients with hepatitis-C, characterized by presence of microaneurysms, retinal haemorrhages and cotton-wool spots.² The prevalence of retinopathy is variable among different studies. Panetta suggested an overall low occurrence of retinopathy at 3.8% in 180 patients treated with IFN-alpha,³ Kadayifcilar and co-workers evaluated 36 patients with chronic active hepatitis receiving IFN-alpha for one year and found 15 patients (42%) having retinopathy with cotton-wool formation and splinter haemorrhages.⁴

The underlying patho-physiology for IFN induced retinopathy is not known. The presence of retinal haemorrhages and cotton-wool areas suggest an ischemic response. The possible mechanism for retinopathy is believed to be due to immune system dysfunction, deposition of immune complexes in the retinal vessels and increase adhesions of activated leucocytes.⁵ Similar mechanism can be argued for choroidal ischemia resulting in Choroidal Neovascularization (CNV). The elevated level of Vascular Endothelial Growth Factor (VEGF) after IFN-alpha therapy has also been reported with correlation to choroidal ischemia and CNV.⁶ Hepatitis-C itself is believed to cause an increase in photocoagulated phospholipids resulting in hypercoagulable state, especially when combined with IFN-alpha treatment with production of thrombogenic auto-antibodies.⁷ Interestingly as IFN has angiostatic property and inhibits

the proliferation and migration of vascular endothelial cells, it has also been used to treat CNV in age-related macular degeneration. However, results of these studies are inconclusive with a need for further randomized trials.⁸

Ocular ischemic changes are more reported in patients with history of DM, HTN and with increased lipids and it is also believed that these changes settle down with termination of IFN-alpha therapy.⁹ Choroidal neovascularization in one eye after IFN-alpha therapy has already been reported.¹⁰ Other rare findings related to IFN-alpha therapy include anterior ischemic optic neuropathy, papilloedema, retinal artery occlusion, central retinal vein occlusion and pan-uveitis.⁴ This patient last used IFN-alpha 6 months ago and did not have any other associated risk factors, such as DM, HTN or raised lipids.

REFERENCES

1. Glue P, Fang JW, Rouzier-Panis R, Raffanel C, Sabo R, Gupta SK, *et al.* Pegylated interferon alfa-2b, pharmacokinetics, pharmacodynamics, safety and preliminary efficacy data: hepatitis-C intervention therapy group. *Clin Pharmacol Ther* 2000; **68**:556-67.
2. Adams S, Ostermeier M. Retinopathy associated with pegylated interferon and ribavirin treatment for chronic hepatitis-C. *Optometry* 2010; **81**:580-6.
3. Panetta JD, Gilani H. Interferon-induced retinopathy and its risk in patients with diabetes and hypertension undergoing treatment for chronic hepatitis-C virus infection. *Aliment Pharmacol Ther* 2009; **30**:597-602.
4. Kadayifcilar S, Boyacioglu S, Kart H, Gursoy M, Aydin P. Ocular complications with high-dose interferon alpha in chronic acute hepatitis. *Eye* 1999; **13**:241-6.
5. Sugano S, Suzuki T, Watanabe M, Ohe K, Ishi K, Okijima T. Retinal complications and plasma C 5a levels during interferon alpha therapy for chronic hepatitis. *Am J Gastroenterol* 1998; **93**: 2441-4.
6. Andrade R, Gonzales J, Vazquez L. Vascular ophthalmological side effects associated with antiviral therapy for chronic hepatitis-C are related to vascular endothelial growth factor levels. *Antivir Ther* 2006; **11**:491-8.
7. Jain K, Lam WC, Waheeb S, Thai Q, Heathcote J. Retinopathy in chronic hepatitis-C patient during interferon treatment with ribavirin. *Br J Ophthalmol* 2001; **85**:1171-3.
8. Chan CK, Kempin SJ, Noble SK, Palmer GA. The treatment of choroidal neovascularization by alpha interferon. An efficacy and toxicity study. *Ophthalmology* 1994; **101**:289-300.
9. Okuse C, Yotsoyanagi H, Nagase Y. Risk factors for retinopathy associated with interferon alpha-2b and ribavirin combination therapy in patients with chronic hepatitis. *World J Gastroenterol* 2006; **12**:2756-9.
10. Bazarah SM, Ritenour R, Patel ST, Hirsch G, Peltekian KM, Cruess AF. Choroidal neovascularization with interferon associated retinopathy: case report and review of literature. *Ann Hepatol* 2006; **5**:172-6.

