



THE AGA KHAN UNIVERSITY

eCommons@AKU

Section of Urology

Department of Surgery

September 2000

Surgical management of penile cancer--report of two cases.

M Amjad Noor
Aga Khan University

Hammad Ather
Aga Khan University

M Nasir Sulaiman
Aga Khan University

Farhat Abbas
Aga Khan University

Follow this and additional works at: http://ecommons.aku.edu/pakistan_fhs_mc_surg_urol



Part of the [Surgery Commons](#), and the [Urology Commons](#)

Recommended Citation

Noor, M. A., Ather, H., Sulaiman, M. N., Abbas, F. (2000). Surgical management of penile cancer--report of two cases. *Journal of the Pakistan Medical Association*, 97(9), 314-317.

Available at: http://ecommons.aku.edu/pakistan_fhs_mc_surg_urol/31

Surgical Management of Penile Cancer - Report of two cases

M. Amjad Noor, M. Hammad Ather, M Nasir Sulaiman, Farhat Abbas (Section of Urology, Department of Surgery, The Aga Khan University Hospital.)

Introduction

Penile carcinoma (PC) is a rare tumor, accounting for 0.4-0.6% of all male malignancies. There are remarkable racial and geographic differences in the prevalence of penile cancer. In United States, 1% of all male cancers are penile malignancies, with annual incidence of 1-2 new cases per 100,000 men. In certain areas of South America, Asia and Africa the frequency is as high as 10-20% of all male cancers. Many areas in Asia however, have very low figures; in Taiwan for example it comprised only 0.25% of all male cancers¹. Penile carcinoma is most frequent in uncircumcised males than in those circumcised in infancy, for example: Non-Jewish versus Jewish population in the West^{1,2} and non-Muslim versus Muslim population in India^{3,4}. Circumcision at birth however, does not always protect an individual from developing penile cancer⁵. Similarly circumcision beyond infancy is also not protective against the development of penile cancer⁶. PC has also been noted in the scarred penile shaft skin following mutilating circumcision⁷. A strong etiologic association of PC has been found between Human Papilloma Virus (HPV), phimosis, paraphimosis, and balanitis^{5,8}. Data from Asian countries indicates that the risk of PC increases progressively beyond 30 years of age with the peak incidence in the 6-7th decades of life⁹.

Some of the key factors complicating effective management of PC are the frequent delay in establishing the diagnosis, controversy about lymph node dissection and patients wish for penile conservation. The time from the initiation of signs and symptoms till the time the patient presents to a physician is usually prolonged, resulting in rather advanced stage of the primary lesion⁶ at presentation. This tends to adversely affect the treatment outcome of the disease.

In countries with very low incidence of PC, such as Pakistan, an average urologist rarely encounters such cases. Combined with the existing controversies about optimum treatment strategies, it is extremely difficult to develop management guidelines based on local experience. It therefore remains important to report such uncommon cancer cases to enlarge the existing local data. This paper describes 2 cases of PC managed at a university hospital during the last three years.

Parameters assessed were clinical presentation, physical examination findings, radiological work up and details of treatment offered. Patients were followed up for long term complications related to cancer treatment and surgical morbidity. Based on personal experience and from review of contemporary literature on the subject protocol for evaluation and treatment in the form of an algorithm is also proposed.

Case 1

A 60-year old male, presented with a 10-year history of itching at glans penis and an ulcer on right side of glans penis for the last 3 years. He suffered from diabetes mellitus and pulmonary tuberculosis and was circumcised in late childhood. His initial evaluation outside Karachi revealed squamous cell carcinoma (SCC) after biopsy of penile ulcer and was subsequently treated with chemotherapy and radiation therapy (no documentation was available). However, within a year he developed a recurrent ulcer at glans penis and presented to our outpatient clinic. His initial general and abdominal examination was unremarkable except for bilaterally enlarged inguinal lymph nodes. A biopsy of the glans penile ulcer revealed a moderately differentiated SCC. X-ray chest showed multiple opacities in the right upper zone which on CT scan of chest, was suggestive of healed tuberculous lesions. CT guided percutaneous biopsy of the pulmonary lesion also showed chronic inflammatory changes. MRI

of the penis (Figure 1)

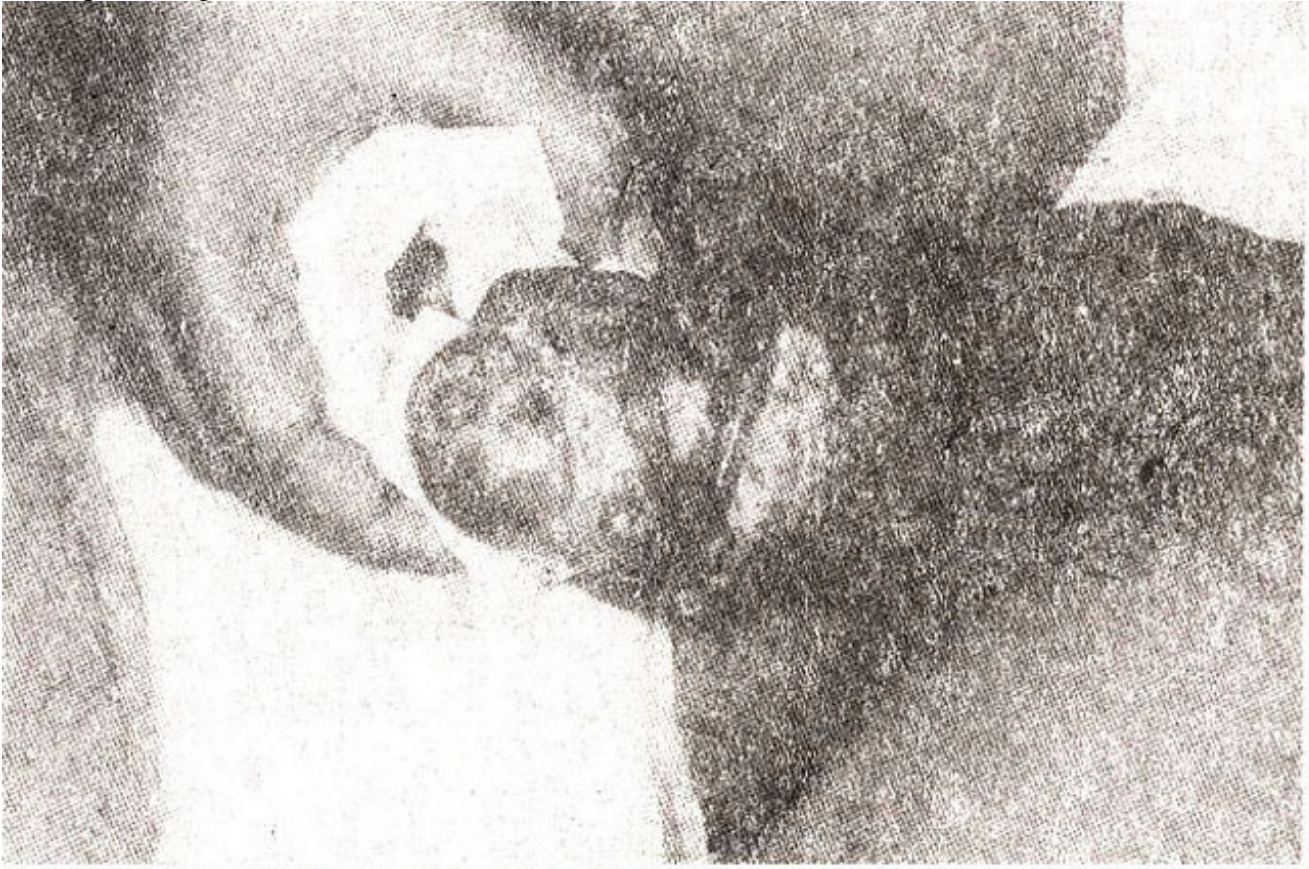

Figure 2. Pre-operative photograph showing the ulcerative lesions on the dorso-lateral aspects of penis. Both lesions were biopsy proven squamous cell carcinoma of penis.

was done to determine depth of tumor invasion and showed no cavernosal involvement. As the disease was confined to the distal shaft, partial penectomy with preservation of 8 cm of un-involved proximal penile shaft and bilateral sentinel lymph node biopsy was performed. The resected surgical margin and both sided Sentinel lymph nodes were tumor free, the final pathologic stage was thus pT2NOMO. At one year follow up, he remained free of tumor with no voiding difficulty.

Case 2

A 78-year old healthy male, farmer from northern areas of Pakistan, presented with a 4 month history of swelling and pain in penile shaft and 2 month history of two ulcers on the ventral penile shaft (Figure 2).

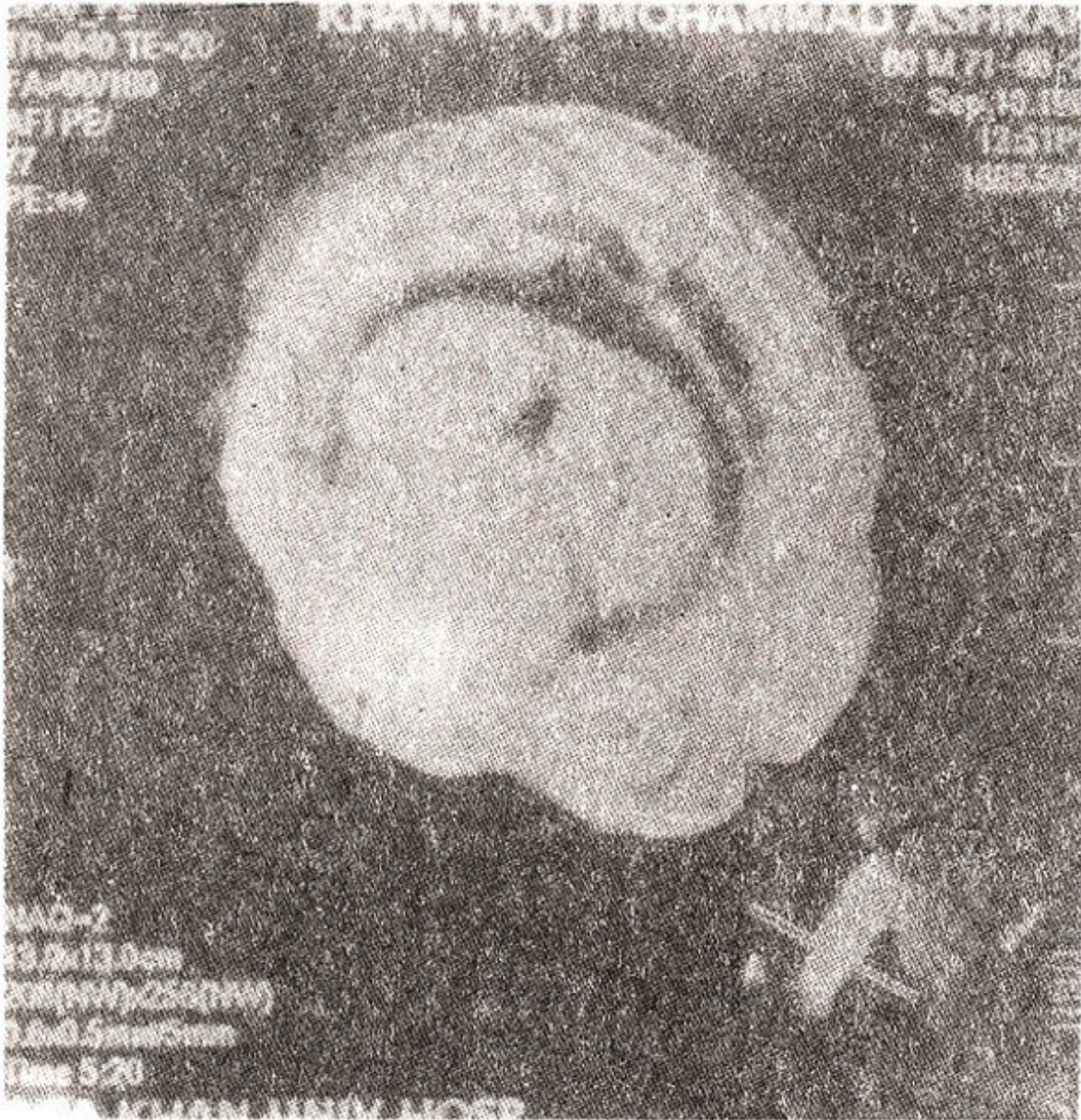

Figure 1 MRI scan with T1 / T2 weighted images, showing extent and depth of tumor invasion.

He was circumcised in late childhood and he had no lower urinary tract symptoms. He was initially evaluated and treated for an infective penile ulcer outside Karachi. Apparently, he underwent some minor surgical procedure and remained well for about a month following which the ulcer progressed to a large ulcerative lesion.

Examination revealed a swollen and hard penis especially the glans penis. There were 2 hard, indurated ulcerative lesions: one measuring 4 x 3 cms about 4 cm from the penoscrotal junction on the ventral surface and, the other measuring 2 x 1 cms about 3 cm from the glans penis. Both ulcers had everted margins and were covered with superficial slough. He had bilaterally enlarged inguinal lymph nodes, which were discrete, hard and mobile. He initially underwent suprapubic cystostomy and biopsy of the penile lesion that revealed keratinizing well differentiated infiltrating SCC. Metastatic workup with chest x-ray, ultrasound abdomen and liver function tests, revealed distant disease and hence the tumour was clinically staged as T3 N2 M0 (Stage III according to AJCC) and was treated by total penectomy

and perineal urethrostomy. Resected margins of corpus spongiosum with right and left crura were tumour free. He was given a six-week course of broad-spectrum antibiotics, following which minimal clinical regression of inguinal lymph nodes was noted. An MRI of pelvis and perineum (Figure 3)

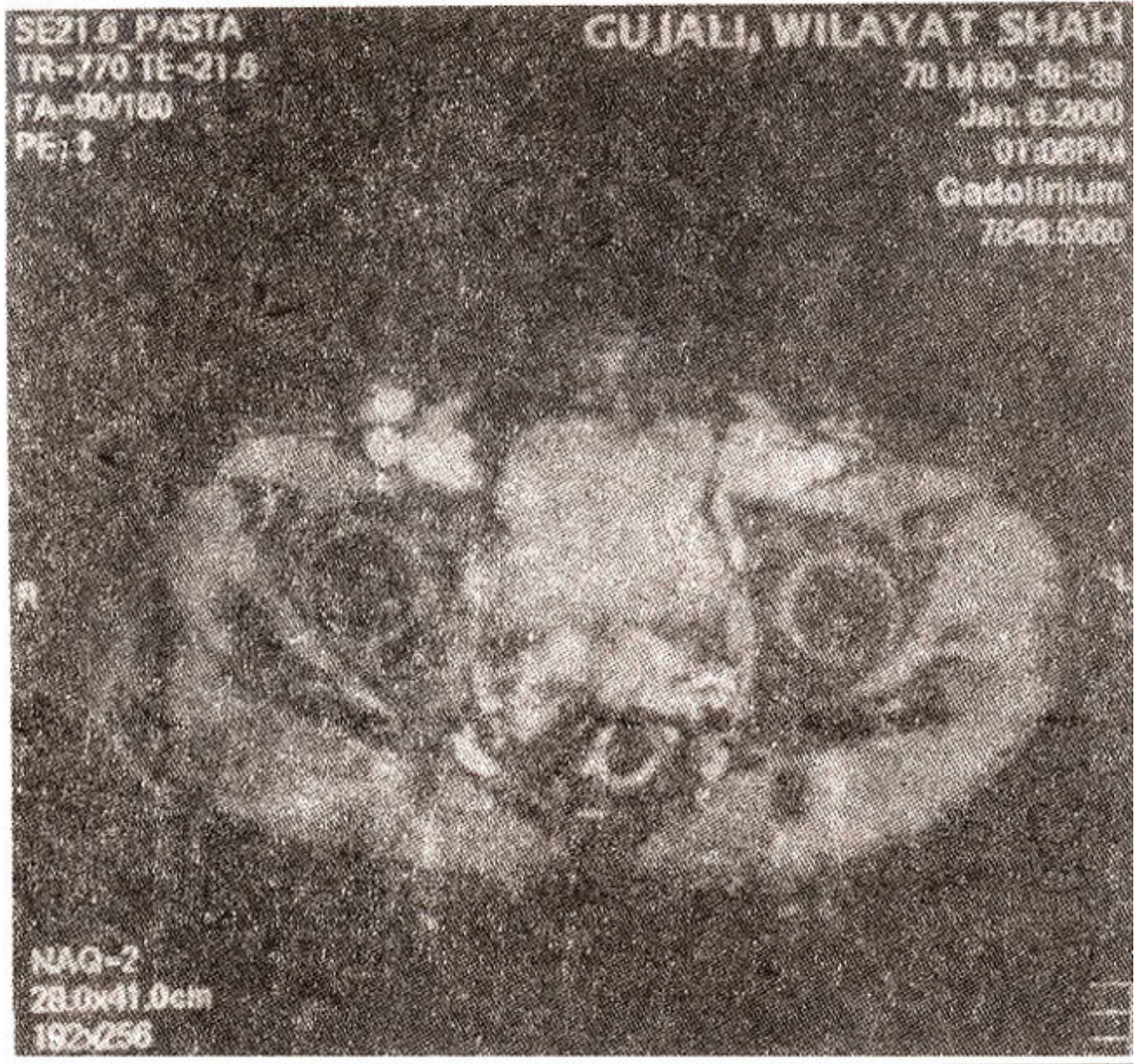


Figure 3 MRI scan with T1 / T2 weighted images showing multiple, moderately large, matted Inguinal and Iliac lymph nodes

revealed bilateral, multiple, large (>2 cm) matted inguinal and iliac group of lymph nodes suggestive of loco-regional nodal involvement. Two months after the initial surgery, the patient underwent bilateral inguinal lymph node biopsy of well defined enlarged lymph nodes, which on frozen section, only revealed reactive changes with no evidence of metastasis. At 3-months, he remains free of tumor recurrence and would be regularly followed.

Discussion

The most common histological type of PC is squamous cell carcinoma with the rare occurrence of basal cell carcinoma, melanoma and Kaposi's sarcoma. Common sites of involvement in descending order

are glans, prepuce and shaft. It is important that the advanced and proximal lesion need to be differentiated from extensive, ulcerative urethral cancer. Recently it has been suggested that both Bowen's disease and Erythroplasia of Queyrat should be considered as penile carcinoma in situ rather than as premalignant conditions¹⁰.

The tumour begins as an area of induration, erythema, warty growth, nodule, or as superficial ulceration. The most important prognostic factor in patients with penile cancer is the status of regional lymph nodes, which in turn are related to the depth of tumor invasion and histologic grade^{9,11-13}. Metastasis to distant sites such as liver, lung, and brain is seen only in 5% of patients at the time of diagnosis¹⁴. Assessment of the depth of invasion of the primary lesion by means of deep tissues biopsy is necessary in all cases to plan an appropriate management. Magnetic resonance imaging is now the investigation of choice for assessment of local extent of the tumor^{15,16}.

In the absence of distant metastasis, surgical management of penile cancer is dependent on the depth, extent of the primary lesion and the status of the regional lymph nodes (Table).

Table. Evaluation of Penile Cancer.

History	Physical Examination	Investigation
Symptoms	Local (Ulcer)	Laboratory
Ulceration	Location	Anaemia
Pain	Size	Leucocytosis
Discharge	Fixation	
		Histopathology Imaging
Irritating Voiding Symptoms	Involvement of Corporal bodies	Urethrography
Bleeding	Rectal and bimanual exam.	
Predisposing Factors	Palpation of inguinal areas	Cavernosography
Uncircumcised males	Ultrasonography	
Phimosis	Systemic	CT-Scan
HPV		MRI
Smoking		

The goal of local treatment is complete removal of the primary lesion with 1.5 cms or more of healthy resected margins¹⁷. While partial or total penectomy remains the gold standard, various other approaches have been used especially in small lesions when organ conservation is an important consideration¹⁸. The experience with conservative surgery is however, limited and carries the risk of local and regional recurrence²⁴. Partial penectomy serves well for distal T1 and T2 lesions with 80% 5 years survival rate in the absence of inguinal lymph node metastases, Similarly, for more proximally penile shaft and T3 lesions, total penectomy and perineal urethrostomy provides excellent cancer control with 90% 5-year survival rates in the absence of distant metastasis. The alternative approaches include Moh's micrographic surgery which is only indicated for small distally located lesions upto 1

cm in diameter laser therapy (CO₂ or Nd: YAG) for T1 and T2 lesions with 89% 5 year survival rate, and radiation therapy for T1 and T2 lesions . In tumors 4 cm or less in size with no or minor corporeal invasion, interstitial radiation therapy has been shown to provide satisfactory local control with good functional results^{20,21} . Rarely, major exenterative surgery such as hemipelvectomy and hemicorporectomy could be used for T4 lesions with fixed nodes¹⁸ .

The treatment of PC is dependent on the degree of local invasion and the status of regional lymph nodes. While the treatment of primary penile cancer is well standardized, the major issue in its management is the decision for lymph node dissection²² . The problem arises due to inaccuracy of clinical or radiological staging and marked morbidity associated with inguinal lymphadenectomy^{11,23,24} . Since PC is mostly a locoregional disease, inguinal/pelvic lymphadenectomy in the absence of distant metastasis, has been shown to improve the cancer control rates. However, only 50% of patients with palpable inguinal lymph nodes would have metastasis. Conversely, about 20% of patients with negative inguinal nodes would have occult metastasis²⁰ . Thus, in patients with clinically negative nodes, it remains controversial whether to perform immediate prophylactic lymphadenectomy, selective sentinel or Catalona lymph node biopsy or adopt a surveillance approach with delayed lymphadenectomy when adenopathy is detected. Surveillance is definitely not indicated if the patient cannot be reliably followed. The sentinel lymph node biopsy has a significant false negative rate of about 25%²⁵ whilst doubts have also been raised about Catalona procedure²⁶ .

Since about 50% of those with clinically positive nodes show no neoplastic involvement, patients presenting with enlarged inguinal nodes should undergo treatment of the primary lesion followed by a 4 to 6 week course of oral broad-spectrum antibiotics. Those with complete resolution of lymphadenopathy may be observed, while the others who persist to have palpable node need locoregional lymphadenectomy when there is absence of distant metastasis.

The information on chemotherapy for regionally advanced or metastatic penile cancer is limited. Preliminary data indicates some response to combination therapy with cisplatin, bleomycin, methotrexate and 5 Fluorouracil²⁷⁻³⁰ .

Radiation therapy is ideal for patients with T1 and T2 primary cancers of the penis. Pre-operative RT is useful for patients with mobile lymph nodes > or = 4 cm in size in the groin. RT provides effective palliation in patients with advanced regional disease and/or distant metastases^{31,32} .

References

1. Sehoen El. The status of circumcision of newborns, N. Eng J. Med., 1990;322:1 308-12.
2. Maden C: Sherman KJ, Beck Mann Am, et al. History of circumcision, medical conditions and sexual activities and risk of penile cancer. J. Natl. Cancer. Inst., 1993;85:19-24.
3. Yeok BB, Jussawalla DJ. Descriptive epidemiology of the cancers of male genital organs in greater Bombay Indian J. Cancer, 1997,34;30-39,
4. Gajalakshmi CK, Shanta V. Association between cervical and penile cancer in Madras India, Acta. Oncol., 1993;32:61 7-20.
5. Ross BS, Levine VJ, Dixon C, et al. Squamous cell carcinoma of the penis in Carcinoma of the penis in a circumcised man; a case for dermatology and urology and review of the literature. Cutis., 1998;61:41-43.
6. Mangoha GA, Kaale RF, Epidemiological and clinical aspects of carcinoma of penis at Kenyatta national hospital. East African Med. J., 1995;72:359-61.
7. Kadar AH, Aslam M, Paracha A, et al Squamous cell carcinoma of the penis in a circumcised population Br. J. Urol.. 1999;83:23-24.
8. Sarkar FH, Miles Mi, Plieth DH, et al. Detection of Human Papilloma virus in Squamous neoplasm of the penis. J. Urol., 1992;147:389-92.

9. Tan LB, Chiang CP, Huang CH. Clinical analysis of penile cancers among Chinese in Taiwan. *J. Formos. Med. Assoc.*, 1990;89:66-69.
10. Gerber GS. Carcinoma in situ of the penis. *J. Urol.*, 1994;151:829-33.
11. Ravi R. Prophylactic lymphadenectomy as observation vs inguinal biopsy in node-negative patients with invasive carcinoma of the penis. *Int. J. Clin. Oncol.*, 1993;23:53-58.
12. Yamada Y, Gohji K, Hara I, et al. Long-term follow-up study of penile cancer. *Int. J. Urol.*, 1998;5:247-51.
13. Chiu TV, Huang IS, Lai MK, et al. Penile cancer in Taiwan--20 years experience at National Taiwan University Hospital. *J. Formos. Med. Assoc.*, 1998;97:673-78.
14. Vapnek JM, Hricak H, Carroll PR. Recent advances in imaging studies for staging of penile and urethral carcinoma. *Urol. Clin. North Am.*, 1992;19:257-65.
15. de Kerviler E, Ollier P, Desgrandchamps F, et al. Magnetic resonance imaging in patients with penile carcinoma. *Br. J. Radiol.*, 1995;68:704-11.
16. Kawada I, Hashimoto K, Tokunaga I, et al. Two cases of penile cancer: magnetic resonance imaging in the evaluation of tumor extension. *J. Urol.*, 1994;152:963-65.
17. Hoffman MA, Renshaw AA, Loughlin KR. Squamous cell carcinoma of the penis and microscopic pathologic margins: how much margin is needed for local cure? *Cancer*, 1999;85:1565-68.
18. Magoha GA. Management of carcinoma of the penis: a review. *East Afr. Med. J.*, 1995;72:547-50.
19. Brkovic O, Kalble T, Dorsam J, et al. Surgical treatment of invasive penile cancer - the Heidelberg experience from 1968 to 1994. *Fur Urol.*, 1997;31:339-42.
20. Thcodorescu D, Russo P, Zhang ZF, et al. Outcomes of initial surveillance of invasive squamous cell carcinoma of the penis and negative nodes. *J. Urol.*, 1996;155:1626-31.
21. Akimoto I, Mitsuhashi N, Takahashi I, et al. Brachytherapy for penile cancer using silicon mold. *Oncology*, 1997;54:23-27.
22. Lopes A, Hidalgo GS, Kowalski IP, et al. Prognostic Factor in Carcinoma of the penis: Multivariate analysis of 145 patients treated with amputation and lymphadenectomy. *J. Urol.*, 1996;156:1637-42.
23. Martin Martinez JC, Herranz Arno F, Jara Rascon, et al. [Complication of inguinal lymphadenectomy for penile carcinoma. Origin, management and prevention] *Actas. Urol. Esp.*, 1995;19:759-71.
24. Ravi R. Morbidity following groin dissection for penile carcinoma. *Br. J. Urol.*, 1993;71:941-45.
25. Pettaway CA, Pisters LL, Dinney CP, et al. Sentinel lymph node dissection for penile carcinoma: the M. D. Anderson cancer experience. *J. Urol.*, 1995;154:1999-2003.
26. Lopes A, Rossi BM, Foneca FP, et al. Unreliability of modified inguinal lymphadenectomy for clinical staging of penile carcinoma. *Cancer*, 1996;77:2099-102.
27. Pizzocaro G, Piva L. Adjuvant and neoadjuvant vincristine, bleomycin, and methotrexate for inguinal metastases from squamous cell carcinoma of the penis. *Acta Oncol.*, 1988;27:823-24.
28. Hussein AM, Bendetto P, Sridhar KS. Chemotherapy with cisplatin and 5-fluorouracil for penile and urethral squamous cell carcinomas. *Cancer*, 1990;65:433-38.
29. Fisher HAG, Brada J, Horton J, et al. Neoadjuvant therapy with cisplatin and 5-fluorouracil for stage-III squamous cell carcinoma of the penis. *J. Urol.*, 1990;143:352.
30. Shamma FV, Ous S, Fossa SD. cisplatin and 5-fluorouracil in advanced cancer of the penis. *J. Urol.*, 1992;147:630-32.
31. Ravi R, Chaturvedi HK, Sastry DV. role of radiation therapy in the treatment of carcinoma of the penis. *Br. J. Urol.*, 1994;74:646-51.
32. Gerbaulet A, Lambin P. Radiation therapy of cancer of the penis. Indications, advantages, and pitfalls. *Urol. Clin. North Am.*, 1992;19:325-32.