



THE AGA KHAN UNIVERSITY

eCommons@AKU

---

Section of Paediatric Surgery

Department of Surgery

---

3-2013

## Focused abdominal sonography for trauma (FAST) in blunt paediatric abdominal trauma

Ahmad Vaqas Faruque  
*Aga Khan University*

Saqib Hamid Qazi  
*Aga Khan University, saqib.qazi@aku.edu*

Muhammad Arif Mateen Khan  
*Aga Khan University, arif.mateen@aku.edu*

Wassem Akhtar  
*Aga Khan University*

Amina Majeed  
*Aga Khan University*

Follow this and additional works at: [https://ecommons.aku.edu/pakistan\\_fhs\\_mc\\_surg\\_paediatr](https://ecommons.aku.edu/pakistan_fhs_mc_surg_paediatr)



Part of the [Pediatrics Commons](#), [Radiology Commons](#), and the [Surgery Commons](#)

---

### Recommended Citation

Faruque, A. V., Qazi, S. H., Khan, M. A., Akhtar, W., Majeed, A. (2013). Focused abdominal sonography for trauma (FAST) in blunt paediatric abdominal trauma. *Journal of the Pakistan Medical Association*, 63(3), 361-364.

Available at: [https://ecommons.aku.edu/pakistan\\_fhs\\_mc\\_surg\\_paediatr/28](https://ecommons.aku.edu/pakistan_fhs_mc_surg_paediatr/28)

## Focused abdominal sonography for trauma (FAST) in blunt paediatric abdominal trauma

Ahmad Vaqas Faruque,<sup>1</sup> Saqib Hamid Qazi,<sup>2</sup> Muhammad Arif Mateen Khan,<sup>3</sup> Wassem Akhtar,<sup>4</sup> AminaMajeed<sup>5</sup>

### Abstract

**Objective:** To evaluate the role of focussed abdominal sonography for trauma in blunt paediatric abdominal trauma patients, and to see if the role of computed tomography scan could be limited to only those cases in which sonography was positive.

**Methods:** The retrospective study covered 10 years, from January 1, 2000 to December 31, 2009, and was conducted at the Department of Radiology and Department of Emergency Medicine, Aga Khan University Hospital, Karachi. It comprised cases of 174 children from birth to 14 years who had presented with blunt abdominal trauma and had focussed abdominal sonography for trauma done at the hospital. The findings were correlated with computed tomography scan of the abdomen and clinical follow-up. Sensitivity, specificity, positive predictive value, negative predictive value and accuracy of focussed abdominal sonography for trauma were calculated for blunt abdominal trauma. SPSS 17 was used for statistical analysis.

**Results:** Of the total 174 cases, 31 (17.81%) were later confirmed by abdominal scan. Of these 31 children, sonography had been positive in 29 (93.54%) children. In 21 (67.74%) of the 31 children, sonography had been true positive; 8 (25%) (8/31) were false positive; and 2 (6%) (2/31) were false negative. There were 6 (19.3%) children in which sonography was positive and converted to laparotomy. There was no significant difference on account of gender ( $p>0.356$ ). Focussed abdominal sonography for trauma in the study had sensitivity of 91%, specificity of 95%, positive predictive value of 73%, and negative predictive value of 73% with accuracy of 94%. All patients who had negative sonography were discharged later, and had no complication on clinical follow-up.

**Conclusions:** Focussed abdominal sonography for trauma is a fairly reliable mode to assess blunt abdominal trauma in children. It is a useful tool to pick high-grade solid and hollow viscous injury. The results suggest that the role of computed tomography scan can be limited to those cases in which focussed sonography is positive.

**Keywords:** Solid visceral injury, Hollow viscous injury, FAST, Paediatric. (JPMA 63: 361; 2013)

### Introduction

An injury is the physical damage that results when a human body is suddenly or briefly subjected to intolerable levels of energy. Childhood injuries are currently a leading cause of death in the world<sup>1</sup> and a global problem worldwide.<sup>2</sup> There is no doubt that the first disease treated on earth was trauma and since then the management of trauma is changing. In the past, 17-25% of patients used to die of unrecognised peritoneal bleed. Initially, blunt abdominal trauma patients were evaluated by clinical examination, but the experience of first half of the last century showed that simple clinical examination of the abdomen was unreliable and misleading in up to 45% of patients, leading to a high incidence of missed fatal injuries as well as a higher number of non-therapeutic laparotomy. Later, there was a

role of diagnostic peritoneal lavage (DPL) followed by computed tomography (CT) scan but all those modalities had certain limitations. Focussed abdominal sonography for trauma (FAST) was a big help in such cases.

FAST is widely used in the whole of North America, Australia and in many trauma centres of Europe and China. Some of the North American centers have claimed that they have not done DPL since 1991 after the introduction of FAST in trauma management.<sup>3</sup> The importance of the FAST examination can be emphasised by the fact that FAST has been included as a part of Advanced Trauma Life Support (ATLS) course and in the surgery curriculum of American and German College of Surgeons.

FAST is a very quick and effective tool to evaluate blunt abdominal trauma in emergency situations. It should be considered the 5th modality in the assessment of trauma situation. The role of FAST in adult blunt abdominal trauma is very definite, but its role in paediatric surgery remains controversial<sup>4</sup> and till now, to the best of our knowledge, no study has been done from our part of

.....  
<sup>1-3</sup>Section of Paediatric Surgery, Department of Surgery, <sup>4</sup>Department of Radiology, <sup>5</sup>Aga Khan Medical College, The Aga Khan University Hospital, Karachi.

**Correspondence:** Muhammad Arif Mateen Khan. Email: arif.mateen@aku.edu

world. Therefore, the current study was planned to evaluate the role of FAST in blunt paediatric trauma patients.

### Patients and methods

The retrospective study, conducted at the Aga Khan Hospital, Karachi, covered a period of 10 years; from January 1, 2000 to December 31, 2009. All cases with haemodynamically stable children according to percentile for height and age from birth to 14 years, who presented with blunt abdominal trauma and had FAST done at the Emergency were included. Children who presented with isolated traumas or cases in which FAST was not performed were excluded. All those paediatric traumas that were discharged from the Emergency were also excluded.

Formal ethical approval was not required as it was a retrospective study and data was collected from the medical record, maintaining confidentiality according to the hospital guidelines.

Data was collected and entered by two different persons into SPSS version 17 for analysis. Age, gender, mechanism of injury, physiologic parameters, Injury Severity Scale (ISS) scoring, FAST results, type of injury, grading of injury, results of laparotomy and CT scan were reviewed. The ISS was calculated as in literature.<sup>5</sup> Relation between FAST outcome and different gender and different mechanism of injury were analysed statistically by applying chi-square test. FAST outcome in terms of the nature of injury was also calculated by applying the same test.

The ultrasound examinations had been performed with real time ultrasound system (Aloka SSD - 650, Tokyo, Japan) located within the Radiology Department and the resuscitation area. It was equipped with a 3.5 MHz to 7.0 MHz curvilinear transducer, a printer and a video recorder.

For FAST, the standard four areas were examined for the presence of free intraperitoneal fluid; Morrison's pouch, the splenorenal recess, the pelvis and the pericardial area.<sup>6</sup>

All children in which FAST was positive had confirmation by CT scan abdomen and clinical follow-up. There was no quantitative measurement of fluid seen on CT scan.

Table-2: Findings in negative FAST patients.

	Age	Gender	Mechanism of injury	FAST result	CT findings	Laparotomy
1.	6 month	Female	MVA	Negative	Grade 2 Splenic laceration	Not done
2.	6 years	Females	Fall	Negative	Grade 2 Splenic laceration	Not done

MVA: Motor vehicle accident.

A case was labelled true positive when FAST and CT abdomen were positive for free fluid; it was considered true negative when both were negative for free fluid; false positive when the FAST was positive, but CT abdomen was negative for free fluid; and false negative when the FAST was negative but CT abdomen was positive for free fluid.

### Results

During the study period there were a total of 1754 paediatric trauma cases reporting at the institute. Out of them, FAST was performed on 174 (9.92%). Majority of children, (n=123; 71%) were of school-going age; followed by pre-school age, 40 (23%); and infants, 11 (6%). There were 113 (65%) boys. There was no significant statistical difference between males and females having FAST positive ( $p < 0.613$ ). Motor vehicle accident (MVA) injuries followed by fall was the most common mechanism of injury i.e. 37% each. There was no significant difference in MVA injury and other mechanisms of injuries with positive ultrasound FAST ( $p < 0.186$ ) (Table-1).

Of the 174 patients who had undergone FAST, 31 (17.81%) were subjected to CT scan. It was limited to only those cases in which FAST had been positive for free intraperitoneal fluid or in which there was a suspicion of definite solid visceral injury. Of the 31 children, FAST had been positive for 29 (93.54%), while 2 (6%) had been false negative (Figure). There were significant children with positive ultrasound FAST having solid visceral injury ( $p < 0.001$ ). Of the 29 children, 21 (72%) had true positive FAST, and 19 (90%) of these 21 children had it confirmed on CT scan. There were 2 (9.5%) positive FAST in which CT scan abdomen was not possible because of the severity of

Table-1: FAST outcome with different gender, mechanism of injury & nature of injury.

	FAST +ve	P value	FAST -ve
Male	21 (72.41 %)	0.384	92 (63)
Female	08 (27.54%)		53 (37)
Motor Vehicle Injury	13 (44.82%)	0.186	84 (57)
Other mechanism of Injury	16 (55.17%)		53 (36)
Solid Visceral Injury	19 (65.51%)	<0.001	2 (1)
Other injury	10 (34.48%)		143 (99)

Other 8 motor vehicle accident patients are not any injuries.

FAST: Focussed abdominal sonography for trauma.

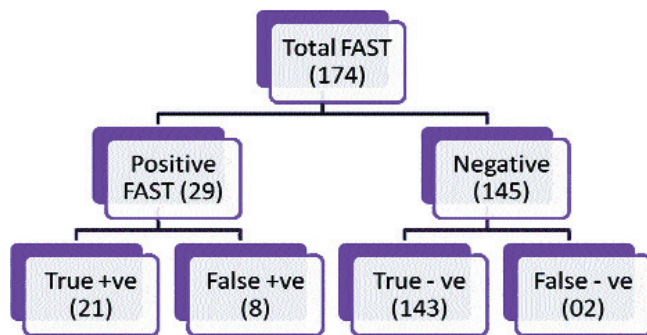


Figure: Positive and negative cases of FAST.

trauma. Both these children had hollow viscous injury, which was later proven in laparotomy. There were 2 cases of low-grade solid visceral injury picked-up by CT scan abdomen, but had not been detected by FAST. There were 2 (25%) children who had FAST positive, but because of haemodynamic instability, it was not possible to do CT scan abdomen and we had to shift them to the operation theater immediately.

There were 6 positive FAST which converted to laparotomy; one had grade 3 splenic laceration and other had grade 4 liver laceration; two children had hollow viscous injury i.e. Caecal and jejunal perforation and both of them had resection anastomosis and had no complications post-operatively. The rest of two had iatrogenic injuries. There were two deaths reported in our study, one due to severe haemorrhagic shock secondary to polytrauma with Grade 3 splenic laceration, and the other was due to septic shock due to delayed presentation.

There were two children with negative FAST, but were later found to have low-grade solid visceral injury on CT scan abdomen. Both of these children were managed conservatively and later discharged (Table-2).

FAST was positive for free fluid in 16% cases. FAST had sensitivity of 91%, specificity of 95%, positive predictive value (PPV) of 73%, negative predictive value (NPV) of 73% and accuracy of 94%.

**Discussion**

Abdominal ultrasound (US) has been used to evaluate trauma patients in Europe since the 1970s.<sup>7</sup> The German surgery board has required certification in US skills since 1988. Over the last 10 years in the United States, the use of US in trauma has gone from non-existent in most centers to now essentially replacing DPL in many centres. Most recently the FAST exam has been included as part of the ATLS course. In addition, The American College of Surgeons has included US as one of several "new

technologies" that surgical residents must be exposed to in their curriculum. It is evident that to rapidly evaluate blunt abdominal trauma, emergency physicians must become proficient in the use of trauma US.

A CT scan abdomen provides excellent solid organ detail, but it is expensive and often requires transport of the patient outside the department. DPL is more sensitive for detecting intra-peritoneal blood than US. Ultrasound is reliably sensitive to usually greater than 250ml in the Morrison's Pouch. DPL, however, is invasive and often limited by pregnancy or previous surgery. Ultrasound is inexpensive, rapid, and easily repeated.<sup>8,9</sup> There is an overwhelming amount of current data supporting the use of the FAST exam as the initial screening tool for evaluation of the abdomen in blunt trauma. Since all haemoperitoneum does not need surgical intervention, further more specific studies such as CT scan abdomen may be warranted in stable patients. There are a few studies recommending that in haemodynamically stable patients, negative FAST examination should be followed by clinical observation and FAST be reported<sup>10</sup> but there is minimum quantitative evidence to support the use of repeat FAST.<sup>7</sup> This area needs further exploration. One algorithm for a clinical pathway in the evaluation of blunt trauma has been adopted by a number of centres, including Jacksonville (Chicago, USA), for the use of ultrasound as the initial screening test.<sup>11,12</sup> If positive, the unstable patient goes to the operating room, a stable patient is evaluated by CT scan abdomen. If the US is negative in the stable patient, no further exams are indicated unless the patient has severe abdominal pain or there is a change in the clinical condition. In these patients, further evaluation is indicated with repeat ultrasound, CT scan abdomen or laparotomy.

The sole objective of FAST is the detection of free intraperitoneal fluid in blunt abdominal trauma. There is a specific criterion of labelling FAST positive. Presence of free fluid in any of the four areas was considered FAST positive. Each cm of fluid present in any of 4 areas given a score of one, and an additional score of one was given if free fluid was found at more than one site. A score of > 3 is a strong indicator of laparotomy.<sup>13</sup> There is an overwhelming amount of current data supporting the use of the FAST exam as the initial screening tool for the evaluation of blunt abdominal trauma in adult practice.<sup>8</sup> However, its role in paediatric practice is controversial. Use of FAST in paediatric trauma has been explored by a number of authors. Combining physical examination with FAST significantly improved the sensitivity of the evaluation. A prospective non-randomised study showed that FAST is rapid, less expensive and had a similar

accuracy as the CT scan.<sup>14</sup> Although it is increasingly being used in several paediatric trauma centres around the world, but still its definitive role in paediatric trauma is not fully established. The biggest criticism about the use of FAST in children has been the limited sensitivity i.e. 45% to 70% in different studies.<sup>8</sup> Nearly 40% of abdominal injuries in children are not associated with free fluid because of low grade solid visceral injuries in children who are restrained in motor vehicles.<sup>11</sup> It is technically difficult to perform FAST in an injured child who is crying and irritable. Also, gaseous distension of bowel in an injured child makes FAST not a useful modality for diagnosis. In 22% cases intraperitoneal fluid between bowel is normal.<sup>12</sup>

Ultrasound could be used in trauma situations as a screening tool and reduces the use of CT scan abdomen to those with doubtful or persistent abdominal findings.<sup>15</sup> It is very important to recognise that in most cases where FAST was positive, later had confirmation by CT scan abdomen. There were only 2 children with FAST results being false negative, and both of them had low-grade solid visceral injuries.

Like all studies there are certain strengths and limitations in our study. One of the strengths is that the objective matches with the conclusion. We stratified children in different categories in terms of any statistic relevance of any difference between male and female gender, this aspect of FAST has never been seen in any previous study. The retrospective nature of the study was its limitation. Besides, it was not a population-based study and was single-centre in nature. We suggest a larger multi-centre longitudinal study to produce results that may be generalised across the board.

## Conclusion

FAST is a fairly reliable mode to assess blunt abdominal trauma in children. Results indicate the role of CT scan abdomen can be limited to only those cases in which FAST is positive. It is a useful tool to detect high-grade solid and hollow viscous injury.

## Acknowledgement

We are grateful to the Department of Radiology for their support and assistance.

## References

1. Rehmani R. Childhood injury prevention (editorial). *J Pak Med Assoc* 2008; 58: 293-4.
2. Sim TP, Ng KC. Childhood injuries: prevention is always better than cure. *Singapore Med J* 2005; 46: 103-5.
3. Rozycki GS, Shackford SR: Ultrasound, what every trauma surgeon should know. *J Trauma* 1996; 40: 1-4.
4. Kortbeek JB, Al Turki SA, Ali J, Antoine JA, Bouillon B, Brasel K et al. Advanced trauma life support, 8th edition, the evidence for change. American College of Surgeons Committee on Trauma. *J Trauma* 2008; 64(6):1638-50.
5. Baker SP, O'Neill B, Haddon W Jr, Long WB. The injury severity score: a method for describing patients with multiple injuries and evaluating emergency care. *J Trauma* 1974; 14: 187.
6. Rozycki G, Ochsner MG, Jaffin J, Champion HR. Prospective evaluation of surgeon's use of ultrasound in the evaluation of trauma patients. *J Trauma* 1993; 34: 516-27.
7. Blackburne LH, Soffer D, McKenney MG, Amortegui J, Schulmon U, Crookes B, et al. Secondary ultrasound examination increases the sensitivity of the FAST exam in blunt trauma. *J Trauma* 2004; 57: 934-8.
8. Rozycki GS, Ballard RB, Feliciano DV, Schmidt JA, Pennington SD. Surgeon-performed ultrasound for the assessment of truncal injuries: lessons learned from 1540 patients. *Ann Surg* 1998; 228: 557-67.
9. Yoshii H, Sato M, Yamamoto S, Motegi M, Okusawa S, Kitano M, et al. Usefulness and limitations of ultrasonography in the initial evaluation of blunt abdominal trauma. *J Trauma* 1998; 45: 45-51.
10. Rozycki G, Ochsner MG, Schmidt JA, Frankel HL, Davis TP, Wang D, et al. A prospective study of surgeon-performed ultrasound as the primary adjuvant modality for injured patient assessment. *J Trauma* 1995; 39: 492-500.
11. Branney SW, Moore EE, Cunniff SV, Burch JM, Terry SJ. Ultrasound based key clinical pathway reduces the use of hospital resources for the evaluation of blunt abdominal trauma. *J Trauma* 1997; 42: 1086-90.
12. Ballard RB, Rozycki GS, Newman PG, Cubillos JE, Salomone JP, Ingram WL, et al. An algorithm to reduce the incidence of false-negative FAST examinations in patients at high risk for occult injury. *J Am Coll Surg* 1999; 189: 145-51.
13. Asher WM, Parvin S, Virgilio RW, Haber K. Echographic evaluation of splenic injury after blunt trauma. *Radiology* 1976; 118: 411.
14. Boulanger BR, McLellan BA, Brenneman FD, Ochoa J, Kirkpatrick AW, et al. Prospective evidence of the superiority of a sonography-based algorithm in the assessment of blunt abdominal injury. *J Trauma* 1999; 47: 632-7.
15. Huang MS, Liu M, Wu JK, Shih HC, Ko TJ, Lee CH. Ultrasonography for the evaluation of hemoperitoneum during resuscitation: a simple scoring system. *J Trauma* 1994; 36:173-177.